



OneShot 4.0  
**Anatomy**



# ANATOMY

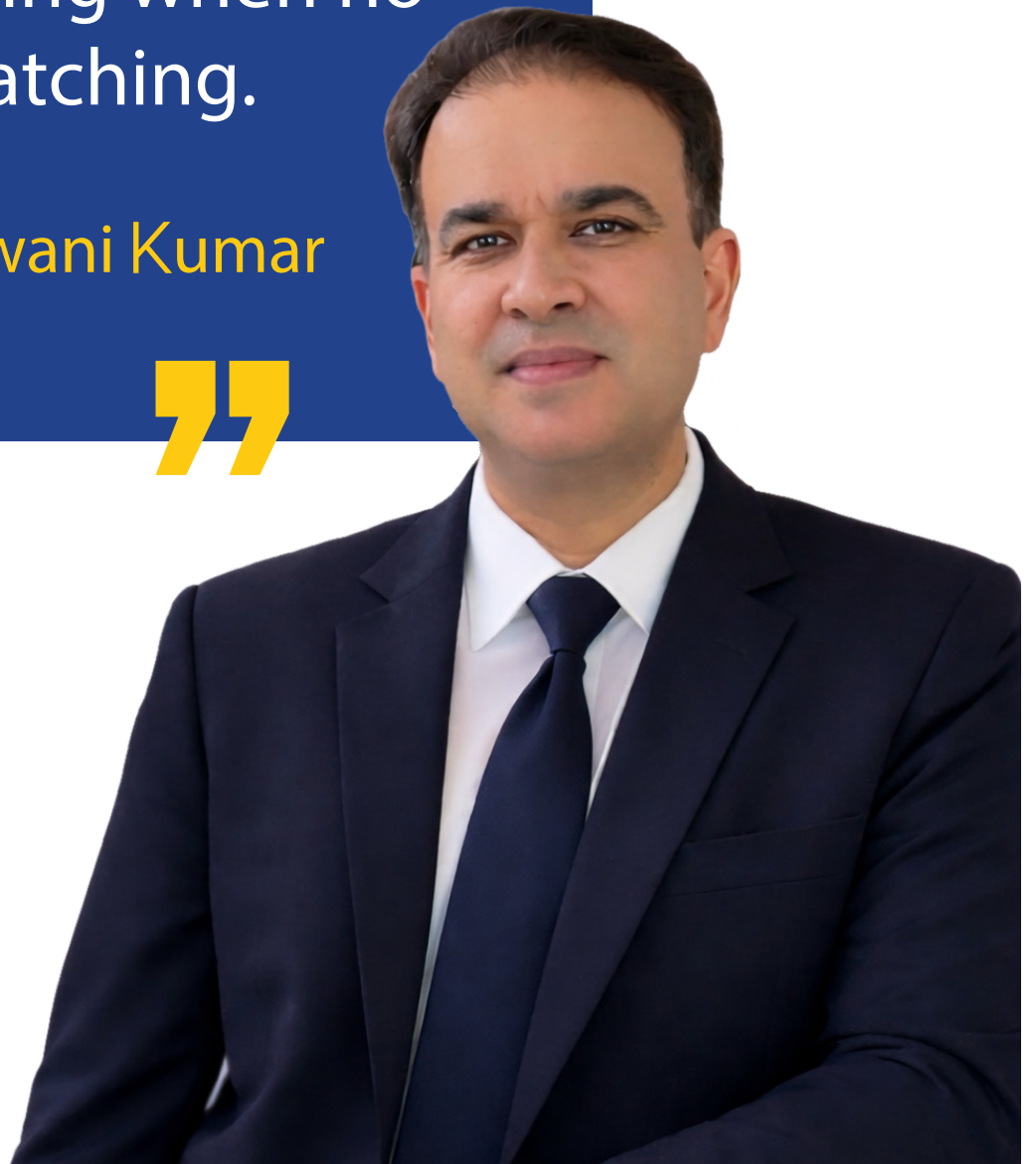Sl. No.	CHAPTER	Page No.
1.	<i>Embryology</i>	3
2.	<i>Upper Limb</i>	17
3.	<i>Lower Limb</i>	31
4.	<i>Head, Neck &amp; Face</i>	51
5.	<i>Neuroanatomy</i>	65
6.	<i>Abdomen &amp; Perineum</i>	77

“

The most powerful transformations happen not in the moments of victory, but in the quiet, unseen decisions to keep going when no one's watching.

- Dr. Ashwani Kumar

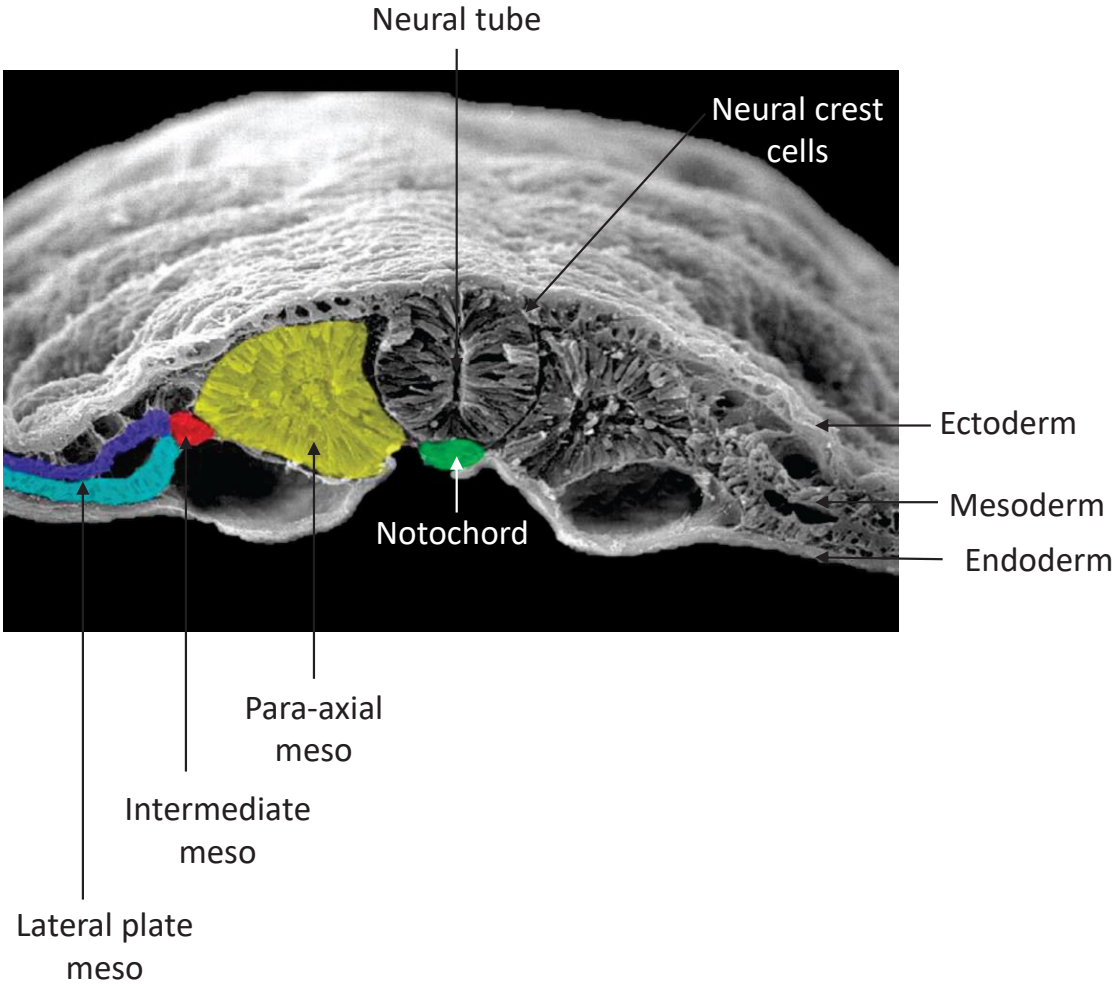
”





# EMBRYOLOGY

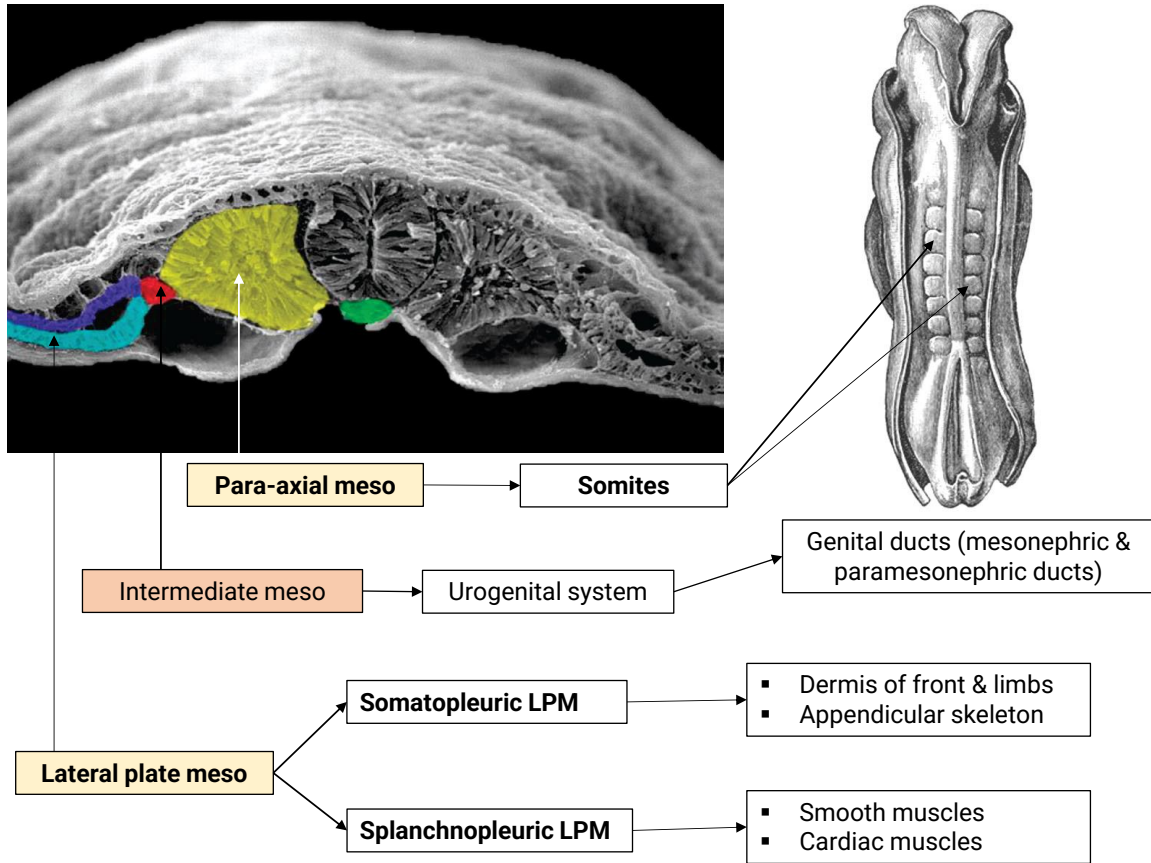
## GENERAL EMBRYOLOGY





**Somites derivatives**

- ✓ Dermis of back
- ✓ Axial skeleton
- ✓ Skeletal muscles (except pharyngeal arches)





**Neural tube**

*Key word- CNS*

- Brain & spinal cord
- Oligodendrocytes
- Astrocytes
- Ependymal cells
- Retina & pigment

**Neural crest cells**

*Key word- PNS*

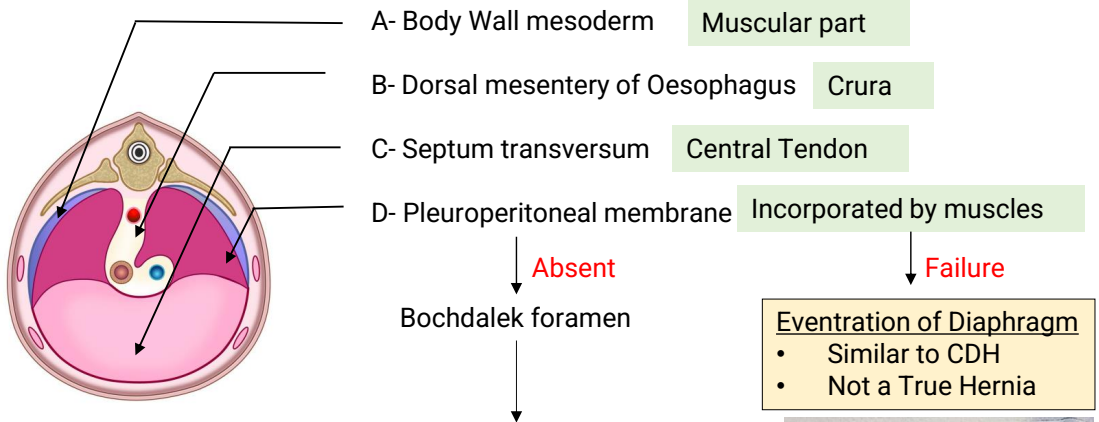
- All ganglion
- Enteric plexus
- Schwann cells
- Adrenal medulla
- Parafollicular C cells
- Melanoblast/cyte
- Skull bones (most)
- Dentine
- Pharyngeal arch cartilage
- Dermis of H&N
- Conotruncal septum

**Notochord**

Remnants

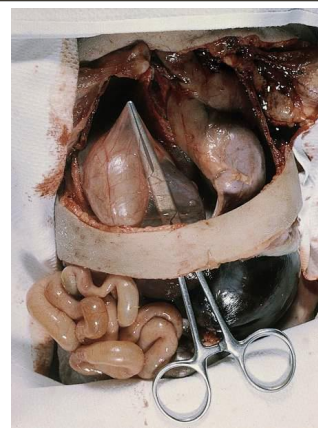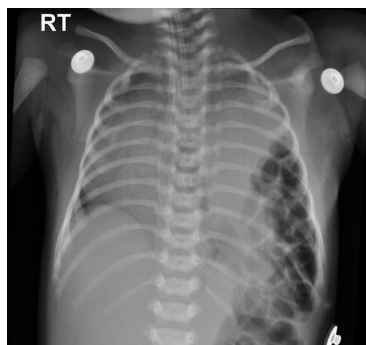
- Nucleus pulposus
- Apical ligament of dens
- Tectorial membrane

**DIAPHRAGM DEVELOPMENT**



**Congenital Diaphragmatic Hernia**

- Common on left side
- Complication → left lung Hypoplasia

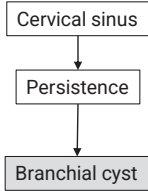
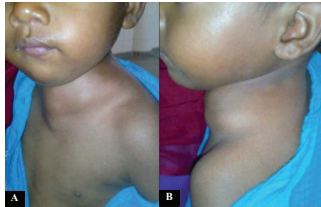



### PHARYNGEAL ARCHES

#### CLEFTS

1<sup>ST</sup> CLEFT : External auditory canal & outer layer of tympanic membrane



#### POUCHES

1<sup>ST</sup> pouch – Inner layer of TM, tympanic cavity, auditory tube & mastoid antrum

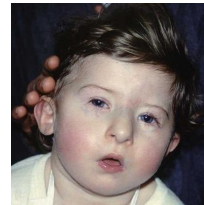2<sup>ND</sup> pouch- Palatine tonsil

3<sup>RD</sup> pouch- Thymus & inferior parathyroid gland

4<sup>TH</sup> pouch- Superior parathyroid gland

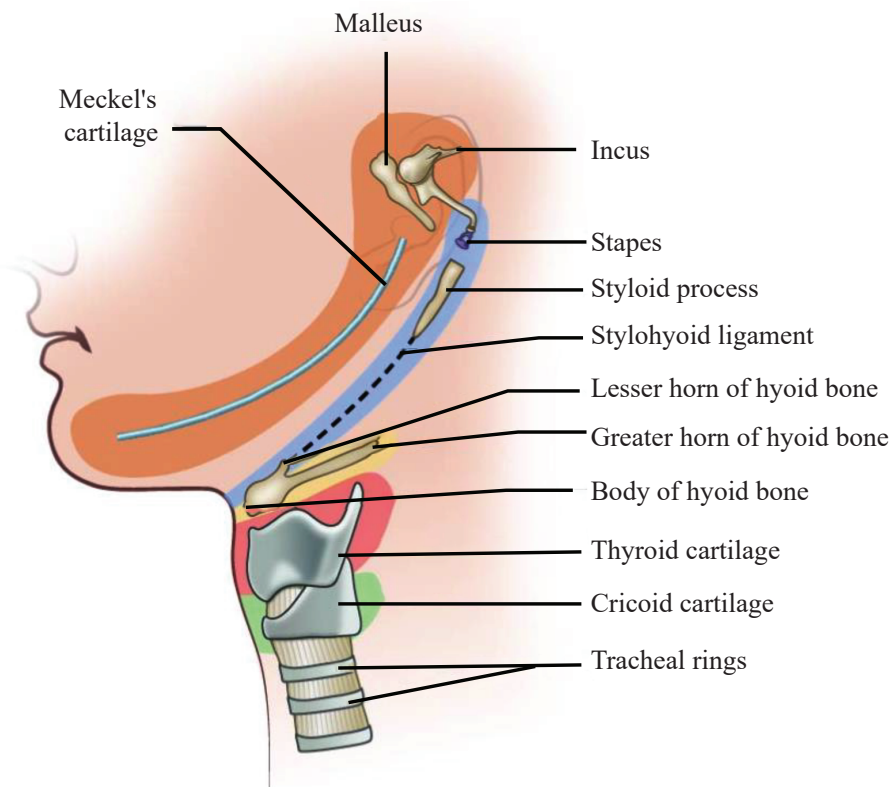
DiGeorge syndrome (22q11 deletion syndrome)

Absent thymus & hypoparathyroidism

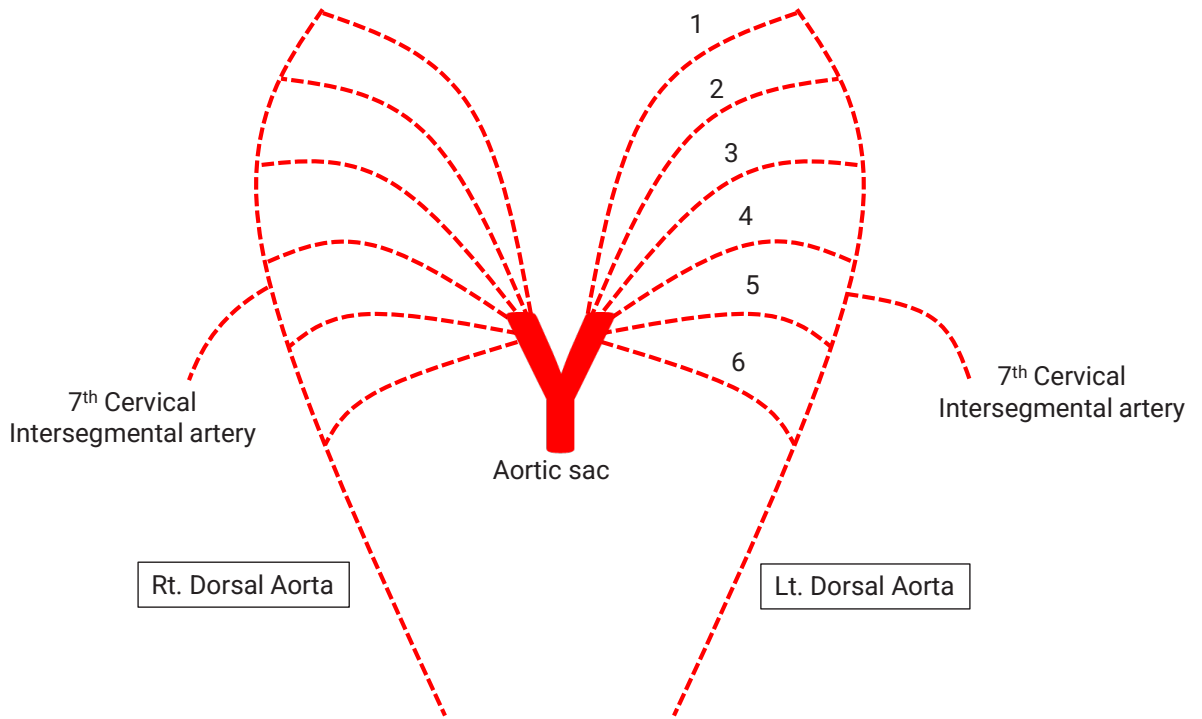


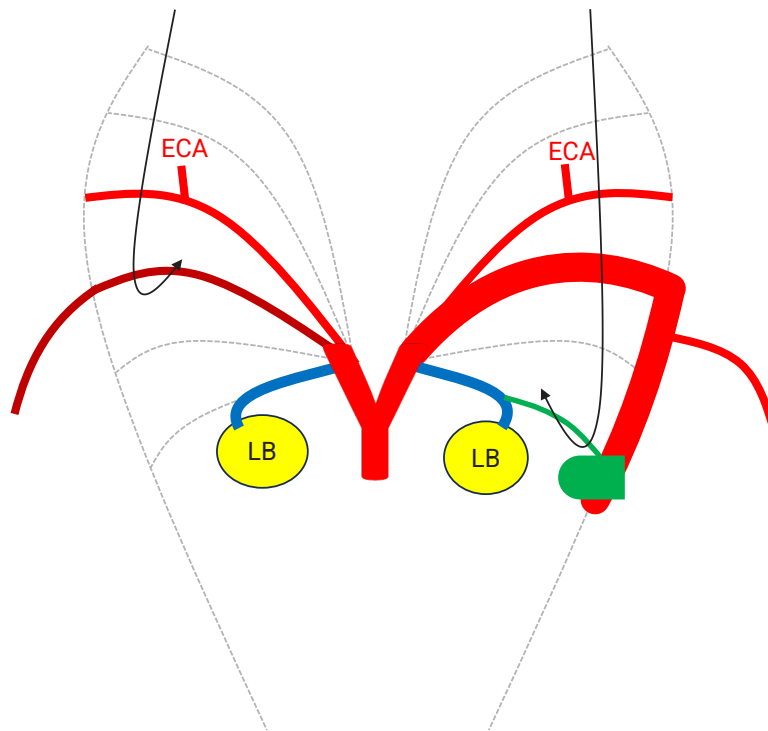
Remnant of 5<sup>TH</sup> pouch- Ultimobranchial body

### PHARYNGEAL ARCH CARTILAGES



**PHARYNGEAL ARCH ARTERIES**





Left RLN *hooks under the left sixth arch artery which persists in extra-uterine life* as the ductus arteriosus, a fibrous remnant. On the right side, neither the sixth nor fifth arch arteries persist.

Arch of Aorta

- Aortic Sac
- Left horn of AS
- Left 4<sup>th</sup> Arch artery

Brachiocephalic trunk

Right horn of AS

CCA

Proximal part of 3<sup>rd</sup> arch artery

ICA

Distal part of 3<sup>rd</sup> arch artery

Left Subclavian artery

Left 7<sup>th</sup> cervical intersegmental artery

Right subclavian artery

Right 4<sup>th</sup> arch artery  
Right 7<sup>th</sup> cervical intersegmental artery

Pulmonary artery

Proximal part of 6<sup>th</sup> arch artery

Ductus arteriosus

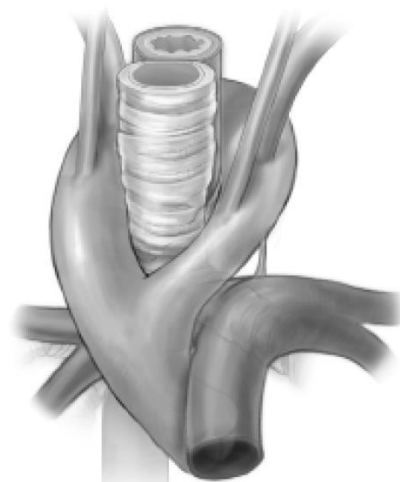
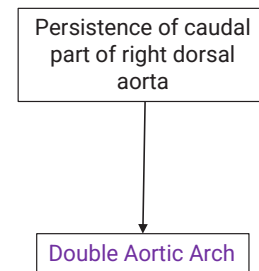
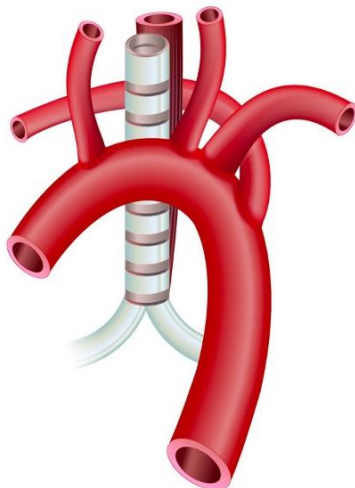
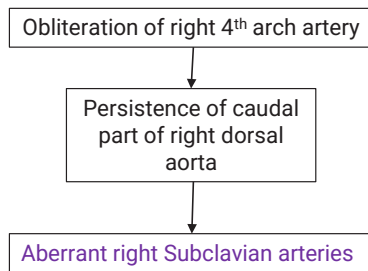
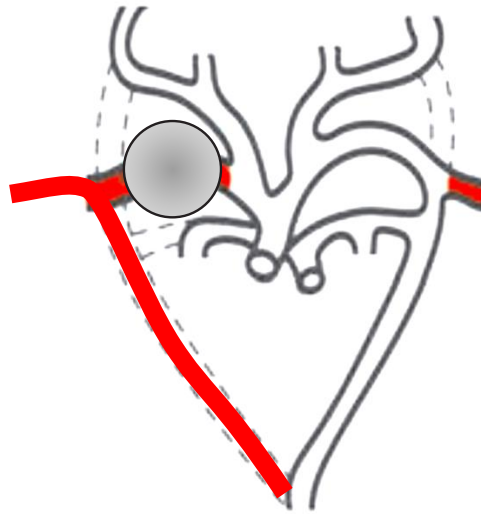
Distal part of left 6<sup>th</sup> arch artery



## PHARYNGEAL ARCH ARTERIES- SUMMARY

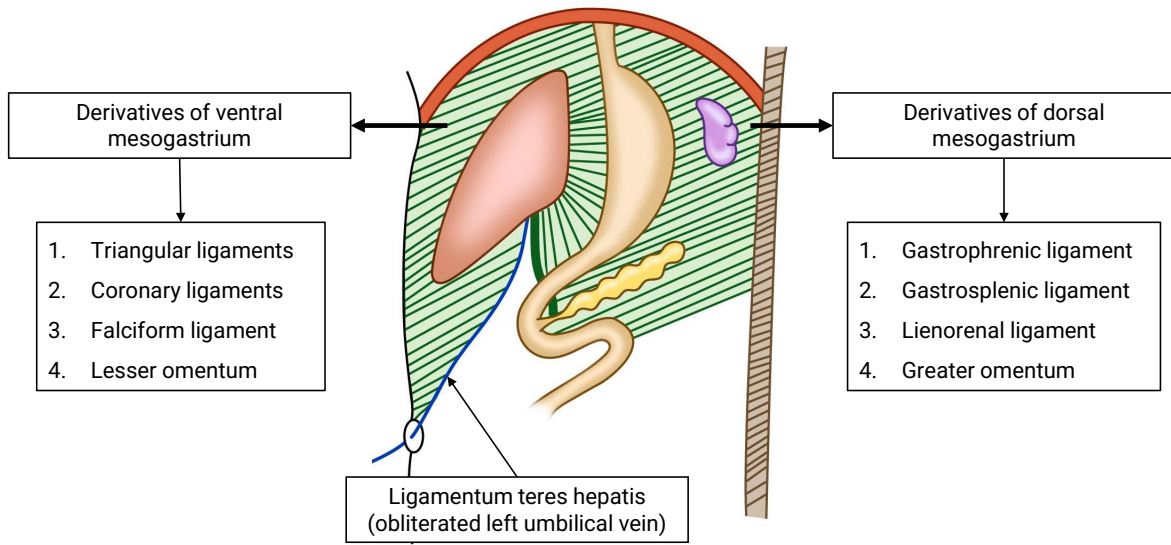
Aortic Arch	Derivatives
1 <sup>st</sup> arch	Maxillary artery (transient)
2 <sup>nd</sup> arch	Hyoid and stapedial artery (transient)
3 <sup>rd</sup> arch	Common carotid artery and proximal internal carotid artery
4 <sup>th</sup> arch	Left - Arch of aorta Right - Part of R subclavian artery
5 <sup>th</sup> arch	Degenerated
6 <sup>th</sup> arch	Left - proximal left pulmonary artery, distal ductus arteriosus Right - right pulmonary artery

## ANOMALIES :



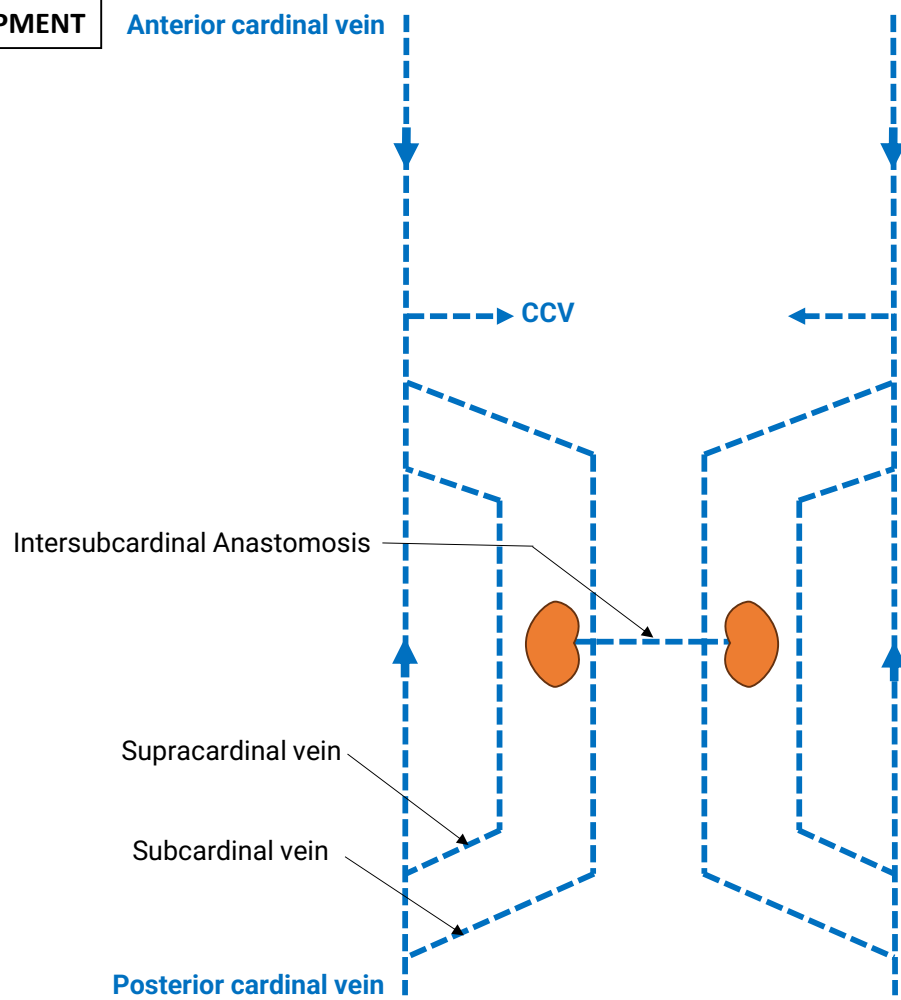


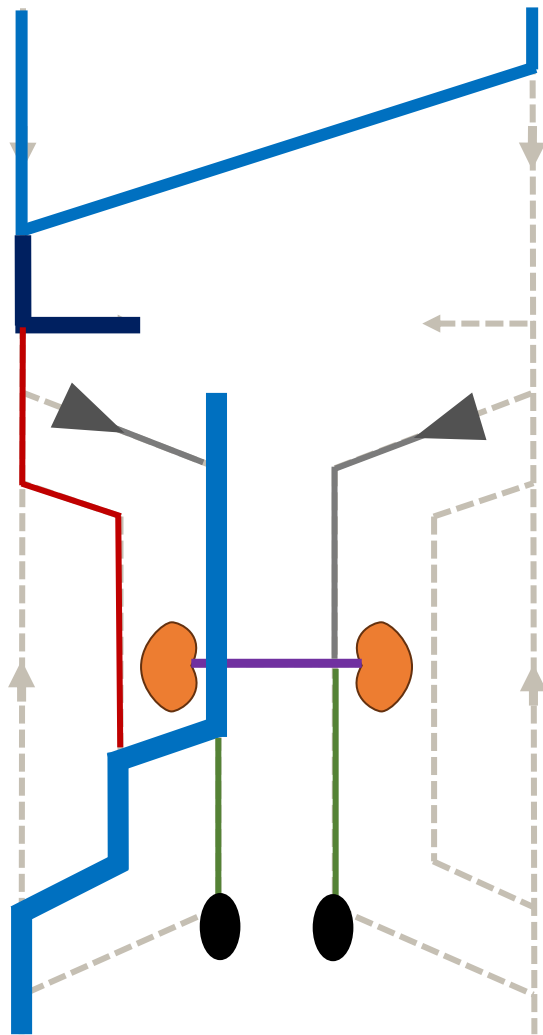
**MESOGASTRIUM & THEIR DERIVATIVES**





**VENOUS DEVELOPMENT**





**Rt. Brachiocephalic vein**  
Rt. ACV  
**Lt. Brachiocephalic vein**  
Lt. ACV + Oblique Anastomosis

**Superior Vena cava**  
Rt. ACV + Rt. CCV

**Inferior Vena Cava**  
Rt. PCV + Rt. Supracardinal vein + Rt. Subcardinal vein

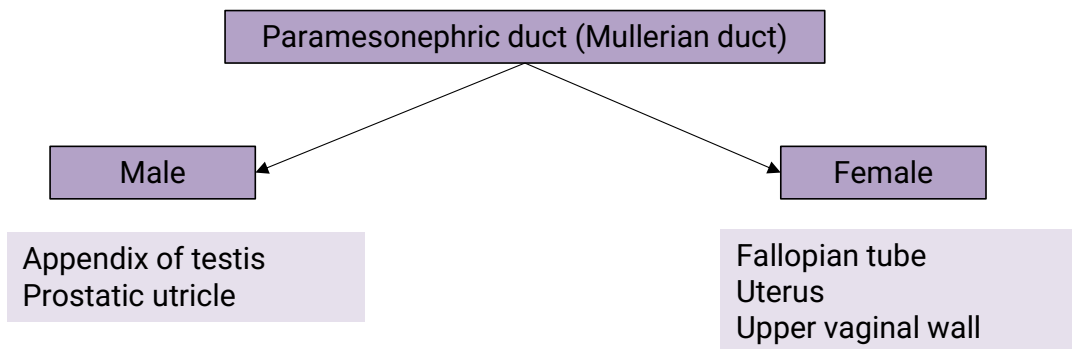
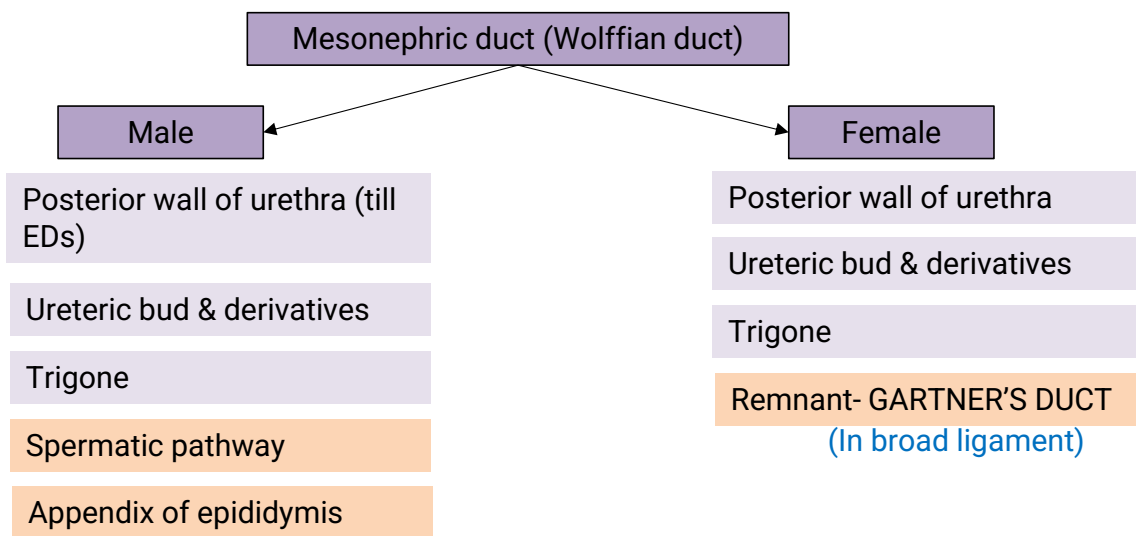
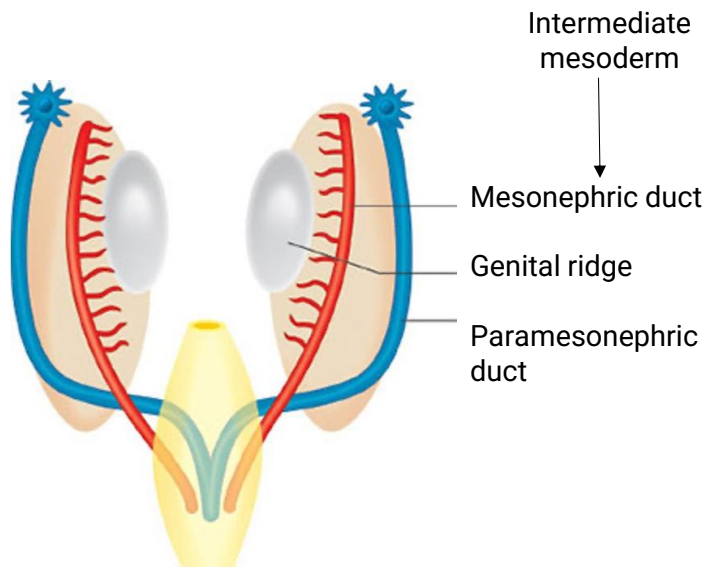
**Azygos vein**  
Rt. Supracardinal vein > Rt. PCV

**Rt. Renal vein**  
Rt. Mesonephric vein  
**Lt. Renal vein**  
Lt. Mesonephric vein + Intersubcardinal anastomosis

**Gonadal vein**  
Caudal part of Subcardinal vein  
**Adrenal vein**  
Cranial part of Subcardinal vein

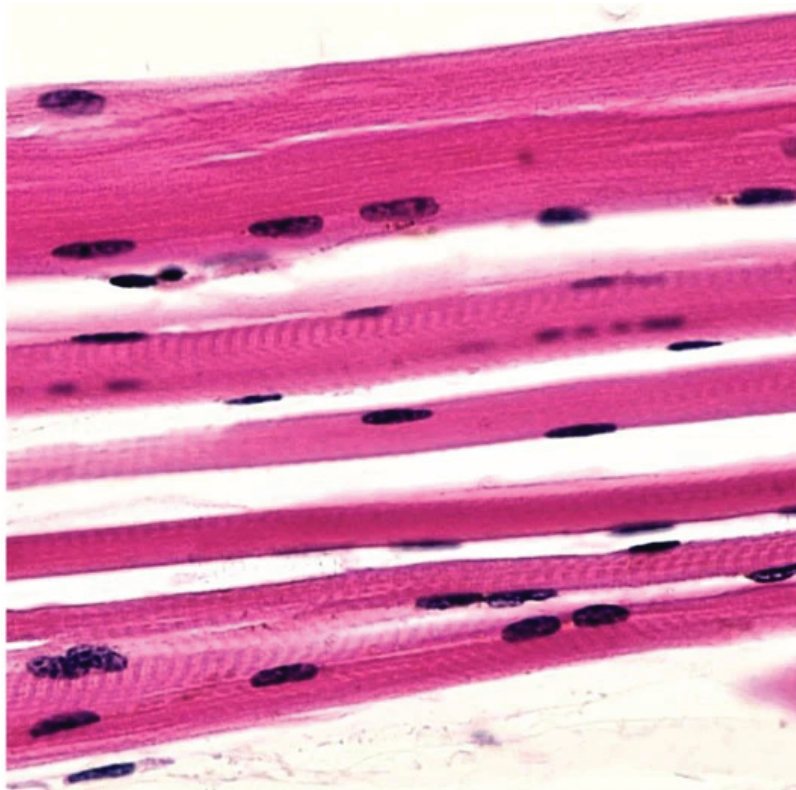
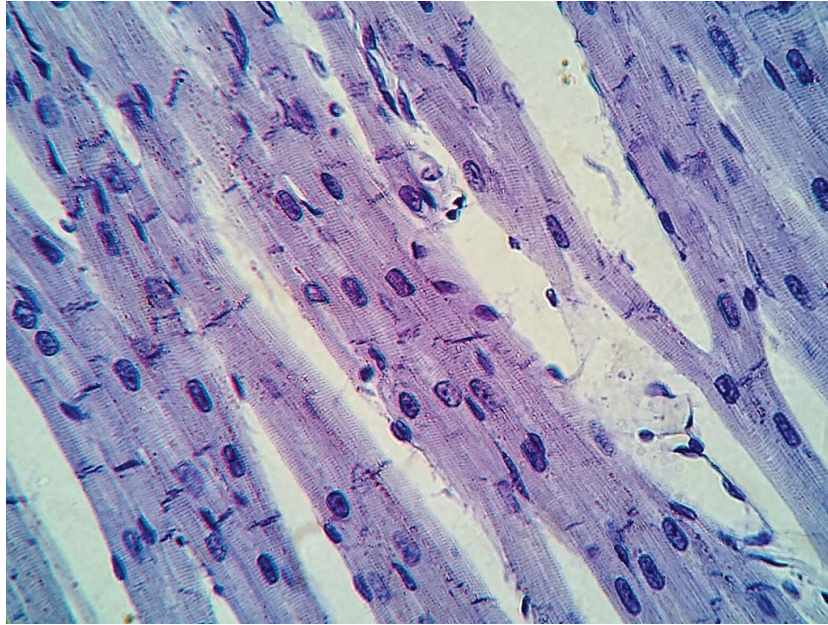



DERIVATIVES OF THE GENITAL DUCTS





HISTOLOGY





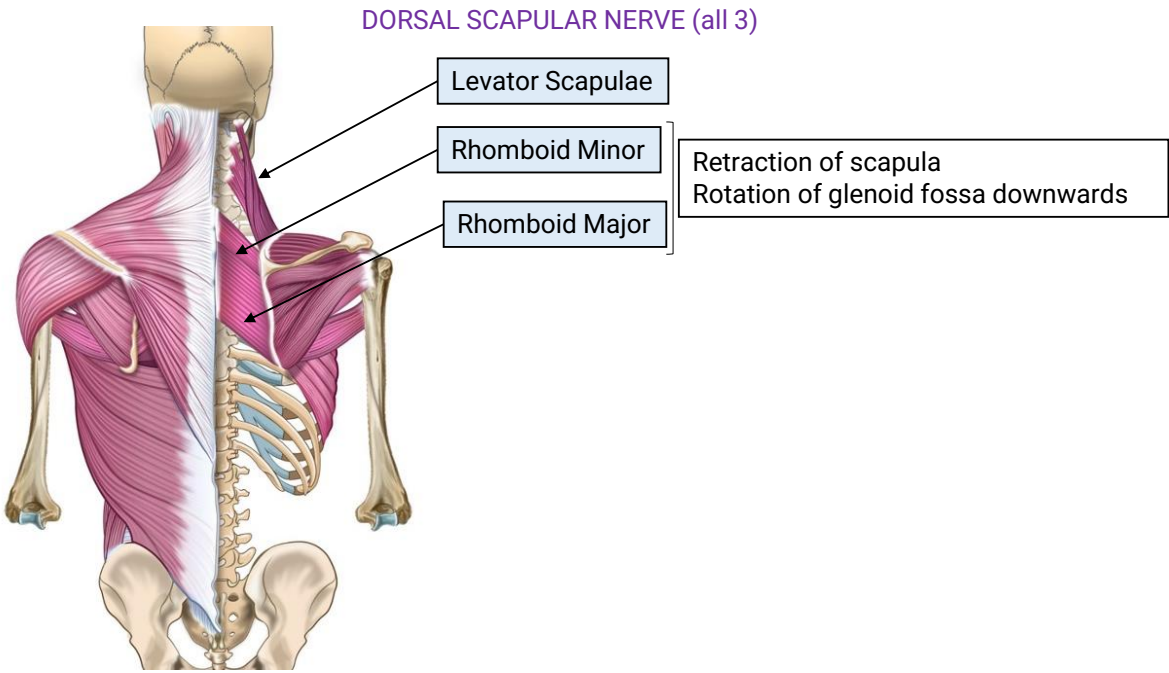


NOTES



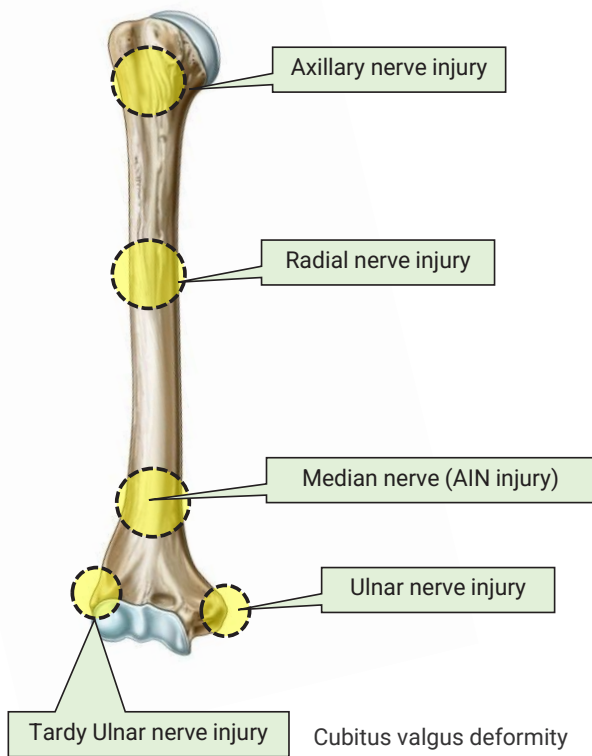
# UPPER LIMB

## VERTEBROSCAPULAR MUSCLES

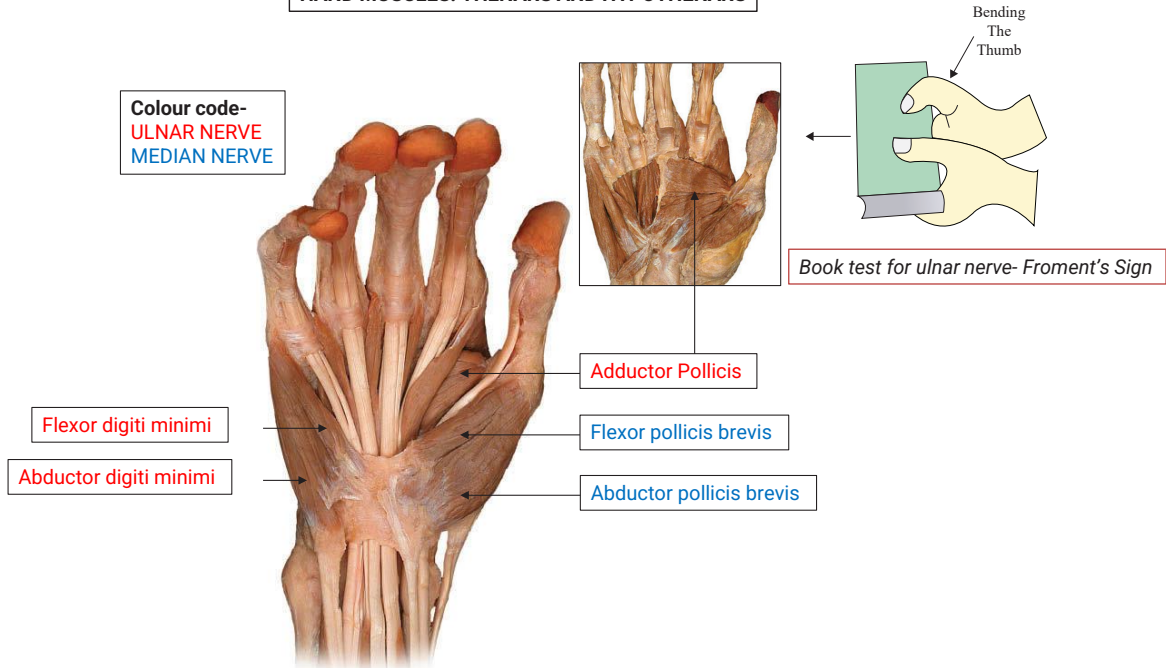




**HUMERAL FRACTURES & NERVE INJURIES**

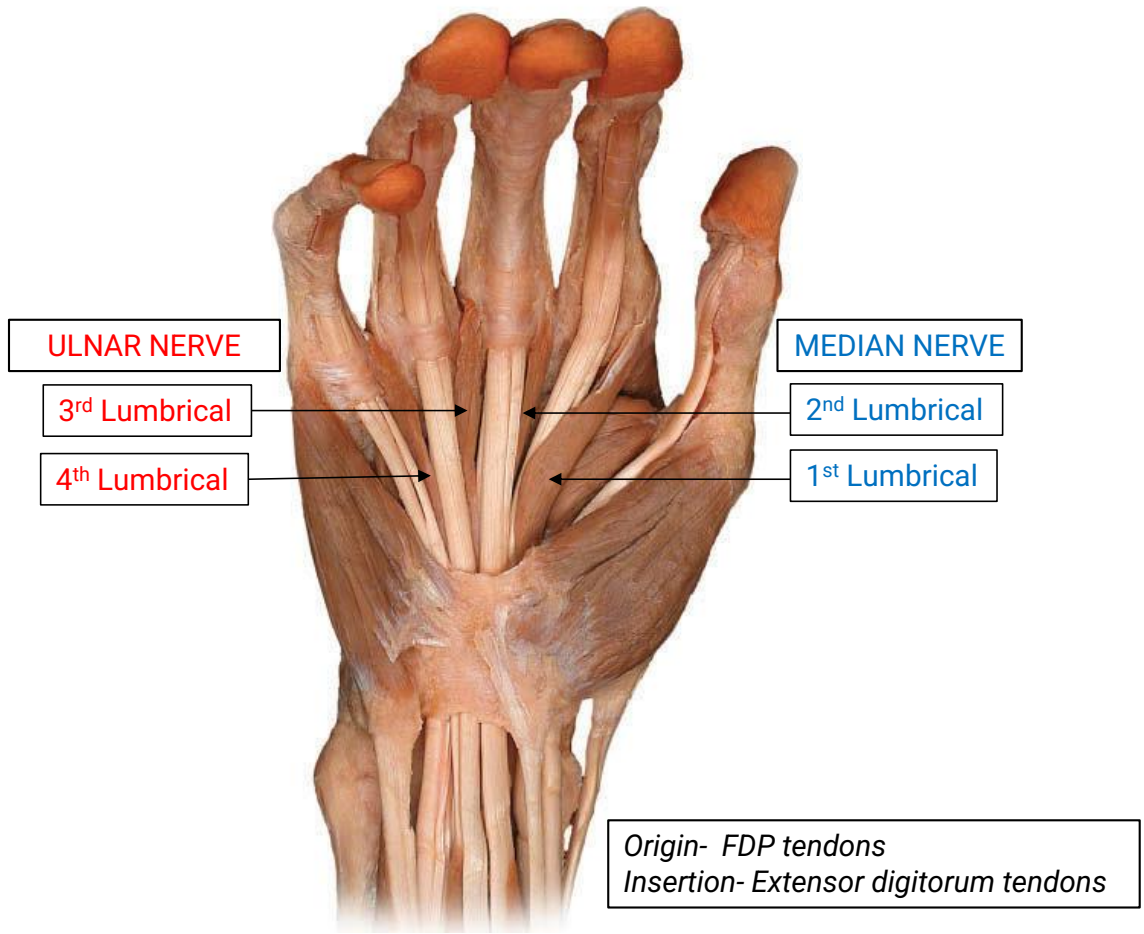


**HAND MUSCLES: THENARS AND HYPOTHENARS**



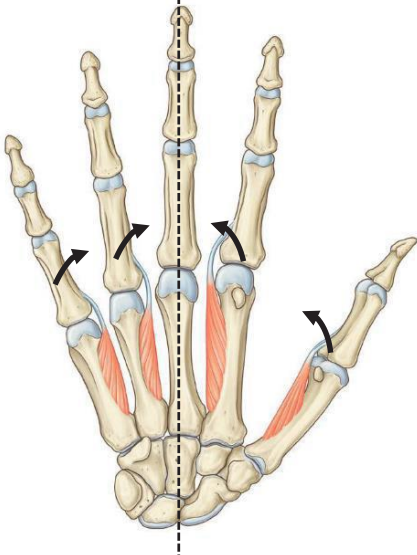


HAND MUSCLES: LUMBRICALS

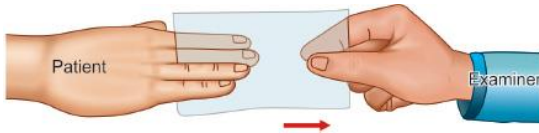


INTEROSSEI- ULNAR NERVE

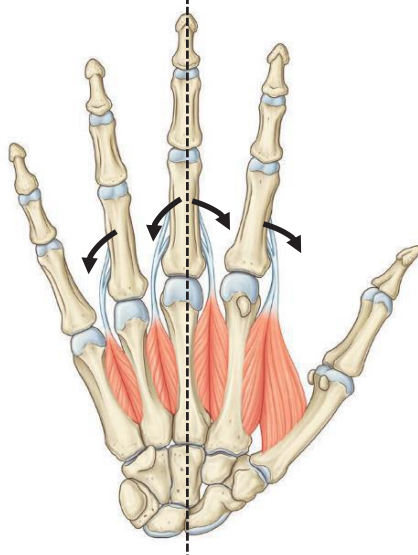
PALMAR INTEROSSEI P-AD



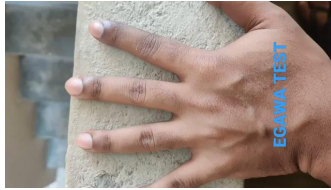- Unipennate
- Absent on middle finger
- Thumb PI may not be present
- TEST- CARD Test

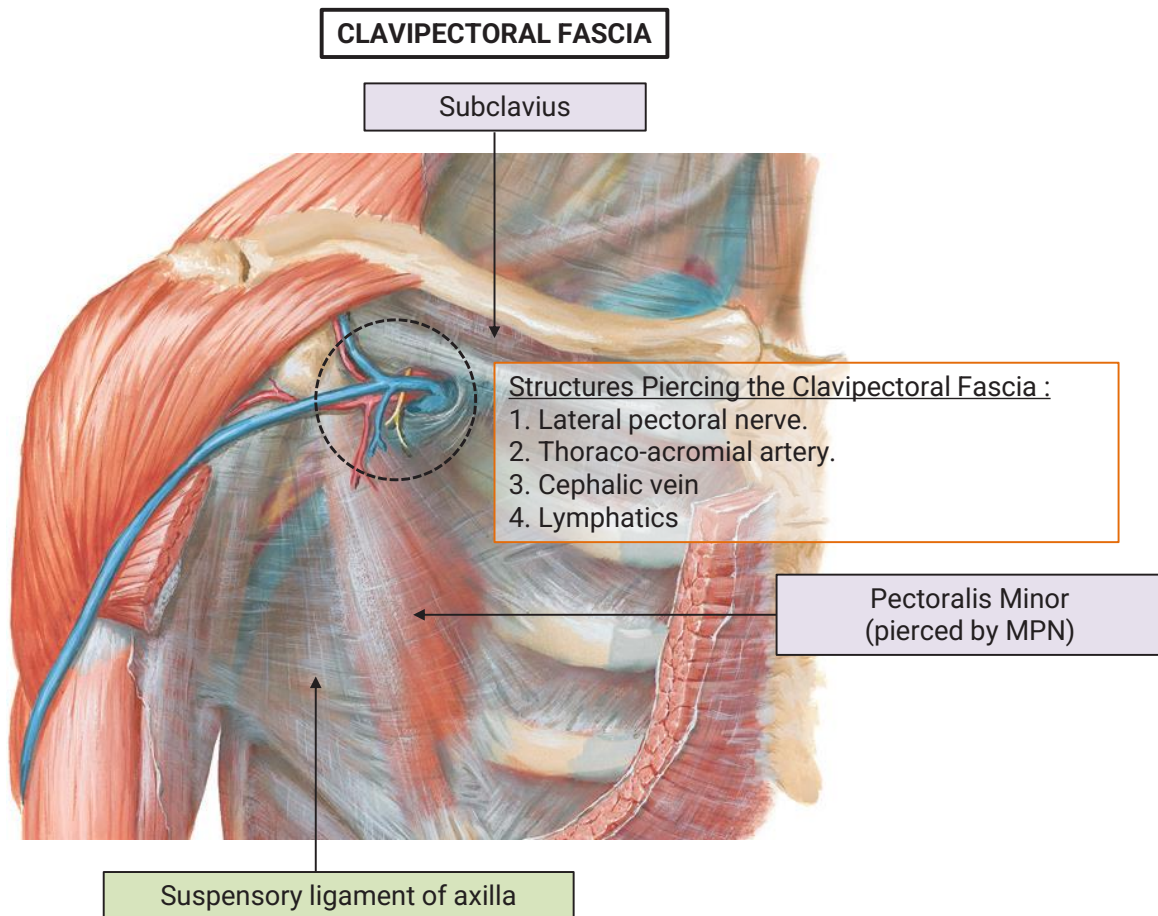


DORSAL INTEROSSEI D-AB

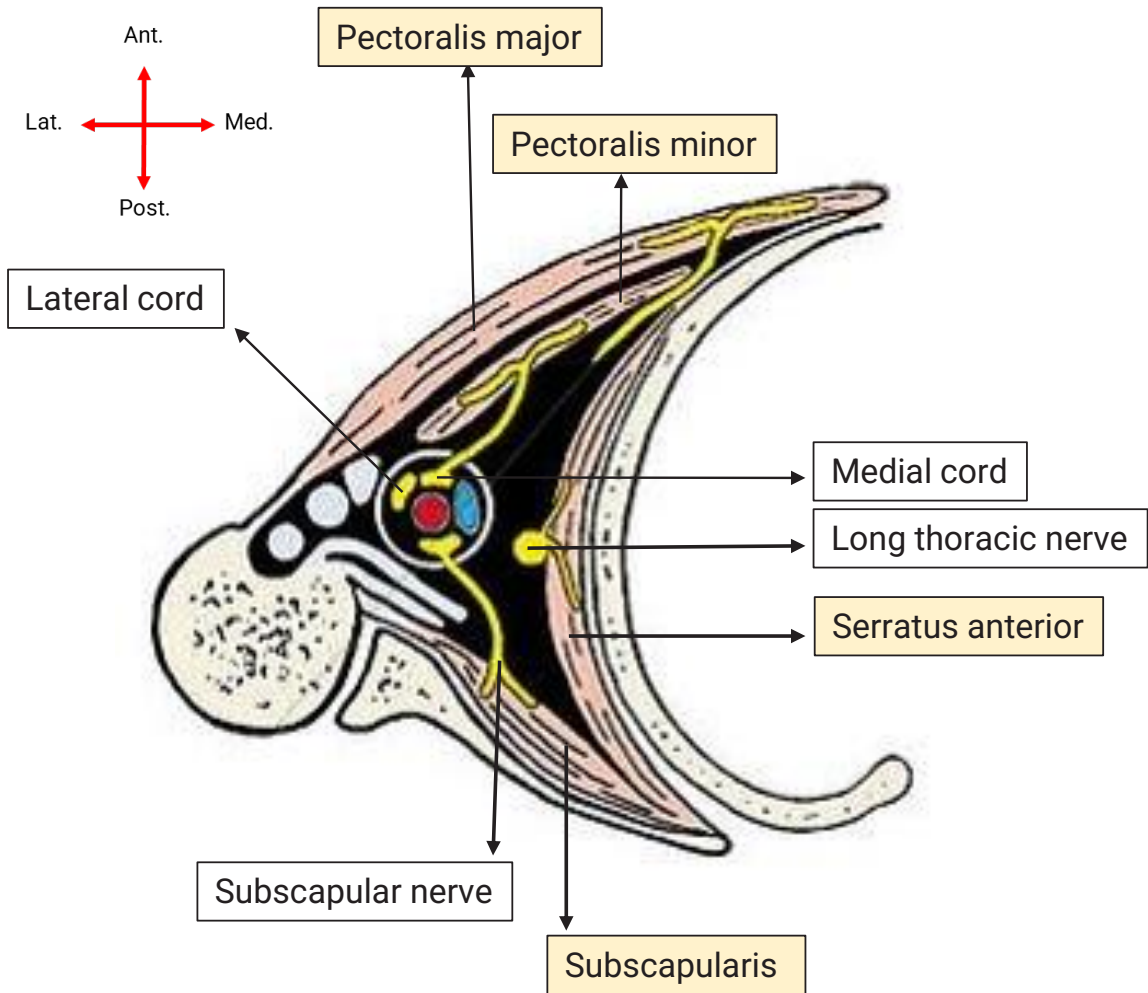


- Bipennate
- Absent on thumb & Little finger
- Middle finger- 2<sup>nd</sup> & 3<sup>rd</sup> dorsal int.
- TEST- EGAWA Test



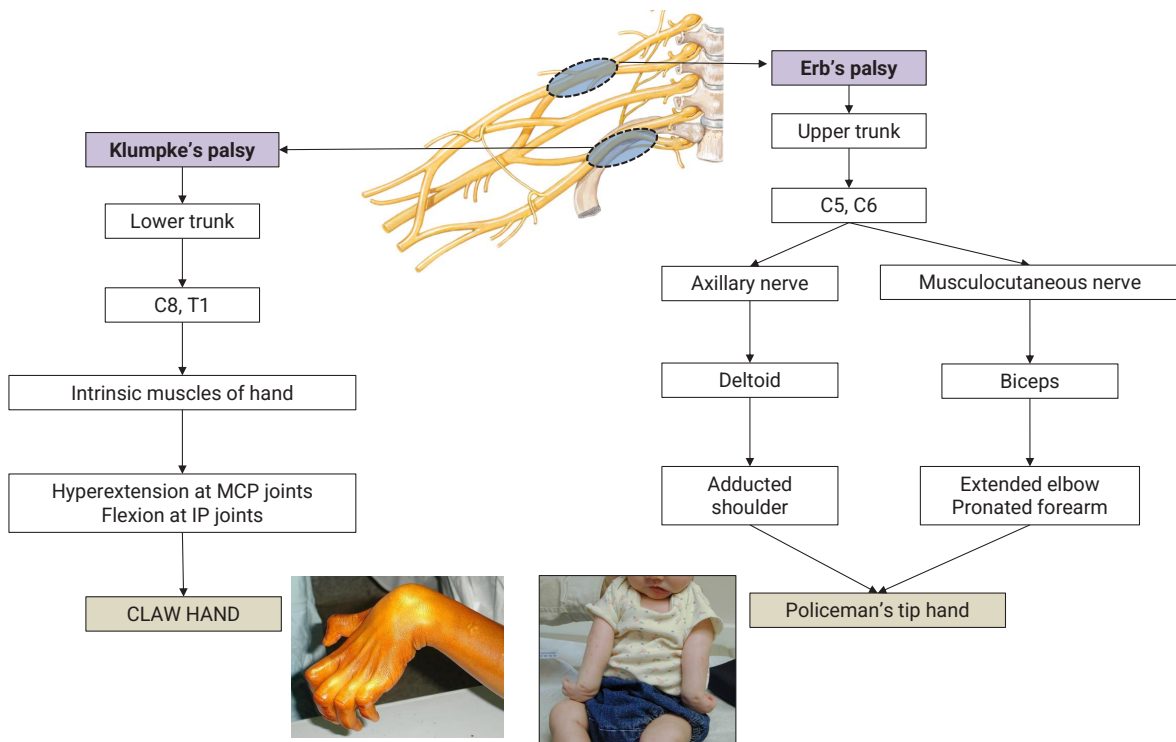
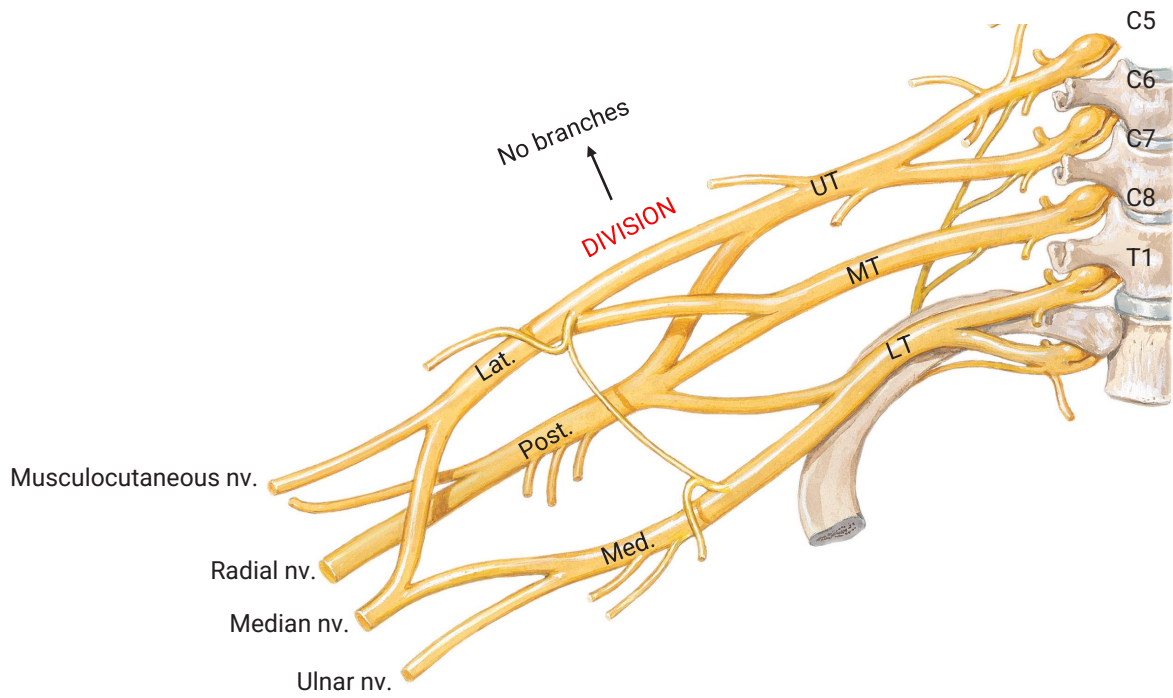


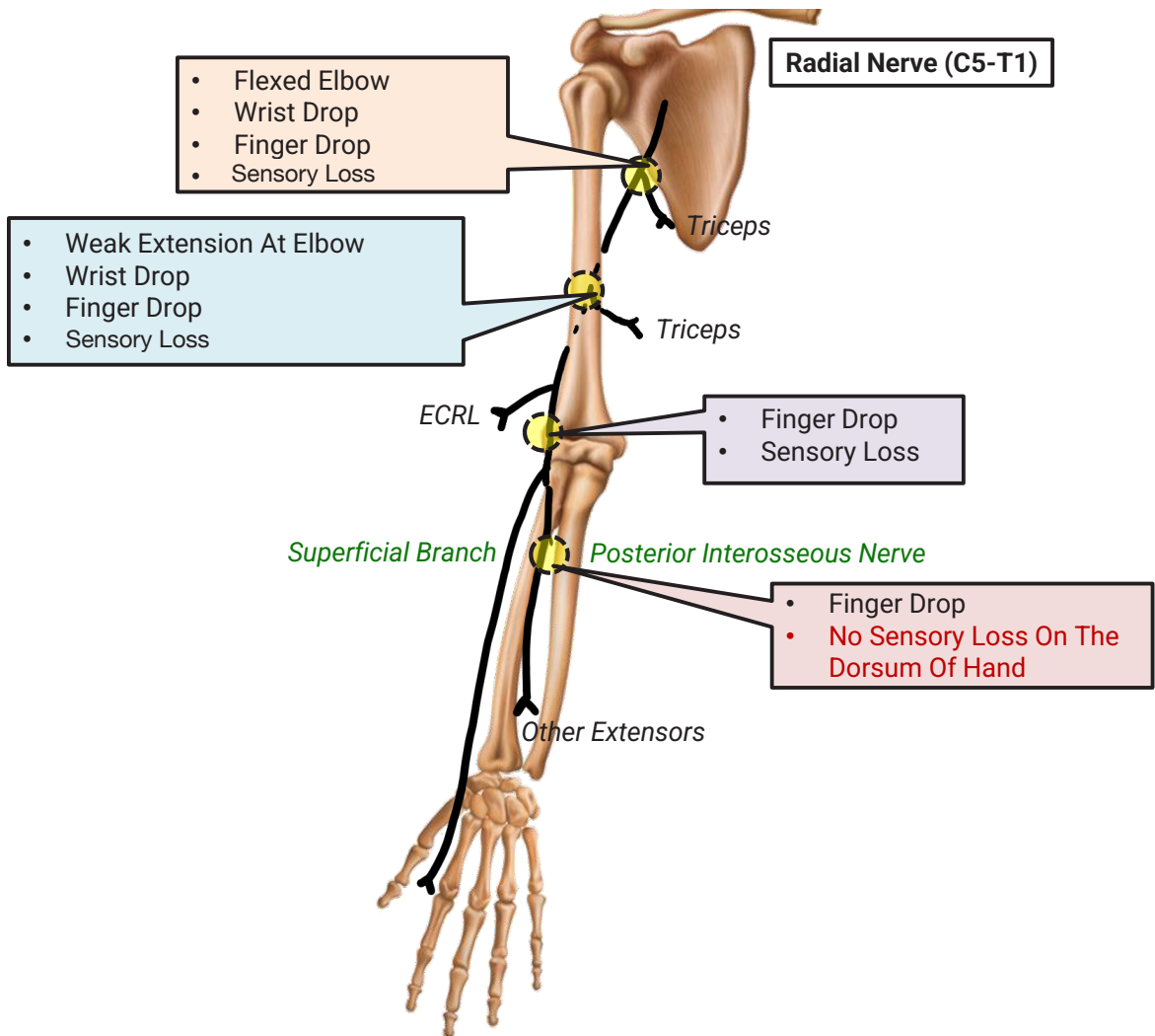
AXILLA: T.S

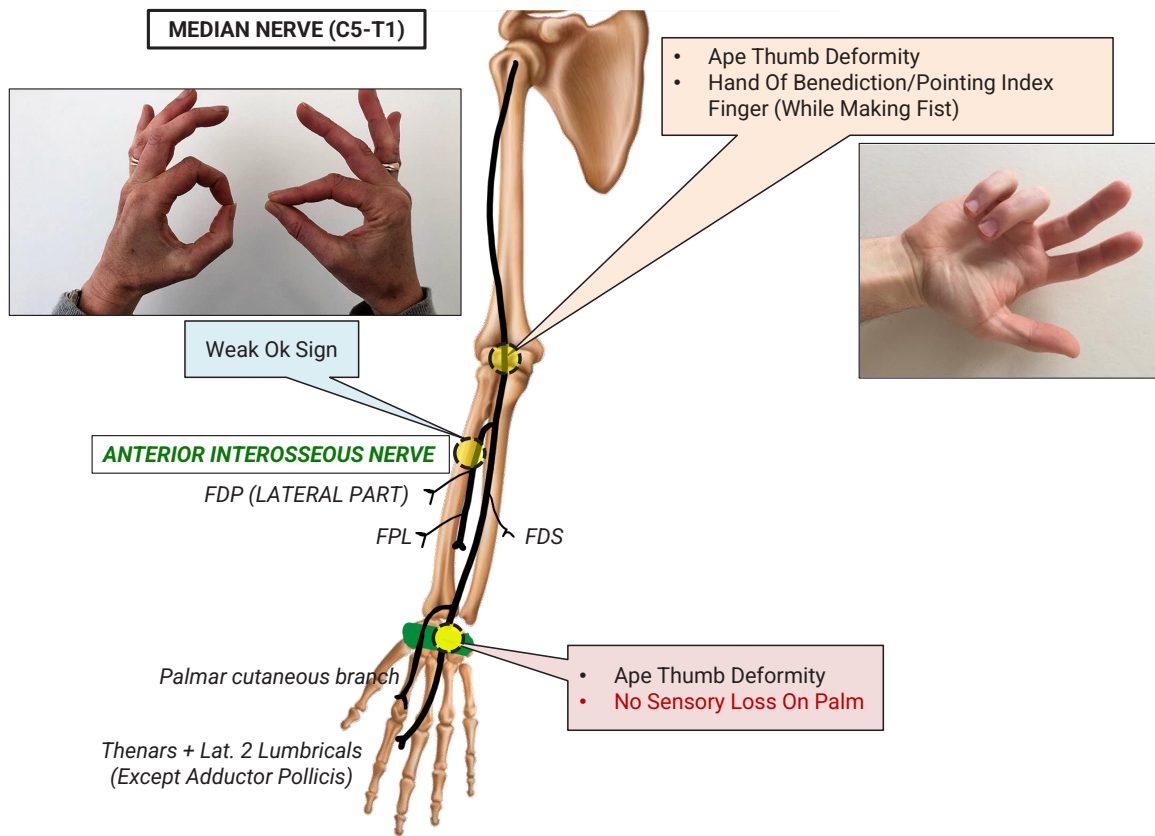


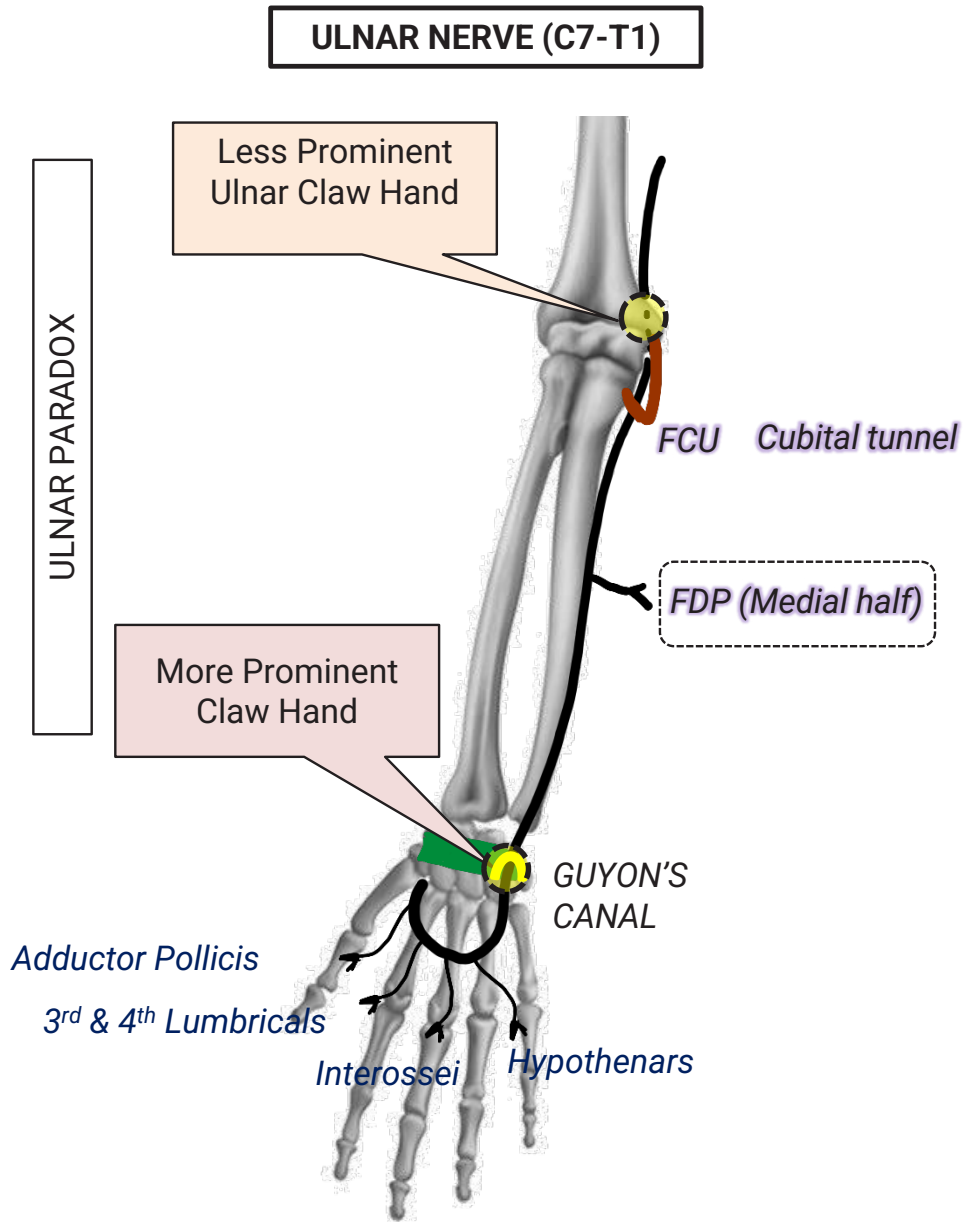


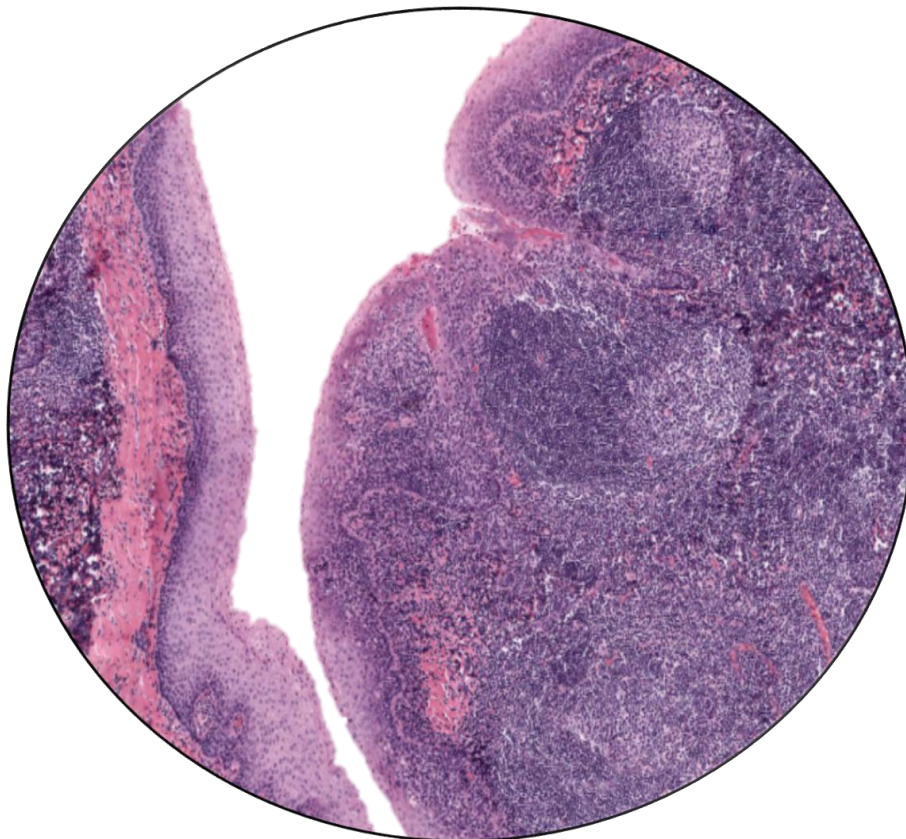
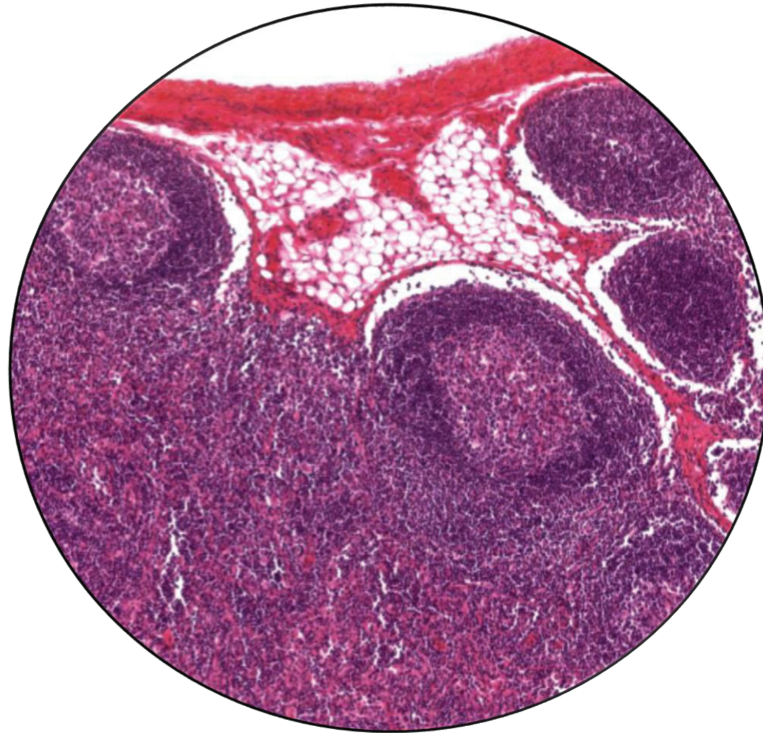
**BRACHIAL PLEXUS**

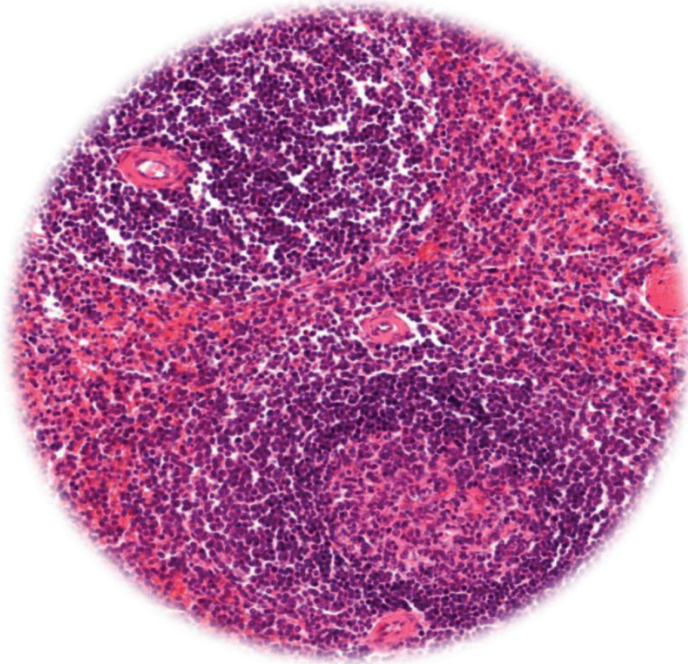
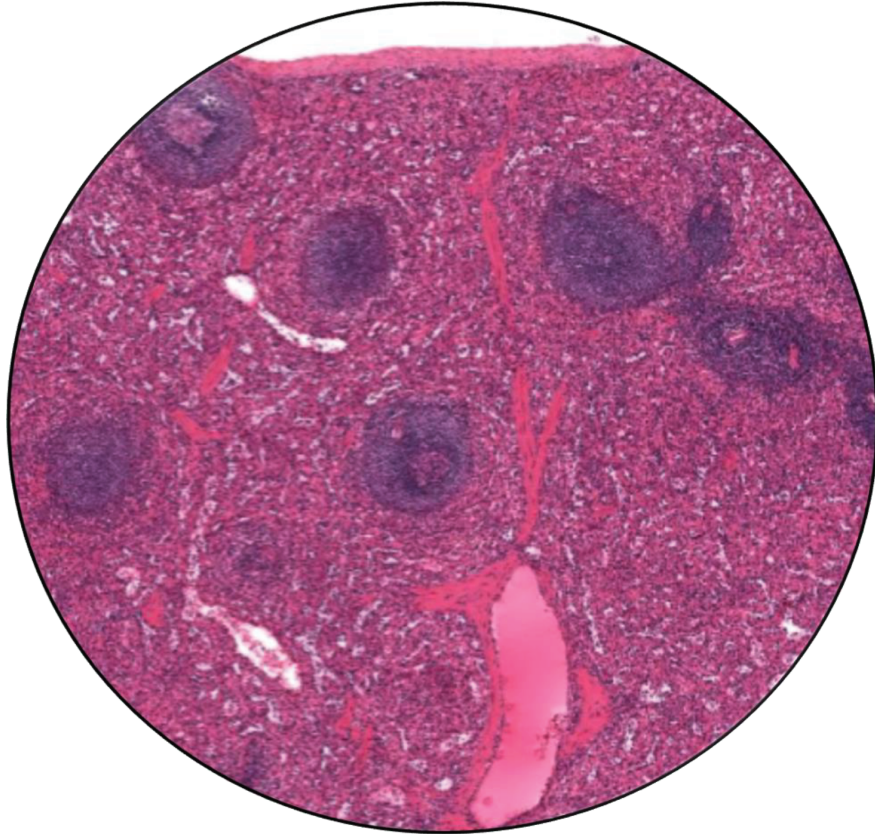


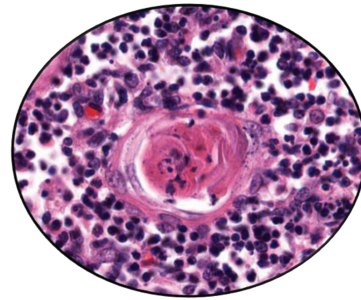
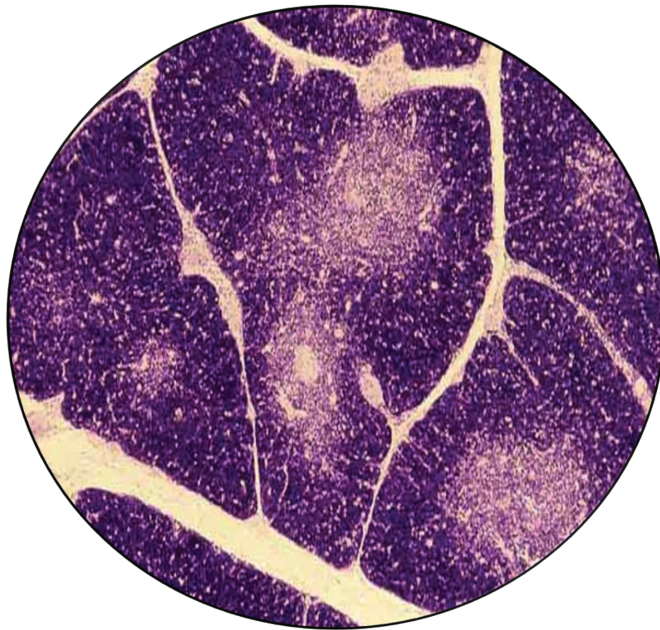










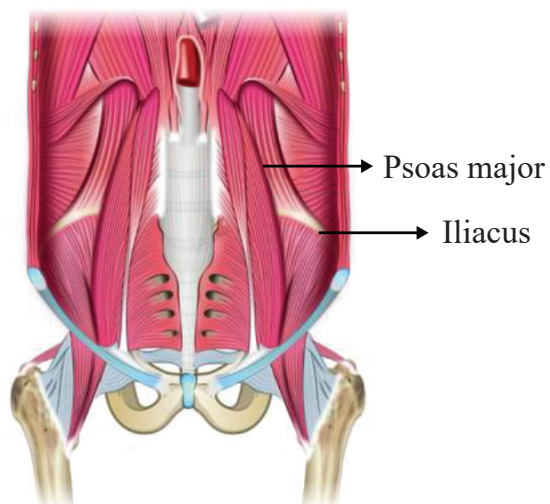
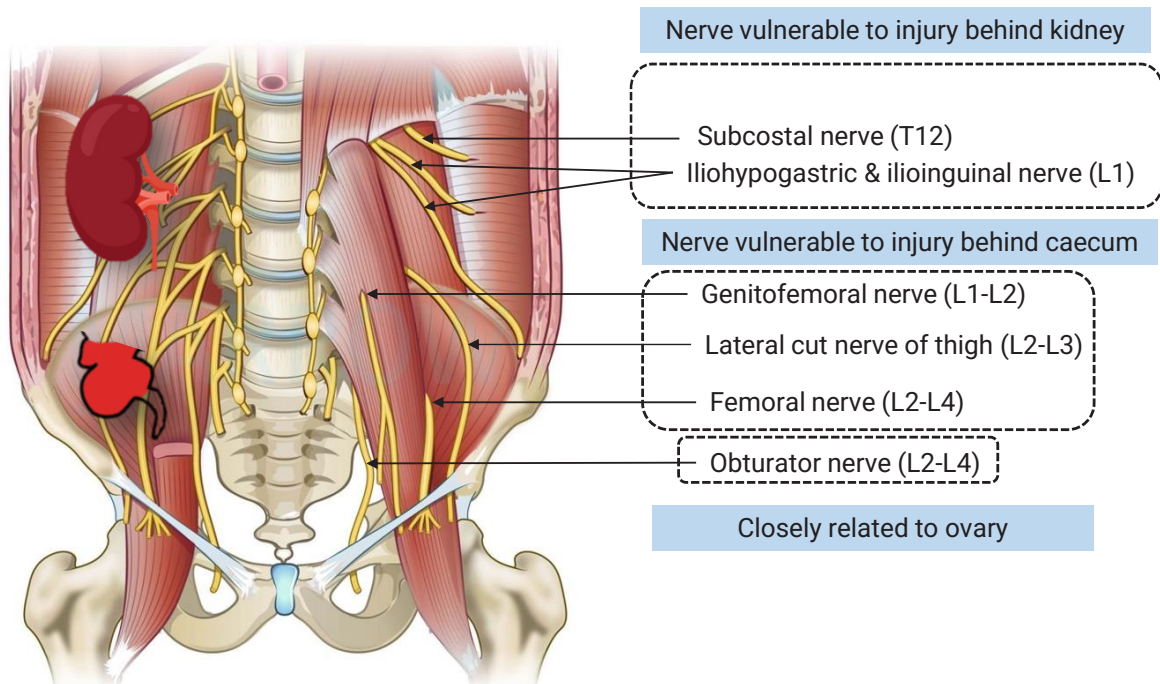


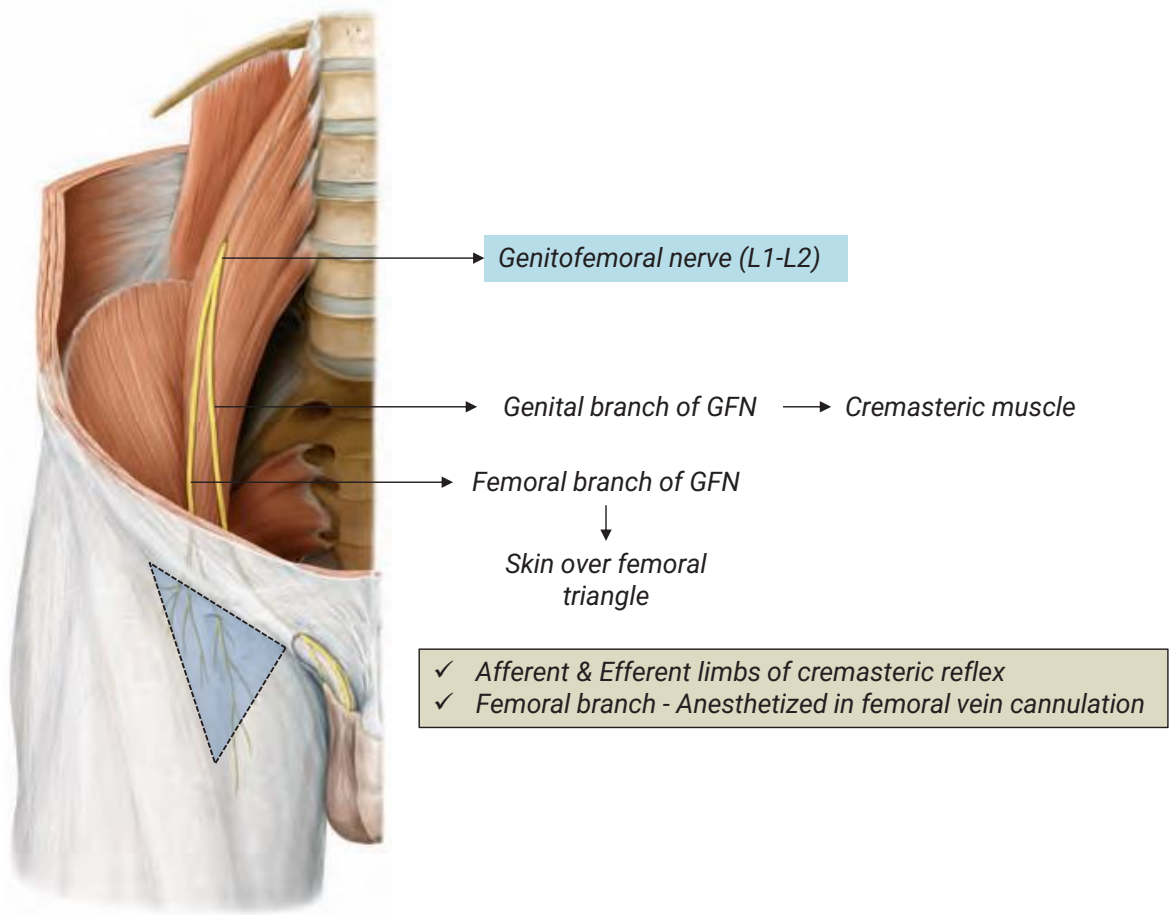
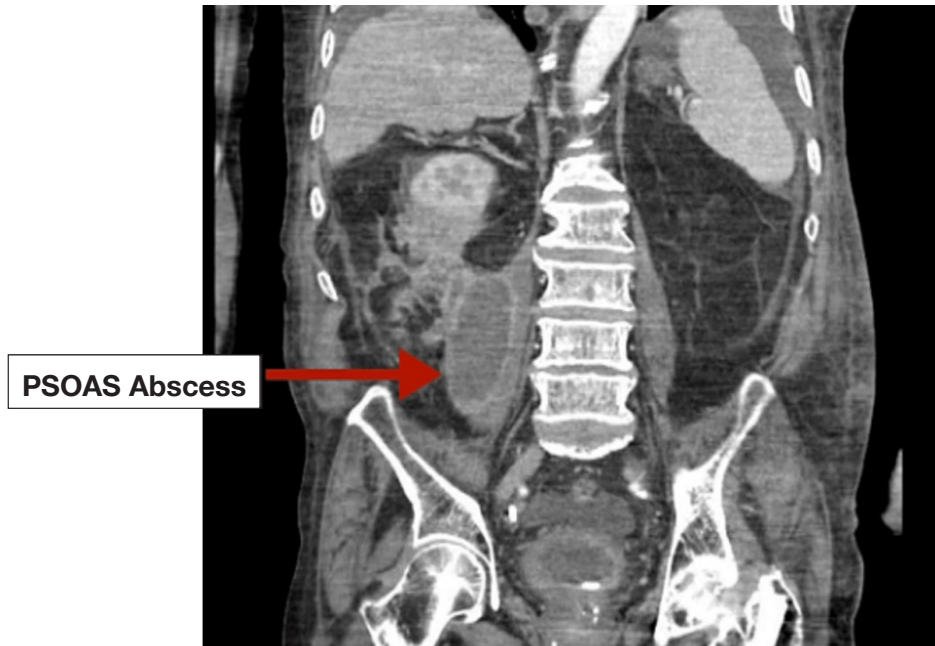


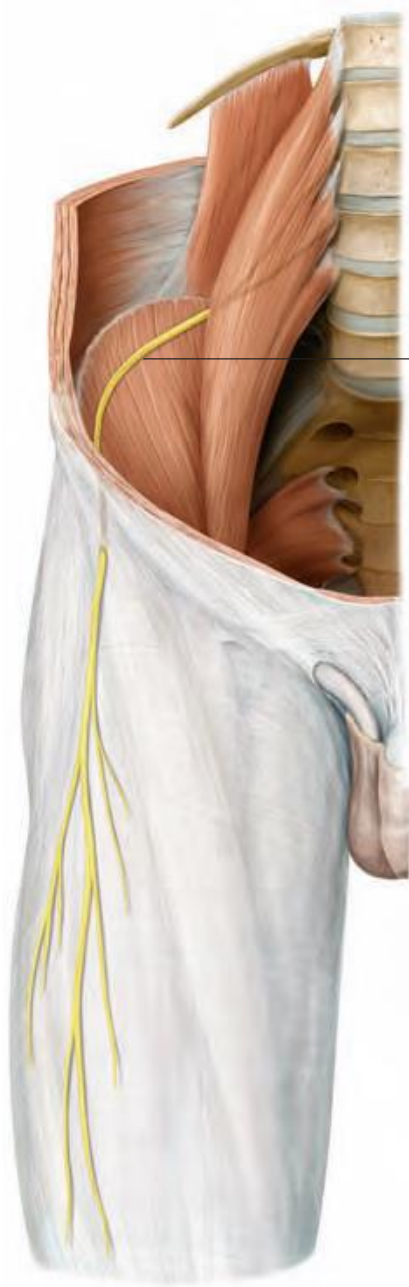## NOTES

## LOWER LIMB

### LUMBAR PLEXUS





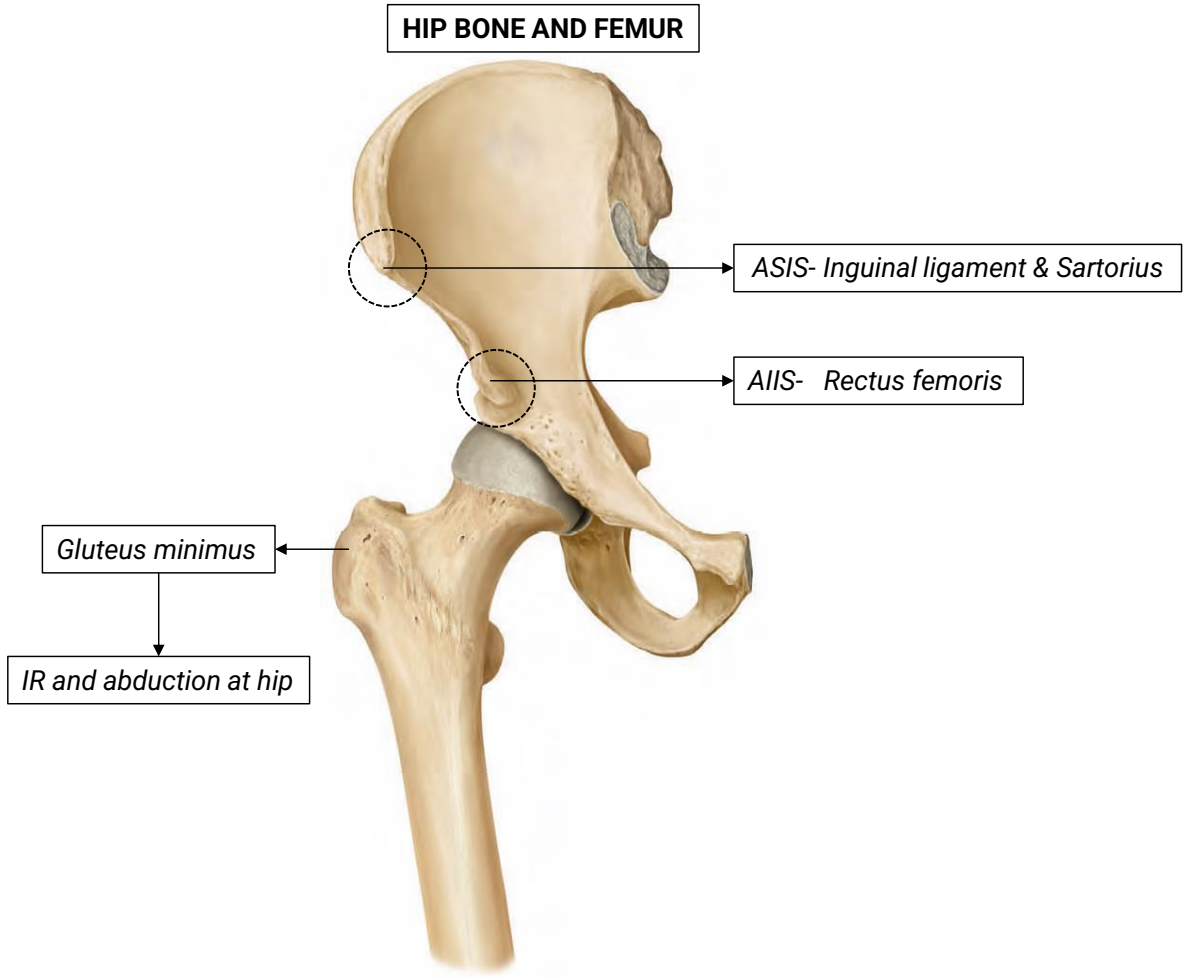


Lateral cutaneous nerve of thigh (L2-L3)

Compression deep to inguinal ligament

Burning stabbing in the lateral thigh area.

Meralgia paresthetica



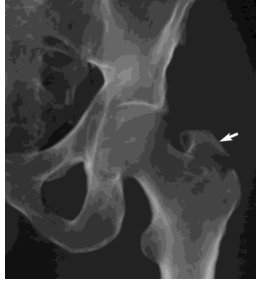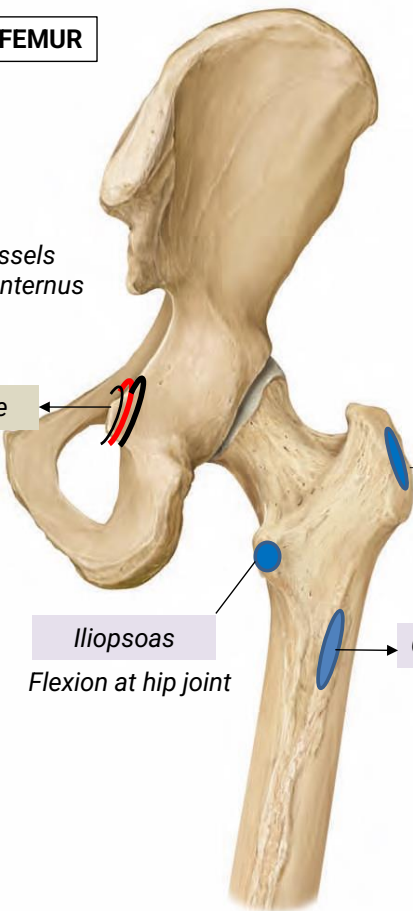


**HIP BONE AND FEMUR**

Muscles of Perineum

P- Pudendal nerve  
I- Internal pudendal vessels  
N- Nerve to obturator internus

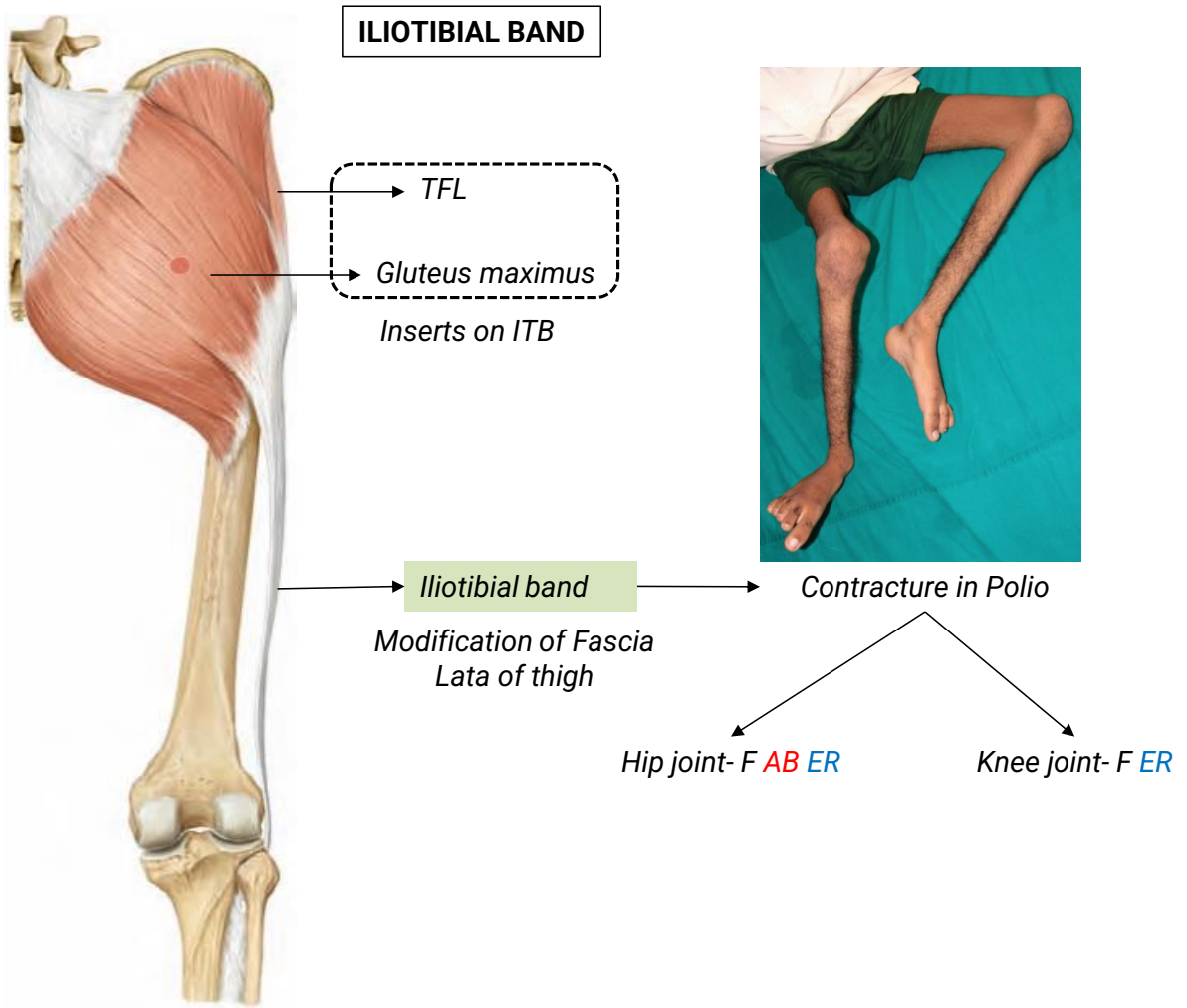
Ischial spine



Gluteus medius  
IR & Abduction at hip

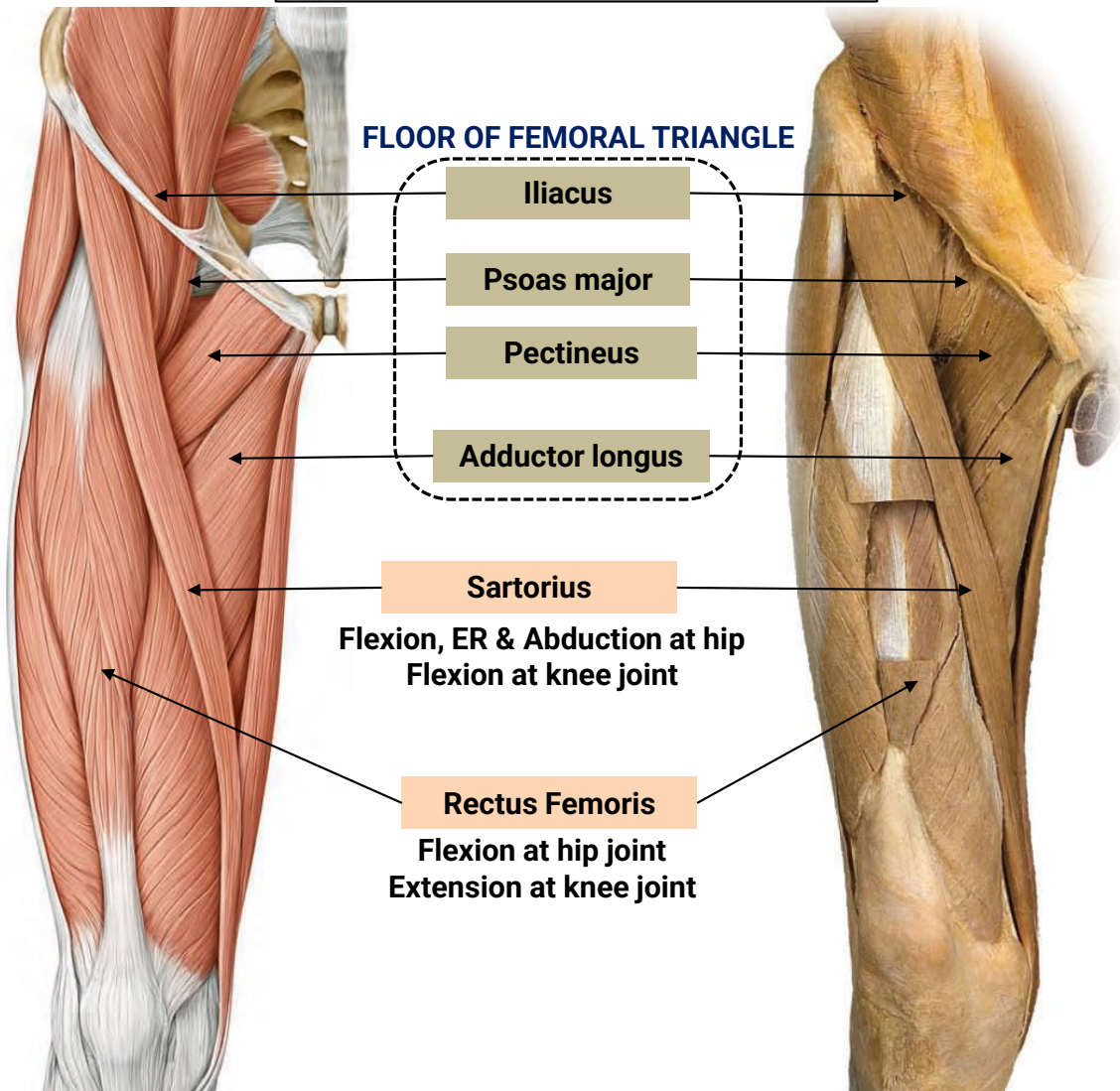
Iliopsoas  
Flexion at hip joint

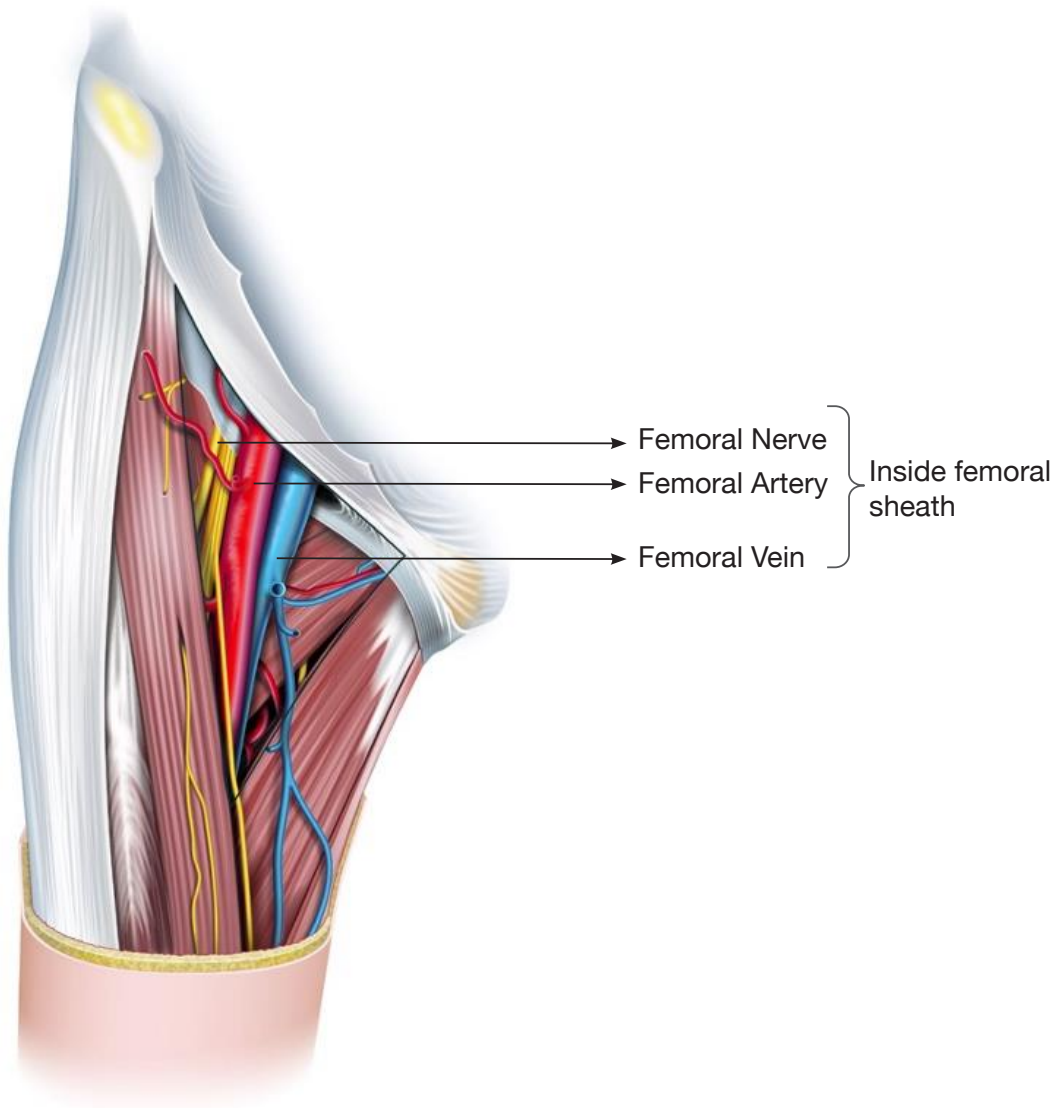
Gluteus maximus (on gluteal tuberosity)  
Extension & ER at hip joint





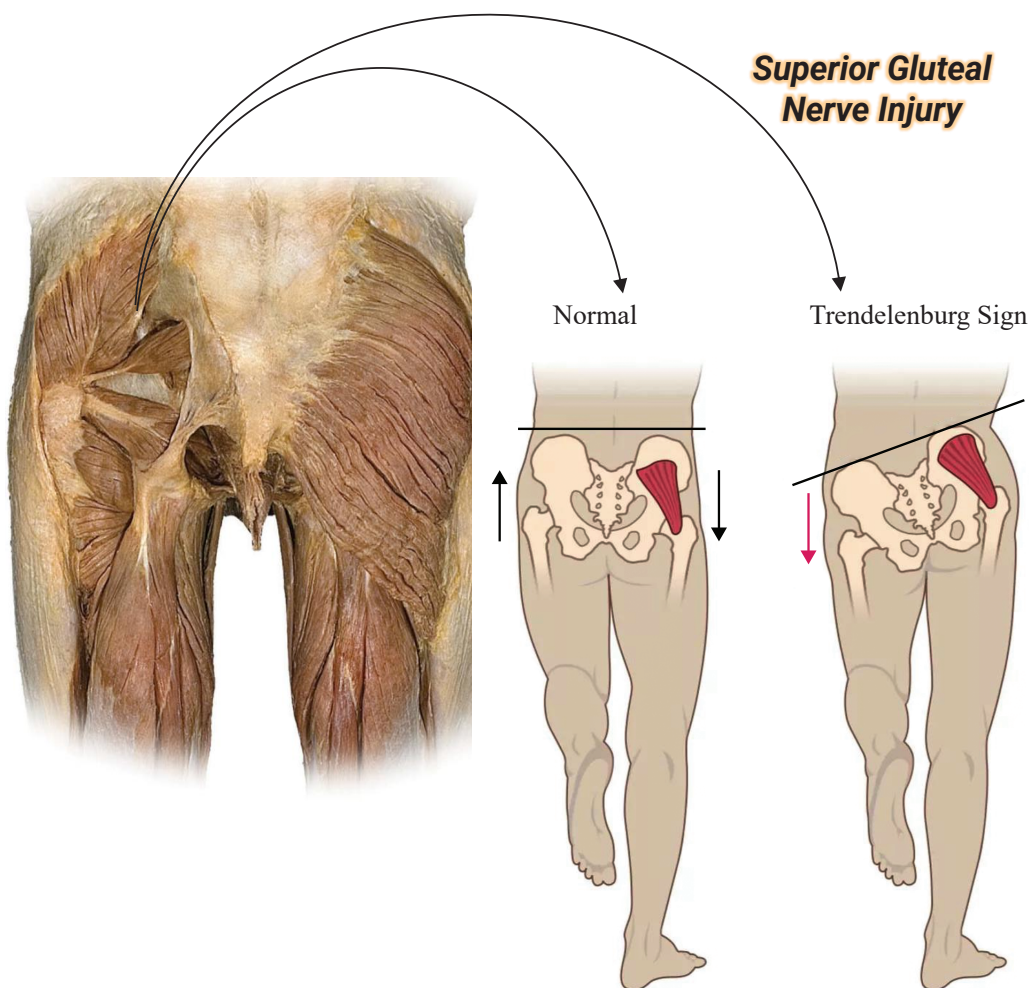
**ANTERIOR THIGH & FEMORAL TRIANGLE**





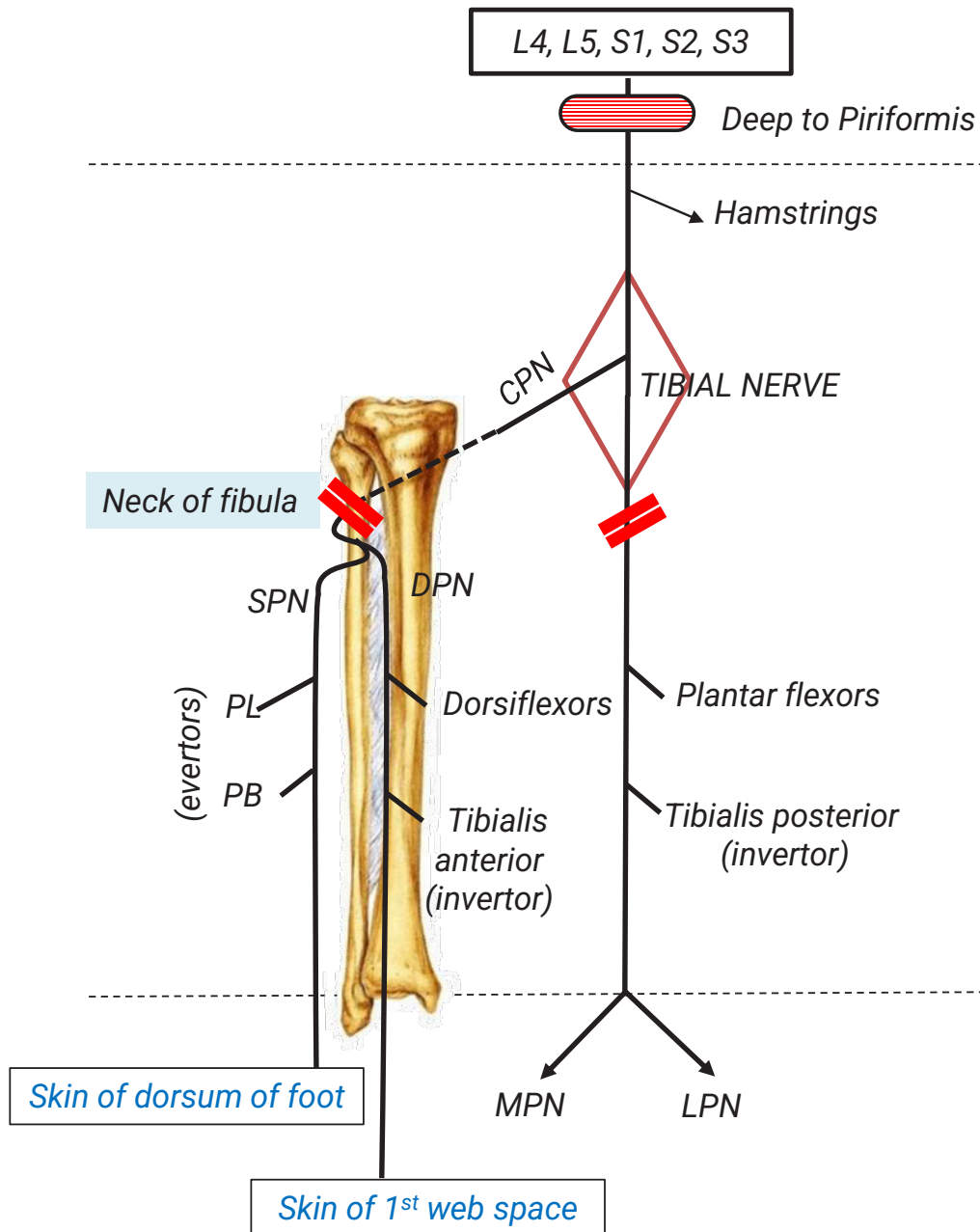


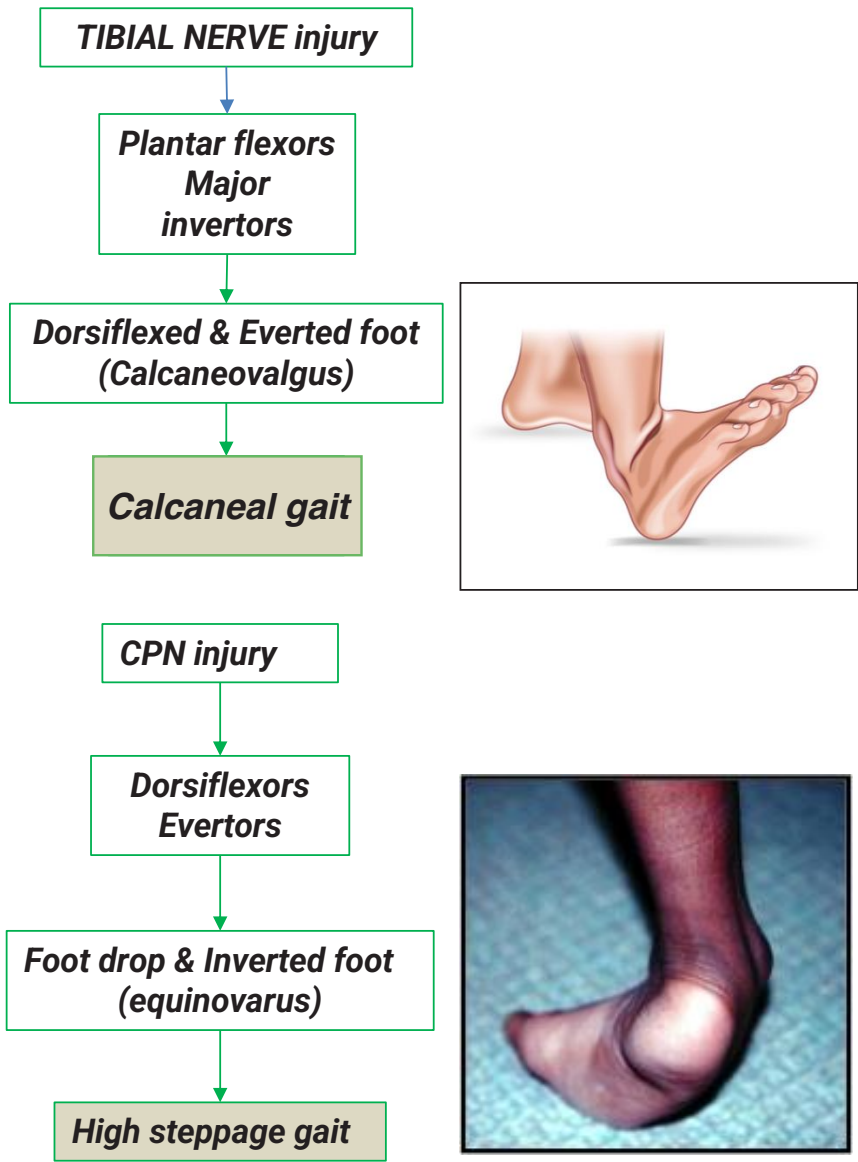
**GLUTEAL REGION**



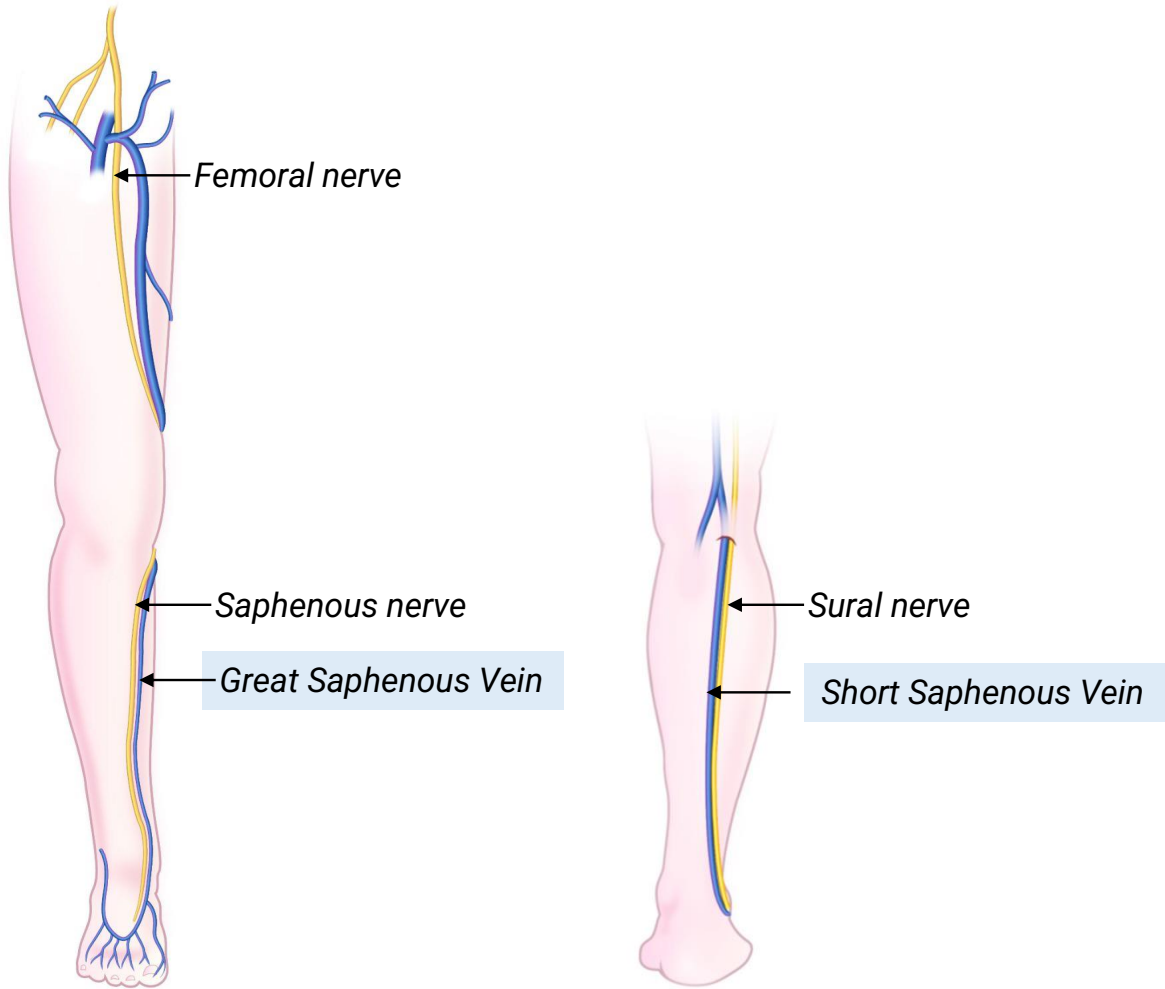


SCIATIC NERVE



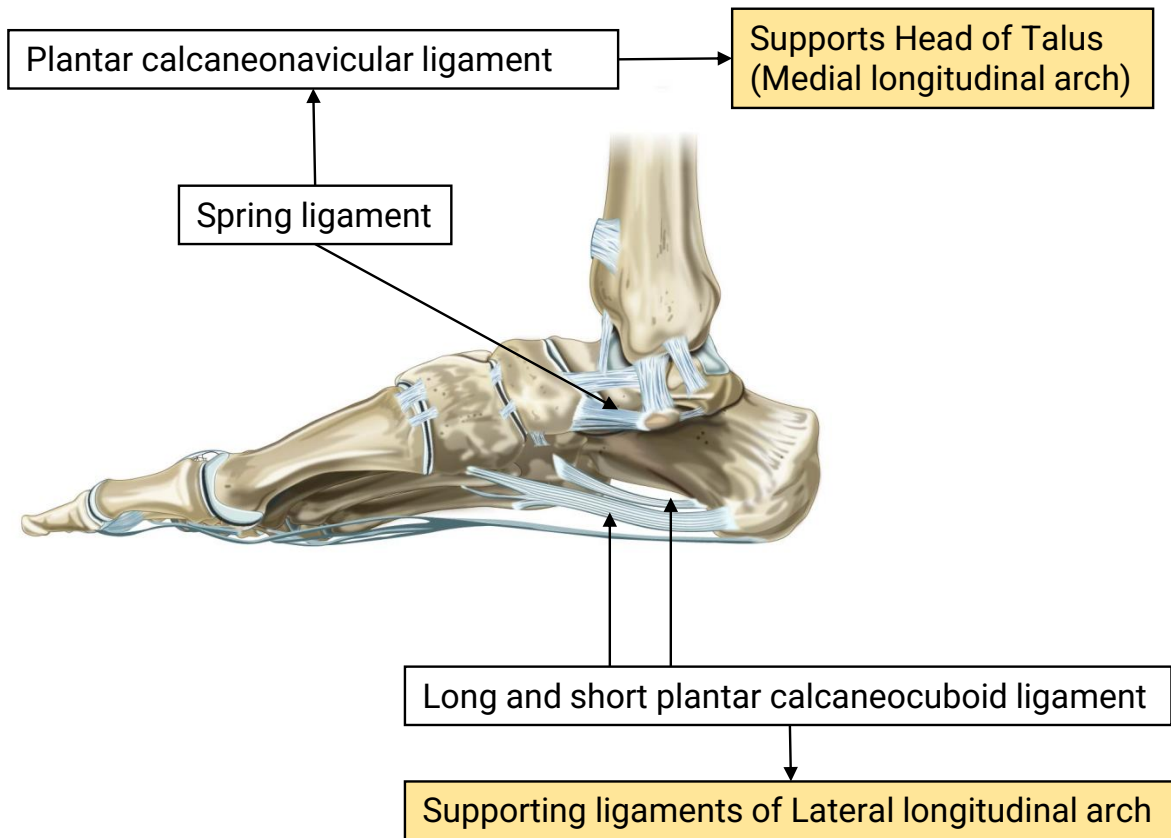


**GREAT SAPHENOUS VEIN AND SHORT SAPHENOUS VEIN**

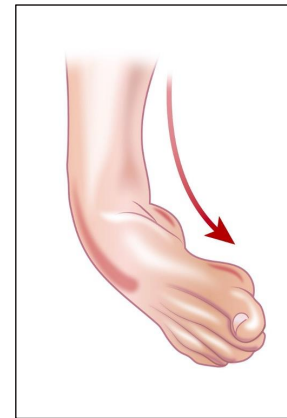
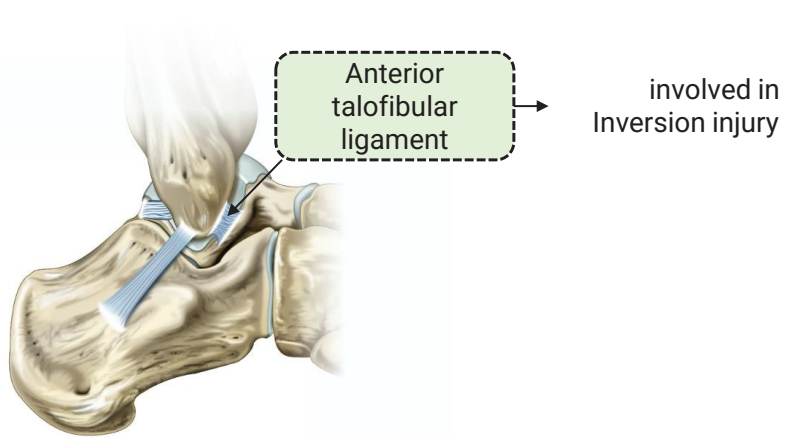
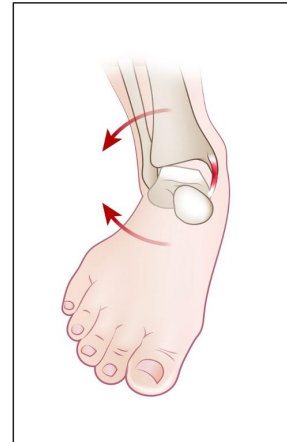
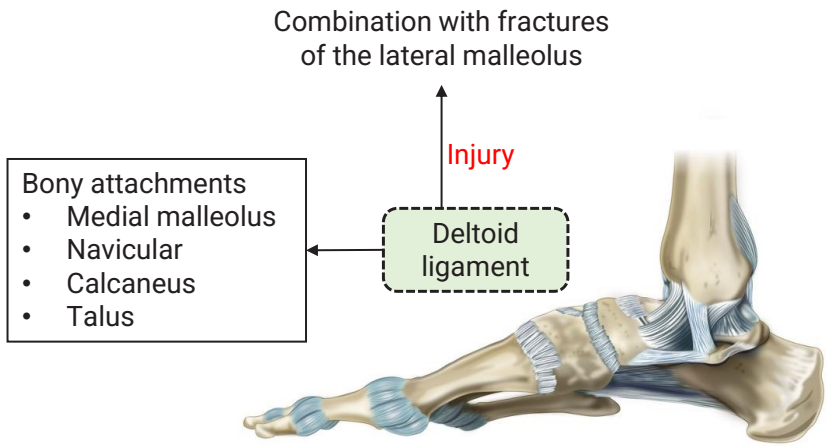




**LIGAMENTS OF FOOT AND ANKLE**

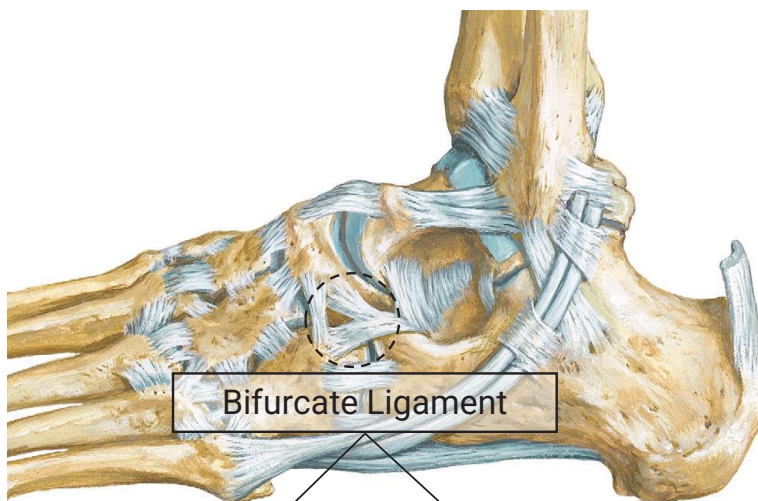


LIGAMENTS OF FOOT AND ANKLE



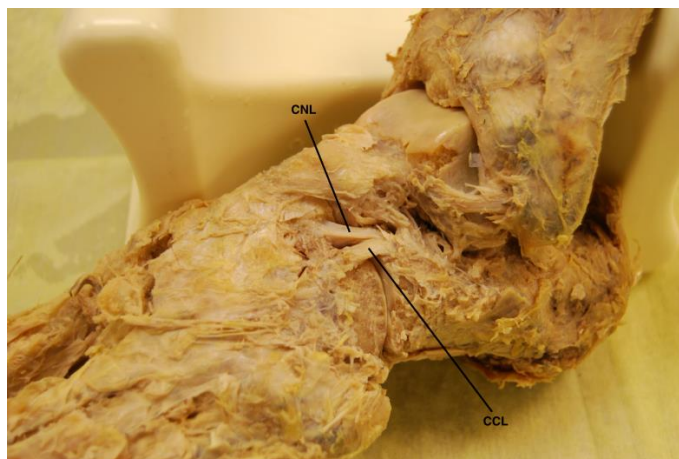


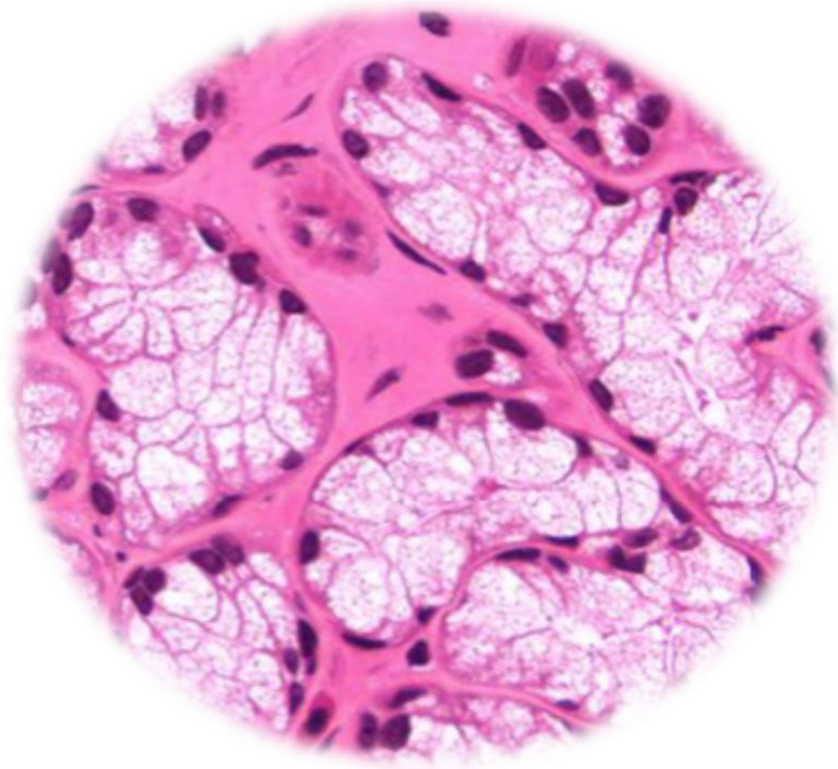
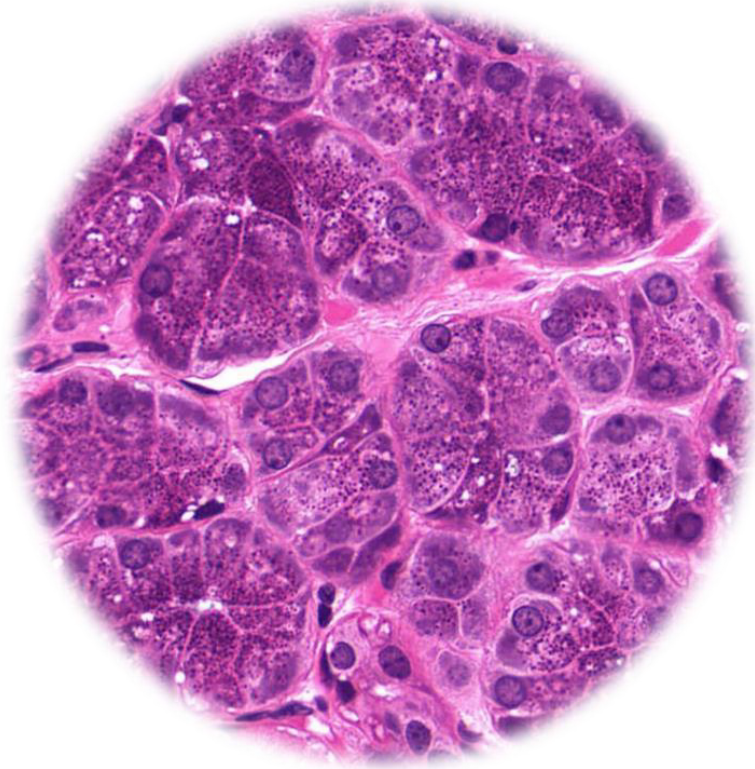
LIGAMENTS OF FOOT AND ANKLE

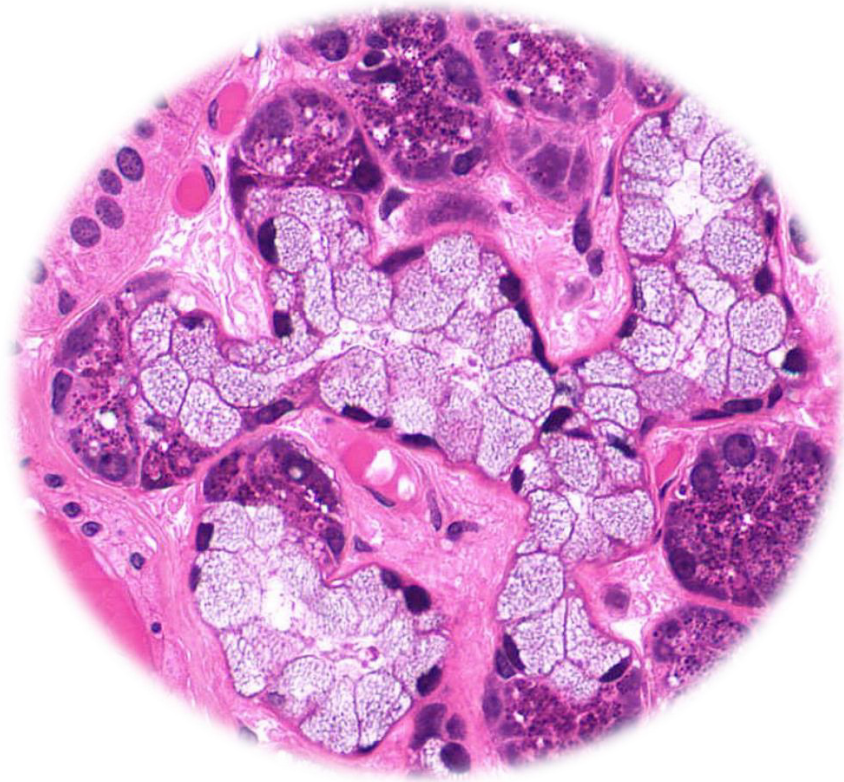


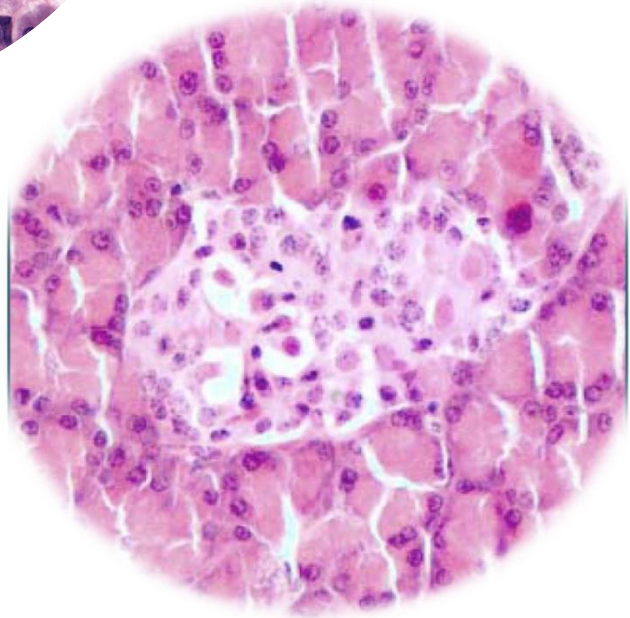
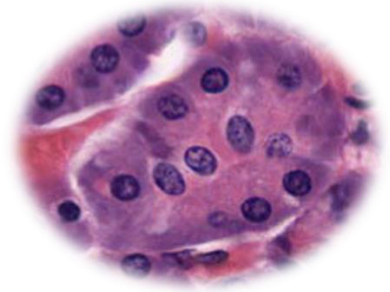
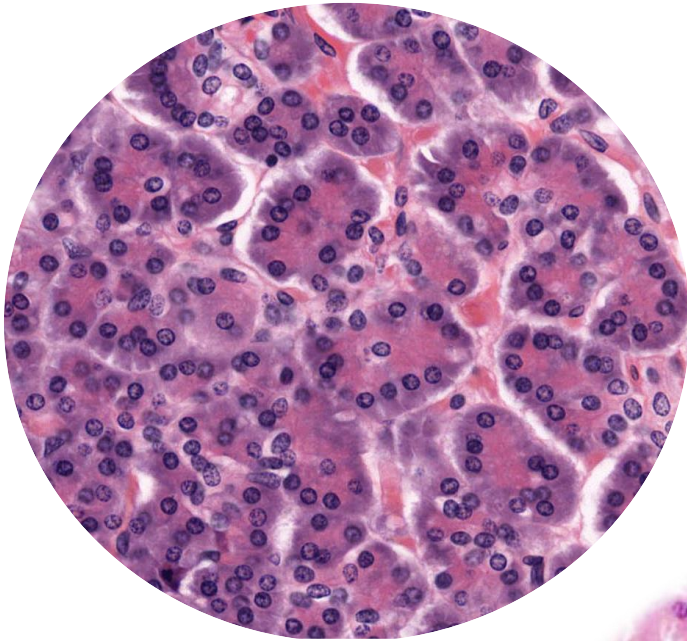
Calcaneocuboid ligament (CCL)

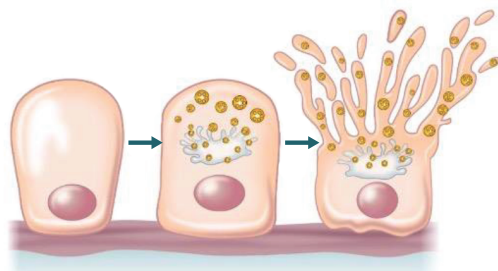
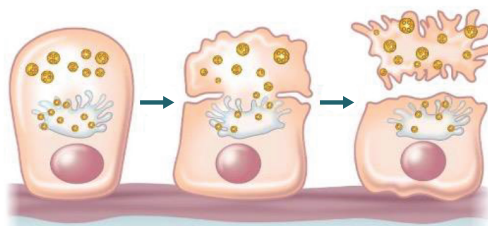
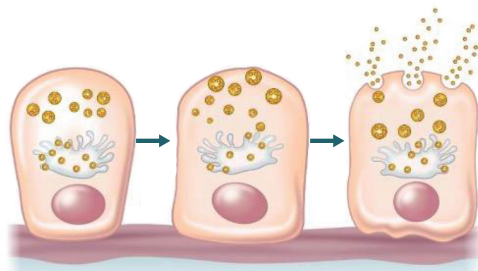
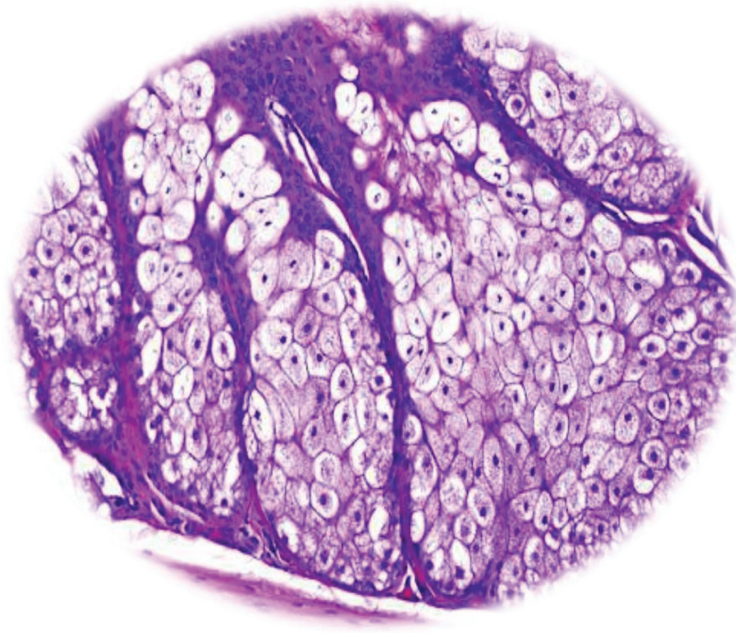
Calcaneonavicular ligament (CNL)













NOTES



# HEAD, NECK & FACE

CRANIAL NERVE NUCLEI AND COLUMNS

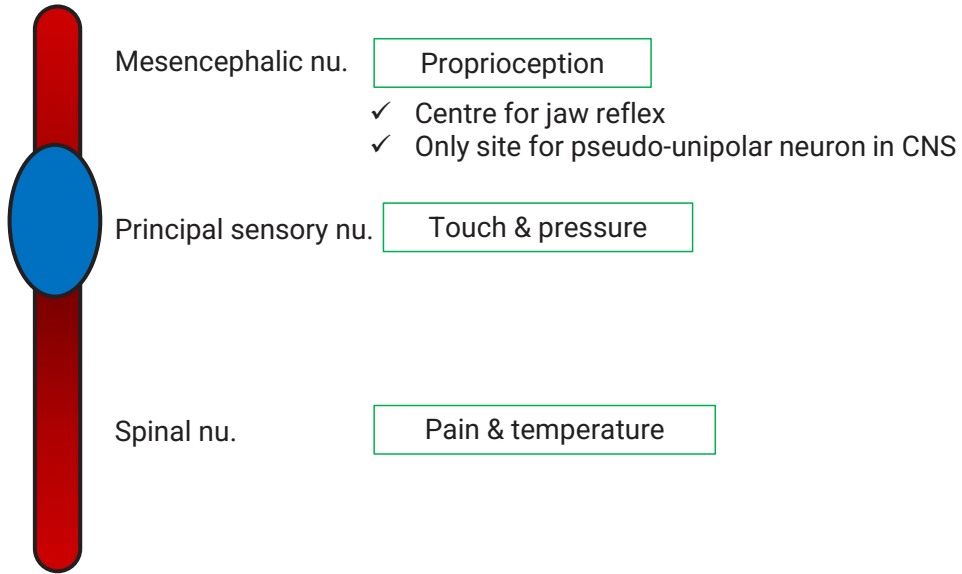
All Columns except first and last  
↓  
VII, IX and X nerves

Columns for III nerve- GSE and GVE

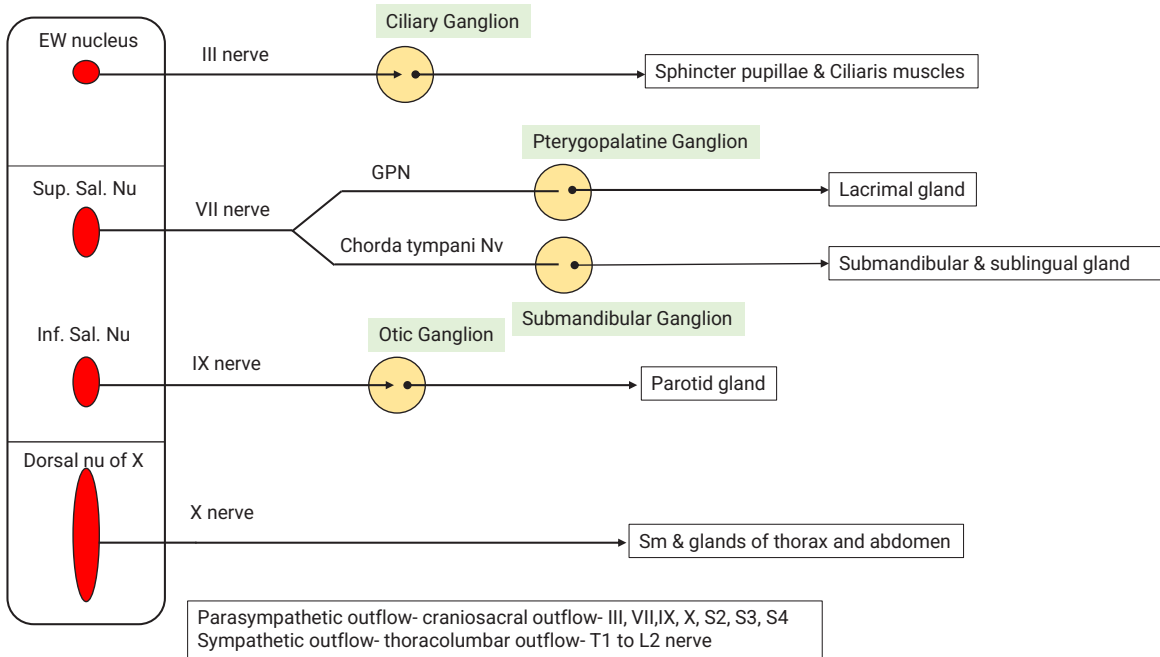
	GSE	SVE	GVE	GVA SVA	GSA	SSA
MIB BRAIN	● III ● IV		● EW		Mesencephalic nu.	
PONS	● VI	● V3 ● VII	● SSN ● ISN		Principal sensory nu.	
MEDULLA	XII	IX X XI NA	Dorsal nu of X	NTS	Spinal nu.	V ● C

**GSA**

TRIGEMINAL NUCLEI

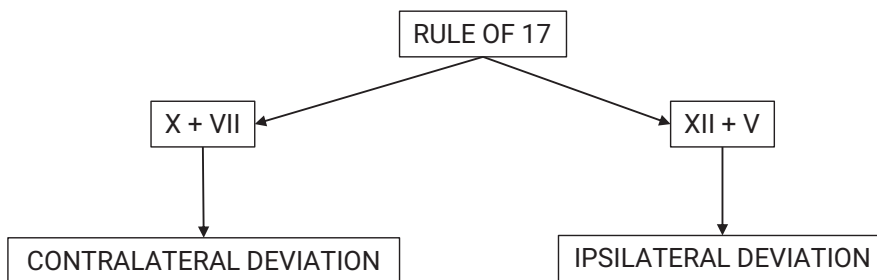


**GVE**

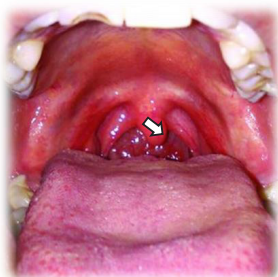



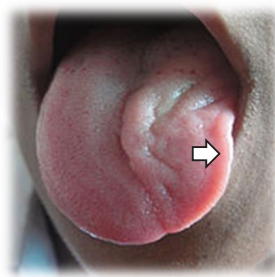CRANIAL NUCLEI COLUMNS		GSE	SVE	GVE	GVA	SVA	GSA	SSA
CRANIAL NERVE	I							
	II							
	III							
	IV							
	V							
	VI							
	VII							
	VIII							
	IX							
	X							
	XI							
	XII							



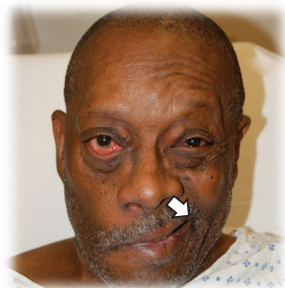
X nerve lesion



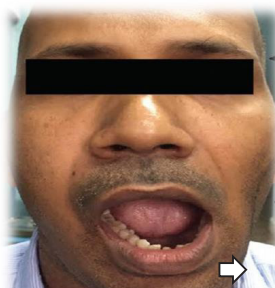XII nerve lesion



VII nerve lesion

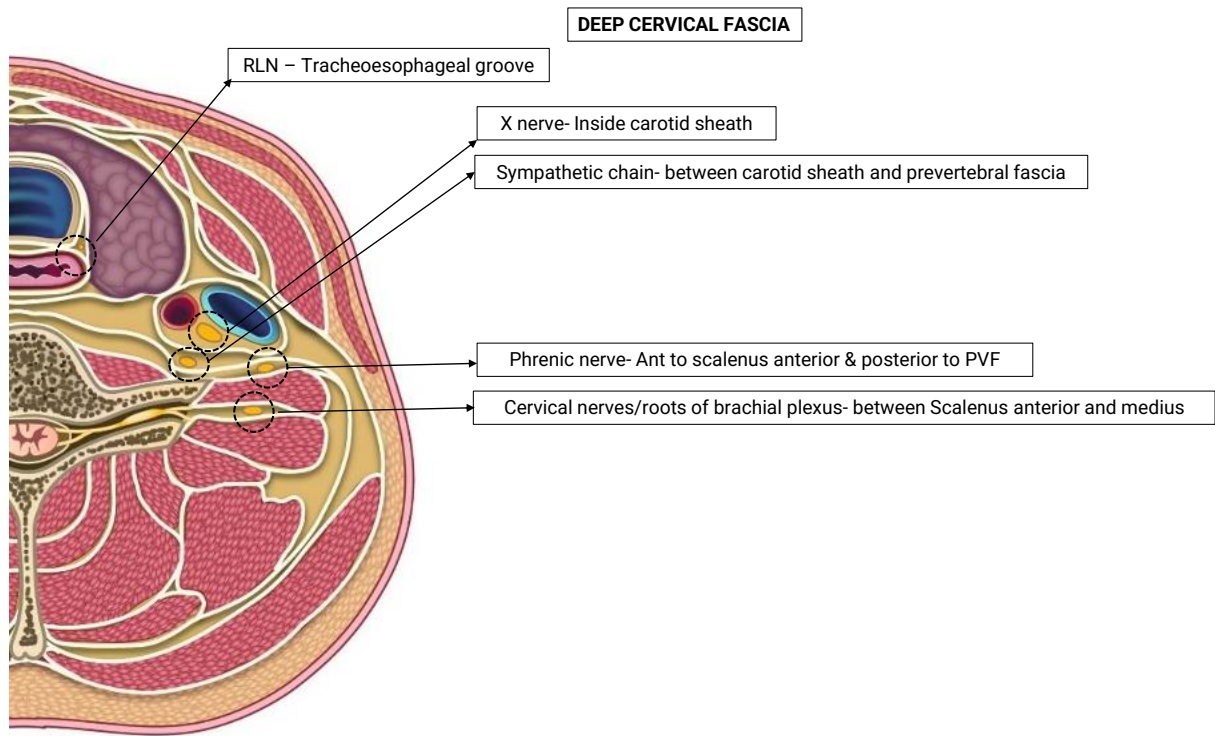
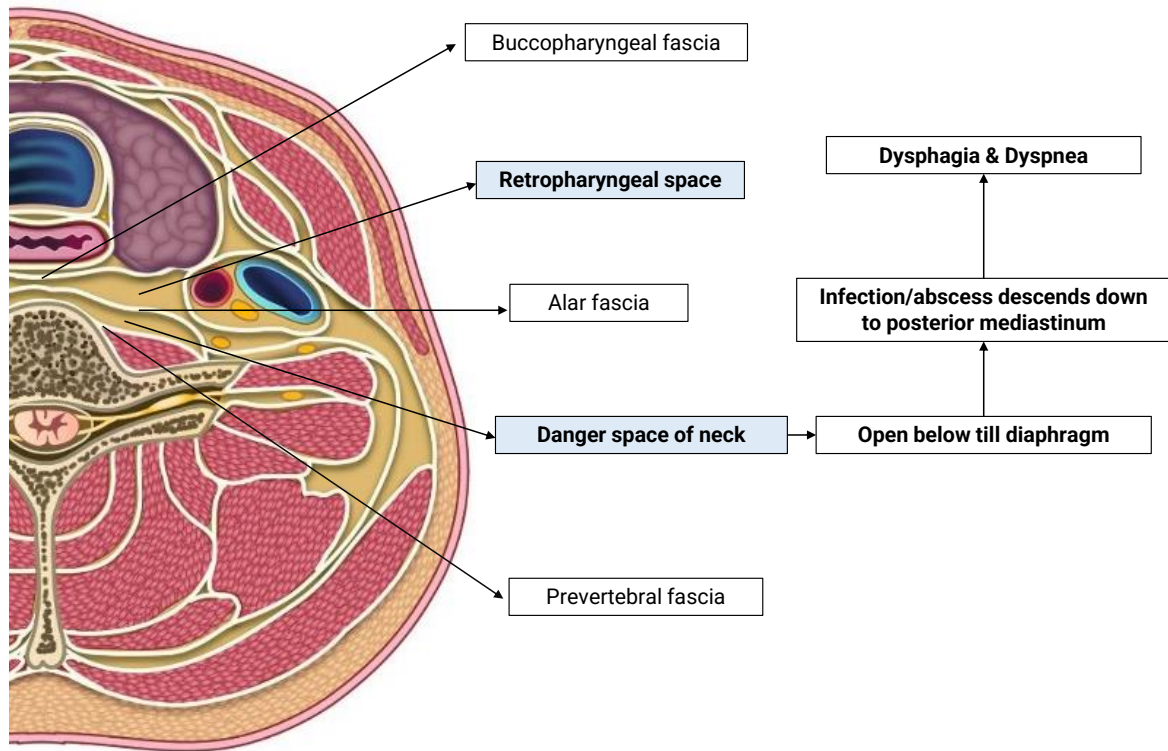


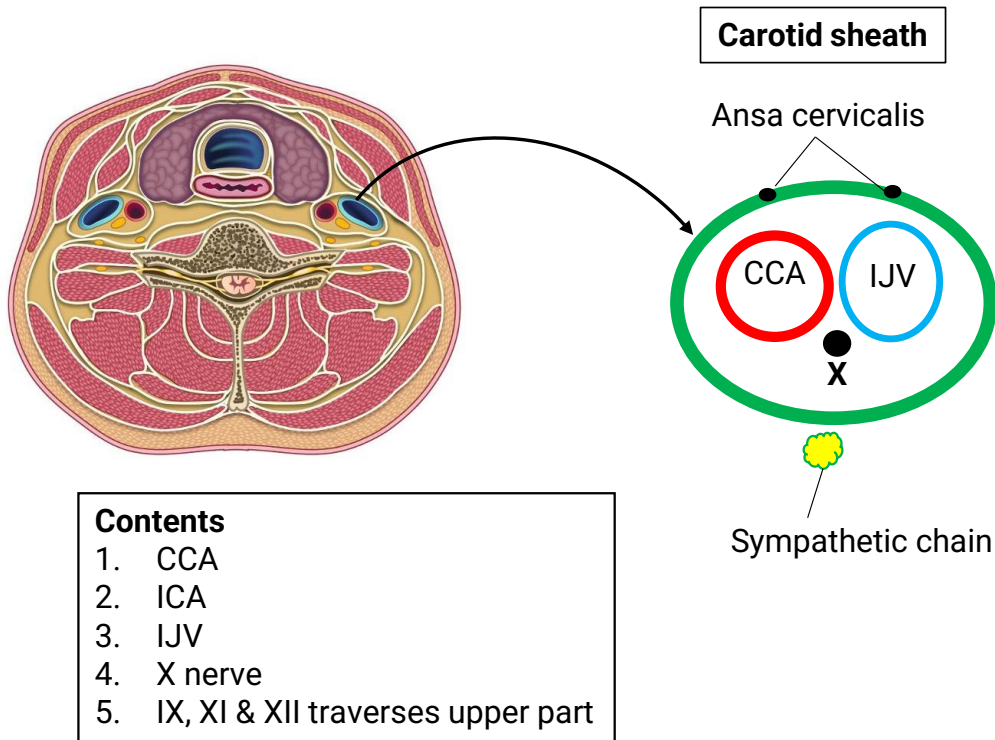
V nerve lesion





### DEEP FASCIA OF THE NECK



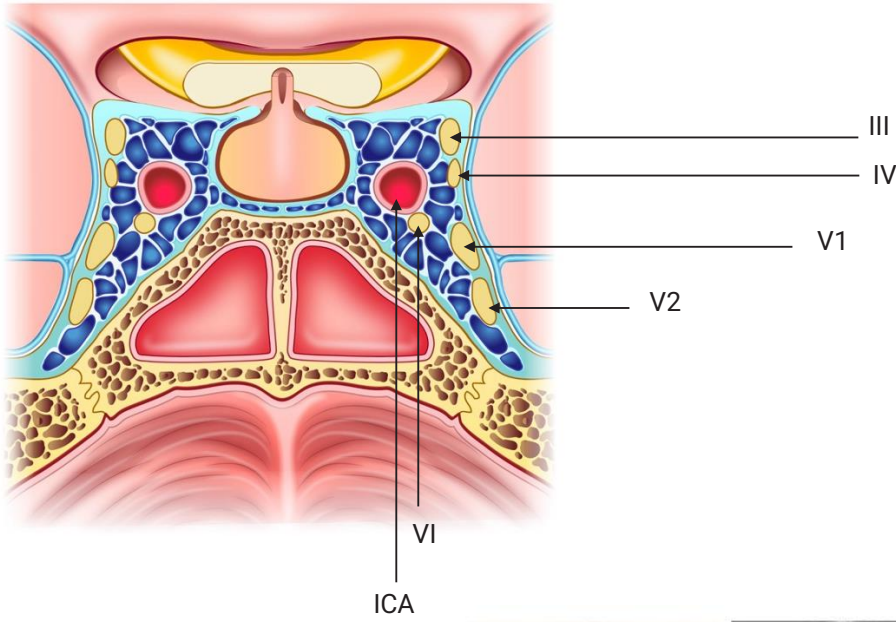


**Investing layer of Deep cervical fascia : Rule of 2**

- ✓ 2 Muscles : SCM & Trapezius
- ✓ 2 Glands : Parotid & Submandibular
- ✓ 2 Ligaments : Stylomandibular & Sphenomandibular
- ✓ 2 Spaces : Suprasternal & Supraclavicular
- ✓ 2 Pulleys : Digastric and omohyoid

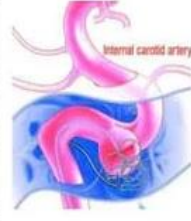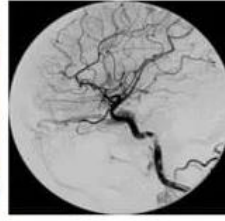
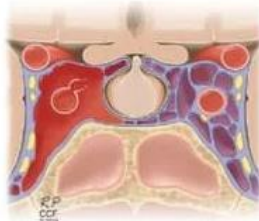


**CAVERNOUS SINUS RELATIONS**



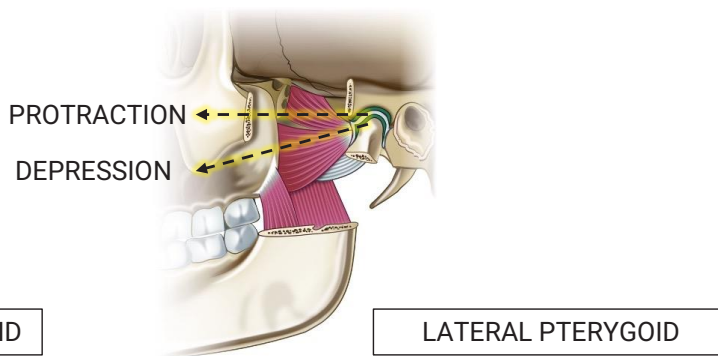
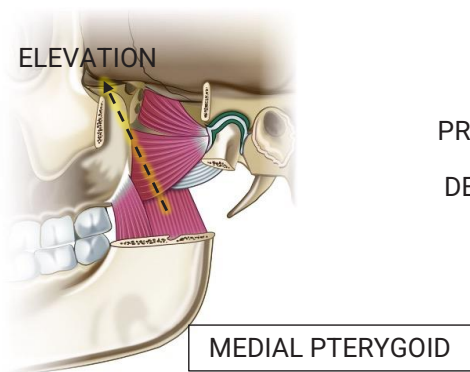
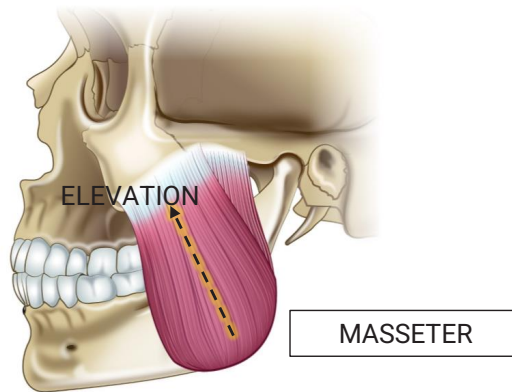
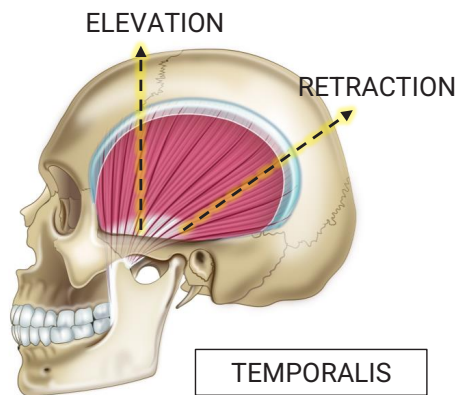
Carotidocavernous fistula

Pulsatile proptosis

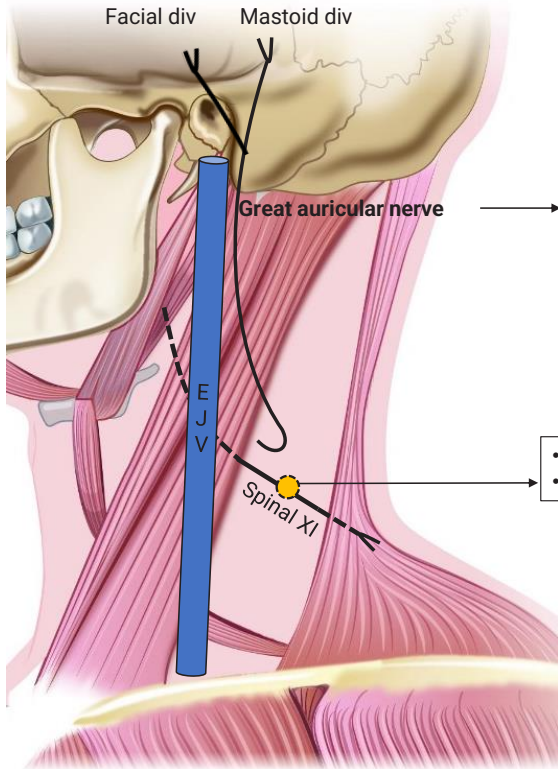




**MUSCLES OF MASTICATION**



**POSTERIOR TRIANGLE OF NECK**



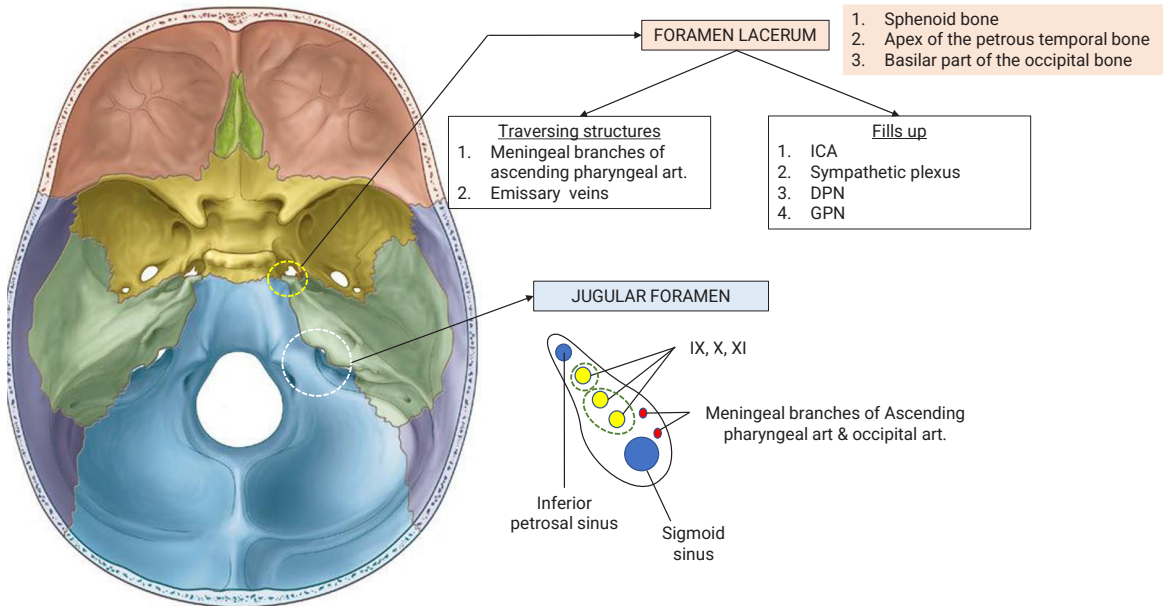
- Root value: C2-C3
- Runs with EJV
- Supplies lobule of ear
- Supplies skin at angle of mandible & parotid region
- In Frey's syndrome- ATN communicates to GAN
- Injured in parotid Sx- sensory loss in shaving area

- Runs between investing layer and prevertebral layer
- Injury in posterior triangle

(SCM - Spared)

Trapezius- affected

- Difficulty in shrugging of shoulder
- Difficulty in retraction of scapula
- Difficulty in overhead abduction



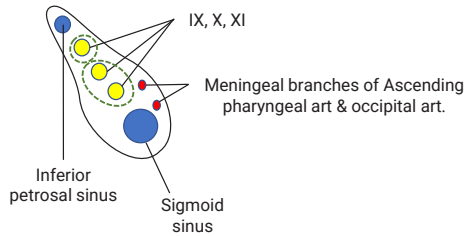
**FORAMEN LACERUM**

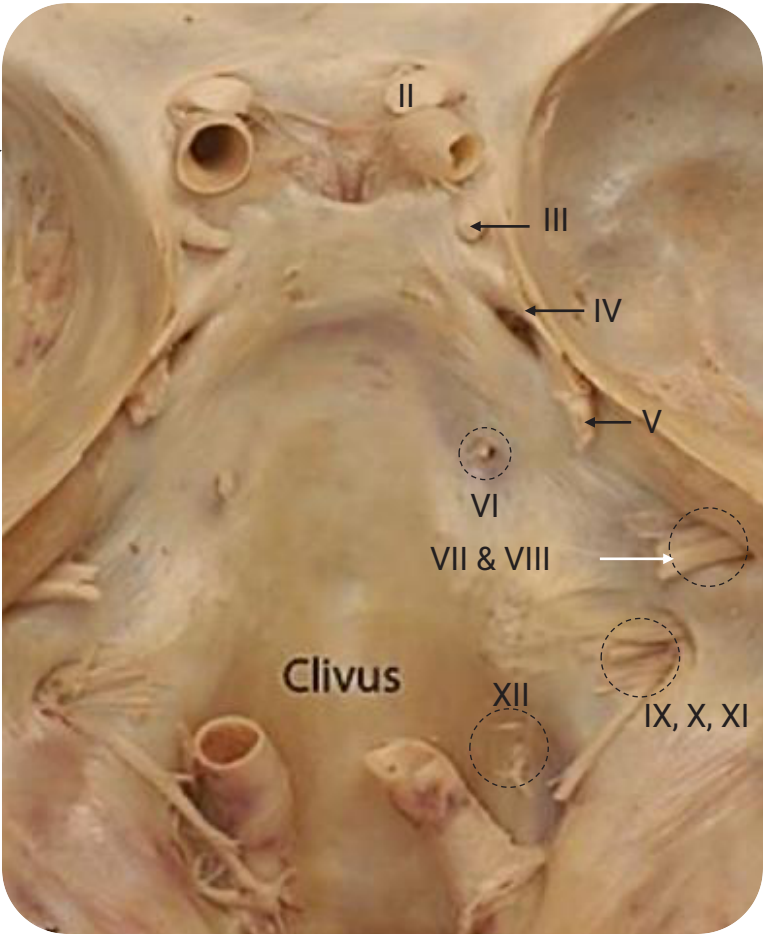
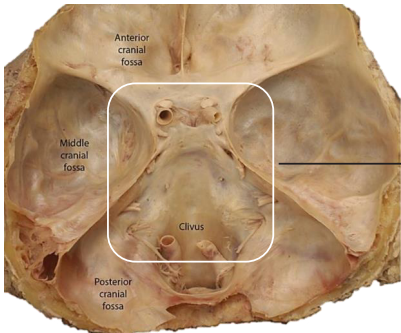
1. Sphenoid bone
2. Apex of the petrous temporal bone
3. Basilar part of the occipital bone

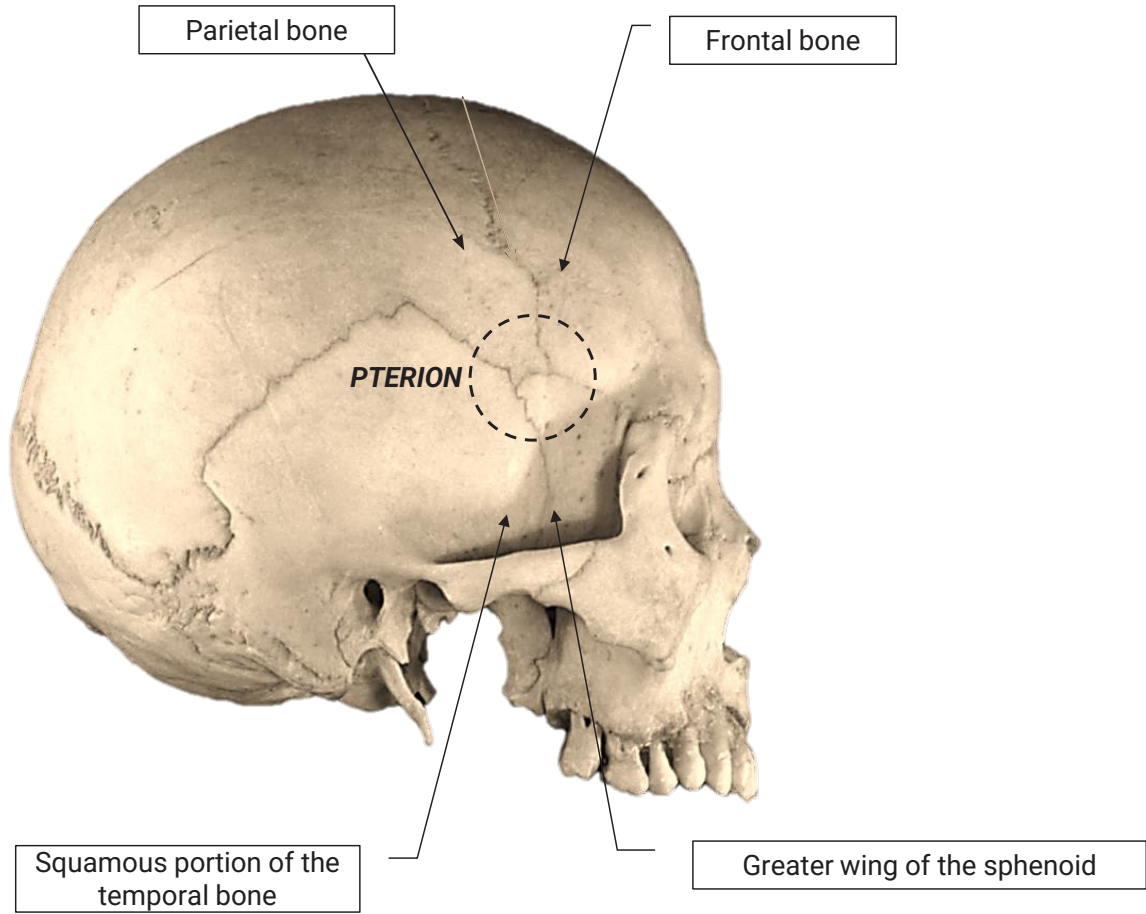
- Traversing structures**
1. Meningeal branches of ascending pharyngeal art.
  2. Emissary veins

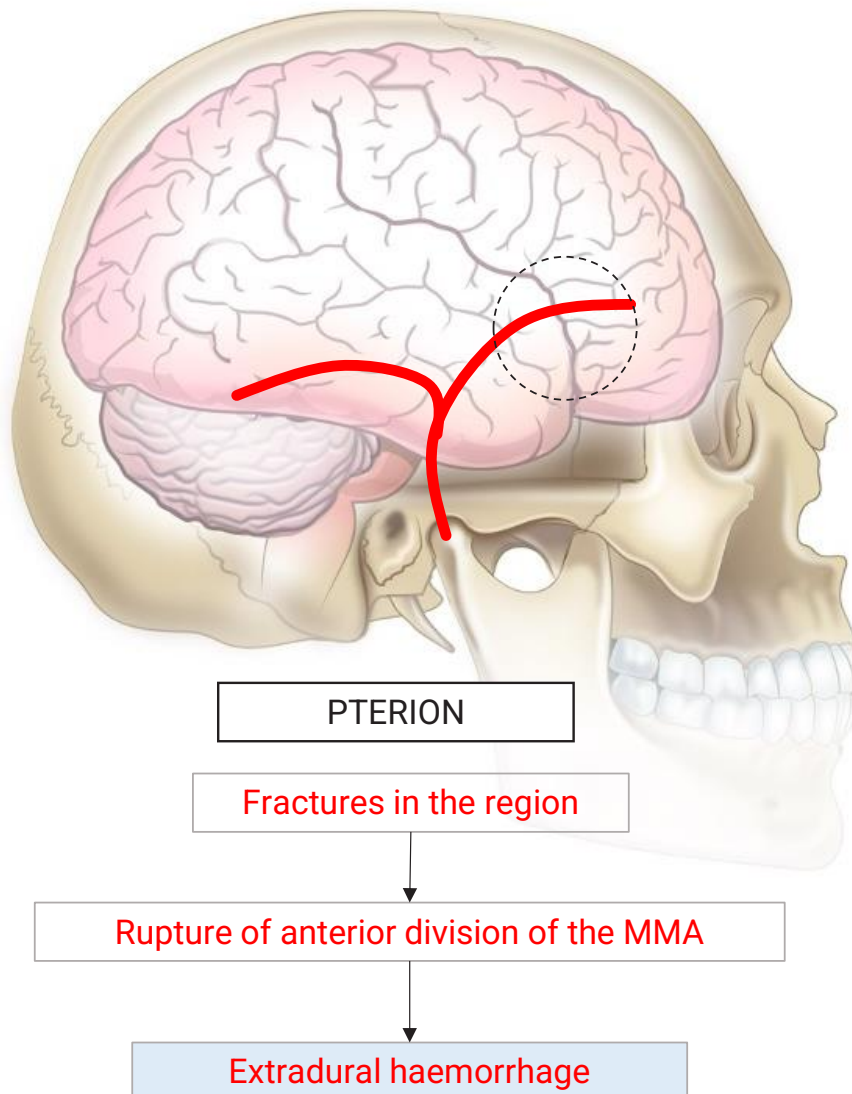
- Fills up**
1. ICA
  2. Sympathetic plexus
  3. DPN
  4. GPN

**JUGULAR FORAMEN**

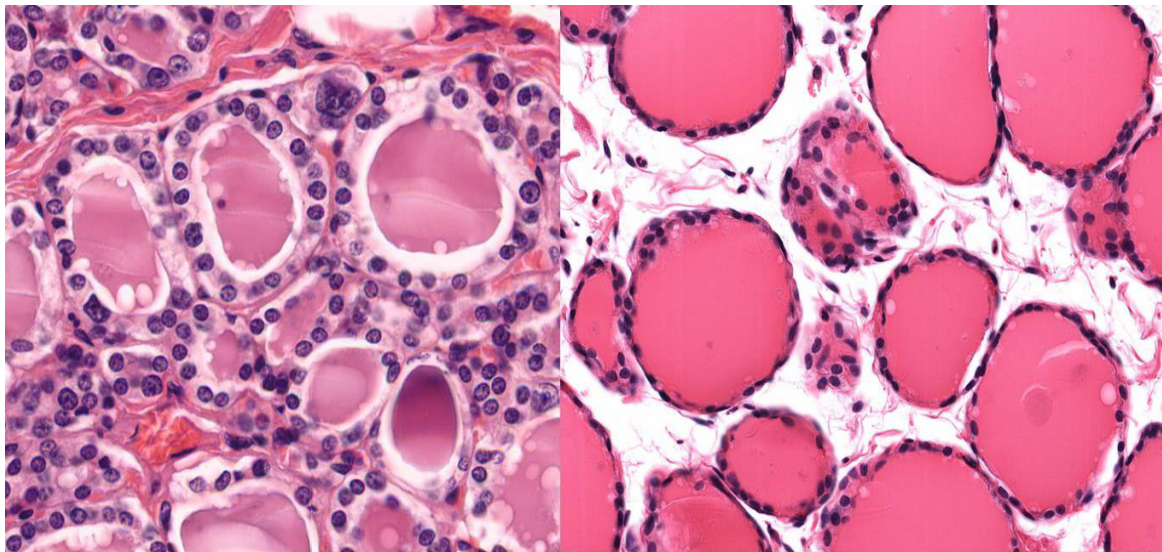
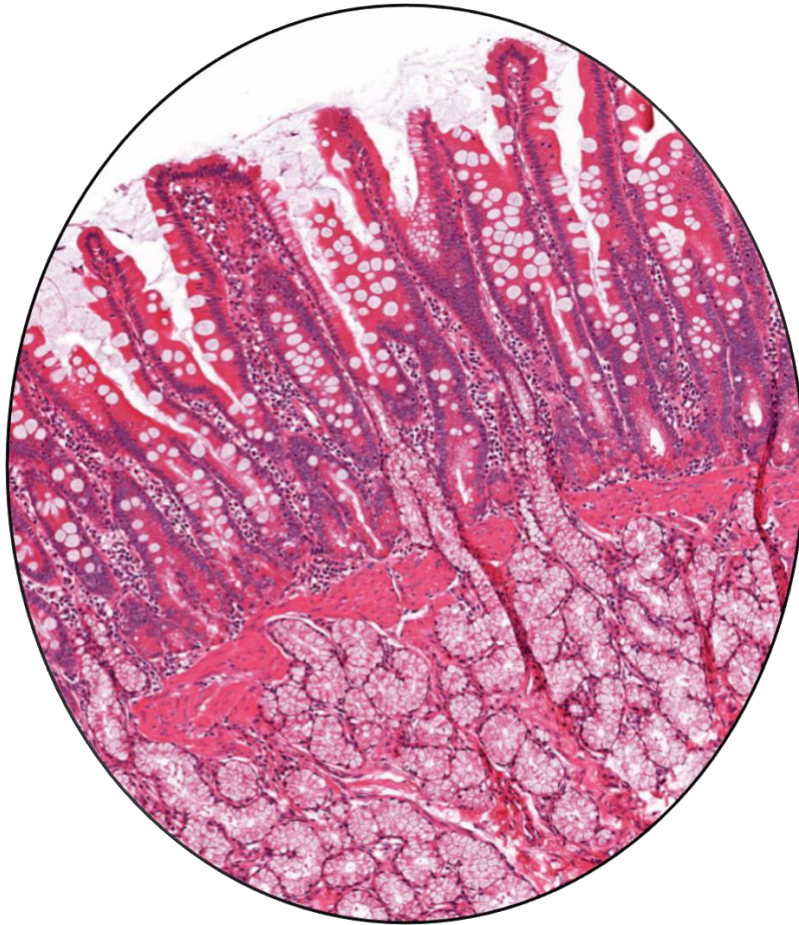


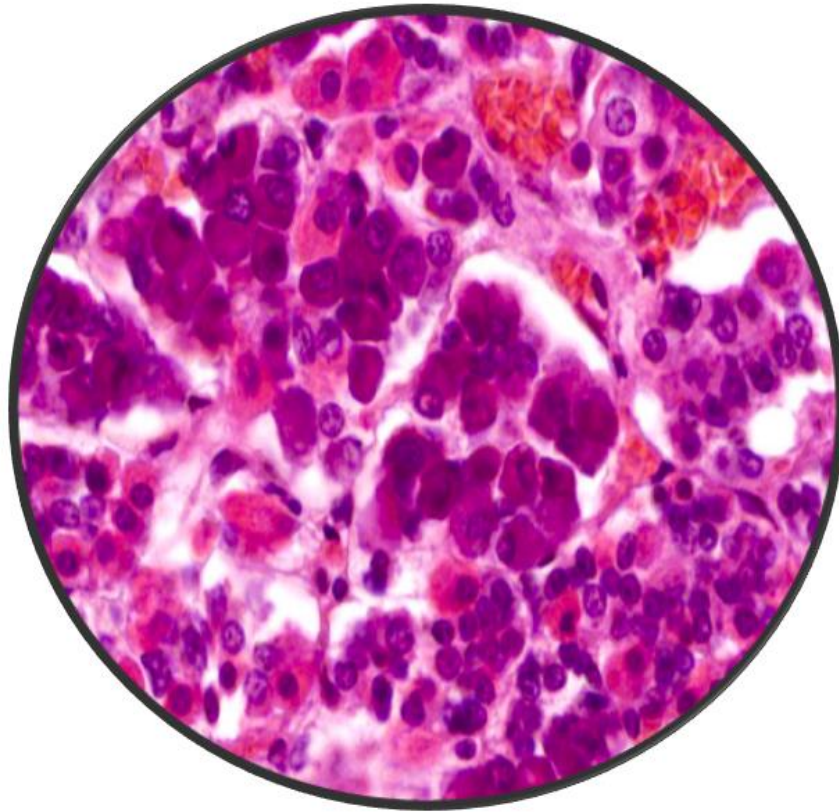




**Relations :**

- Superficial temporal vessels
- Anterior division of the middle meningeal vessels
- Middle cerebral vessels
- Sylvian fissure
- Insula
- Broca's motor speech area (on the left)
- Lesser wing of the sphenoid bone












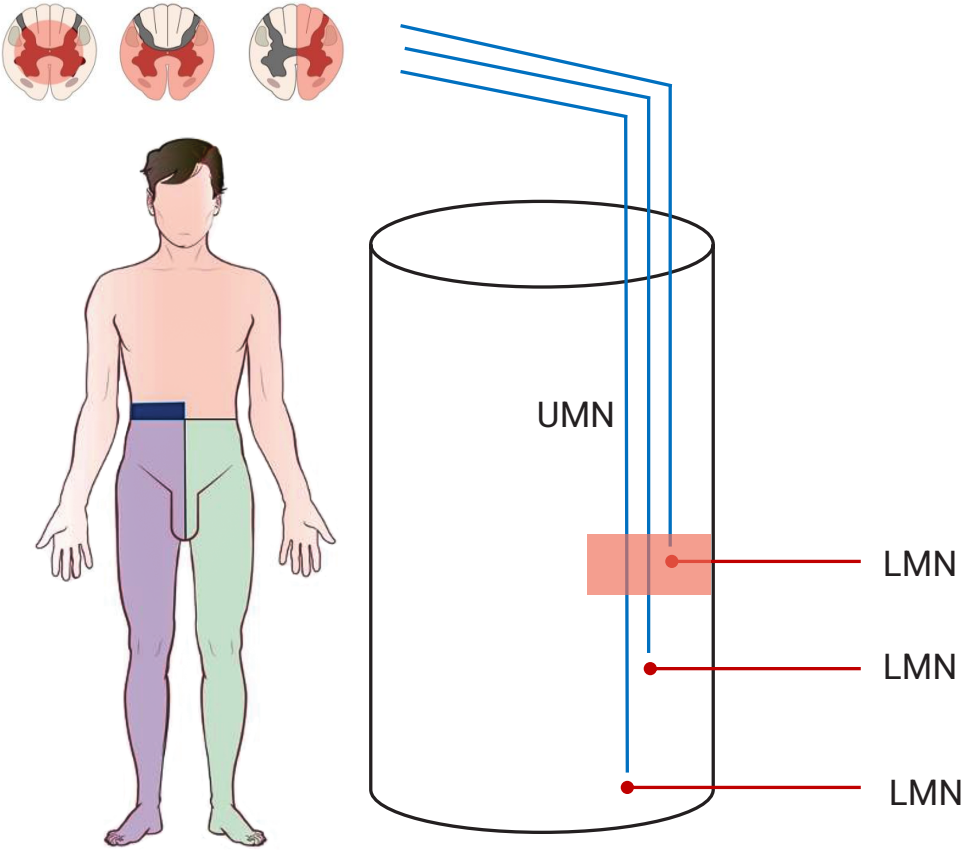
## NOTES



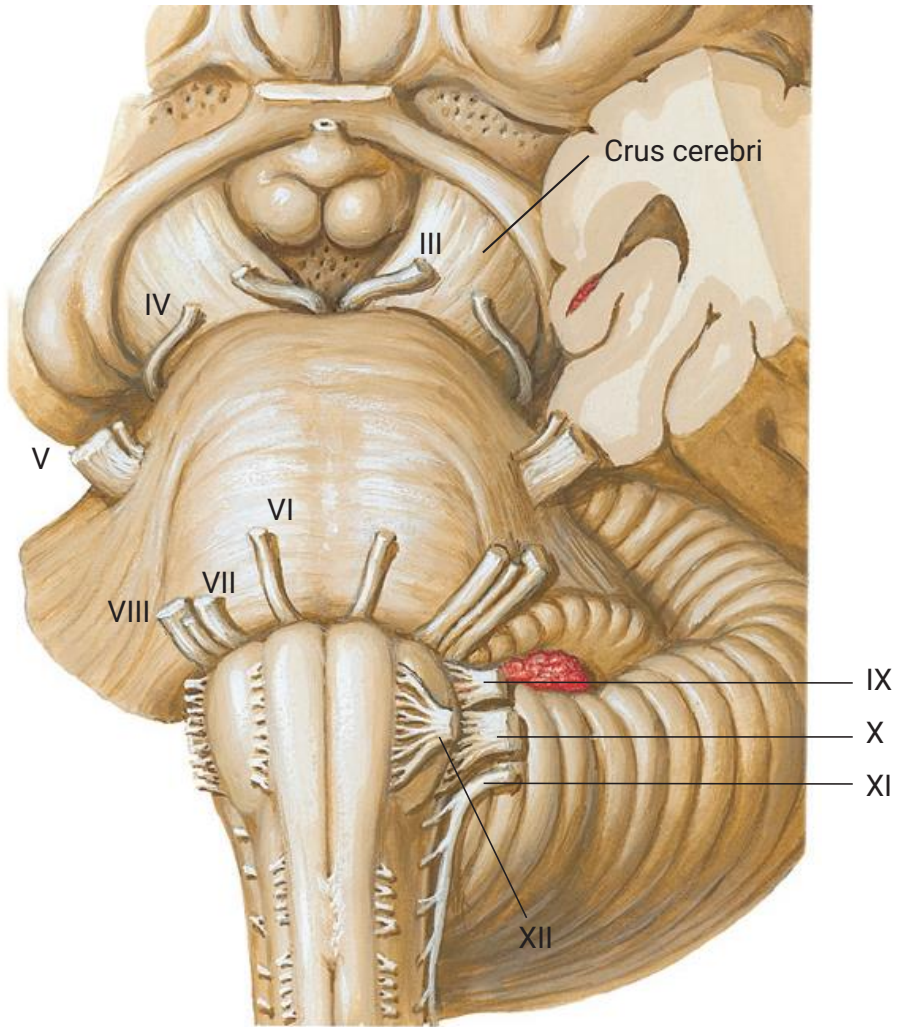
# NEUROANATOMY

## BROWN SEQUARD SYNDROME

-  Ipsilateral loss of all sensory modalities at the level of the lesion
-  Ipsilateral flacid paralysis at the level of the lesion
-  Ipsilateral spastic paraparesis below the lesion
-  Ipsilateral loss of vibration and position sense below the lesion
-  Contralateral loss of pain and temperature below the lesion



VENTRAL ASPECT OF BRAINSTEM





**DORSAL ASPECT OF BRAINSTEM- FLOOR OF IV VENTRICLE**

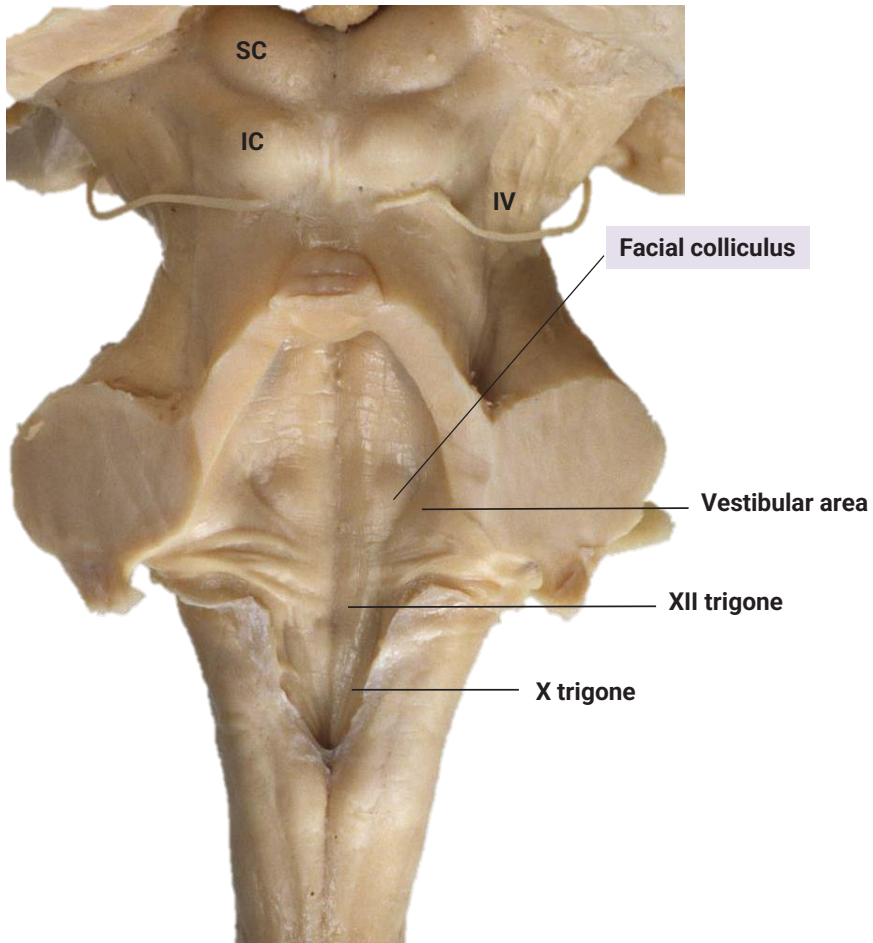
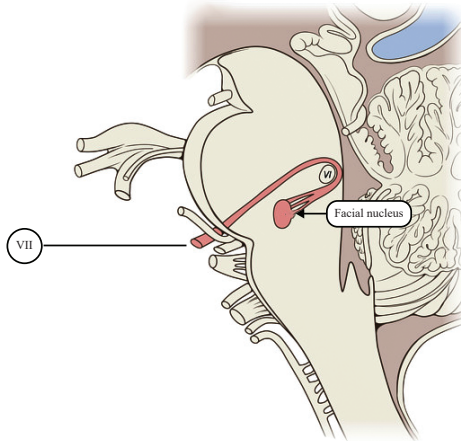
Cranial nerve nuclei in the floor of IV ventricle  
VI, VIII, X & XII

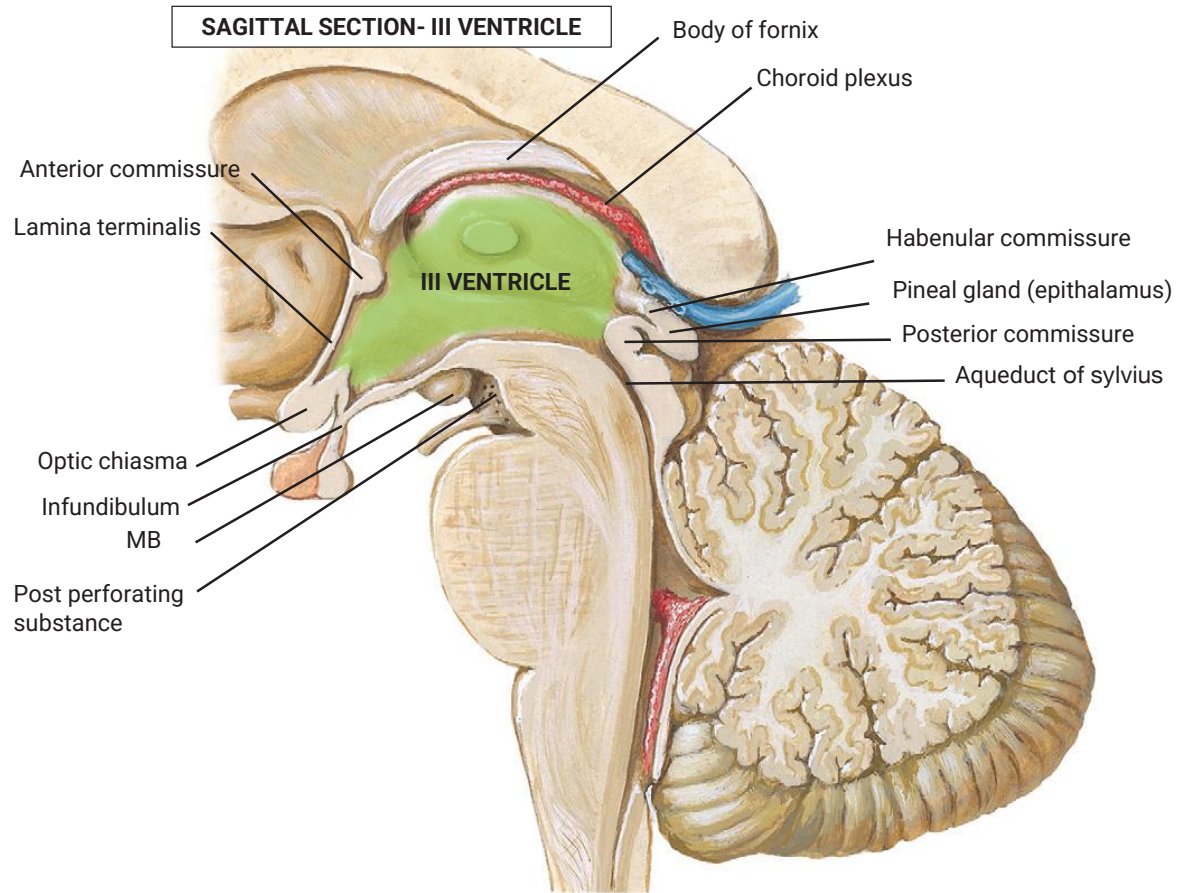
Abducent nucleus surrounded by LMN  
of VII nerve

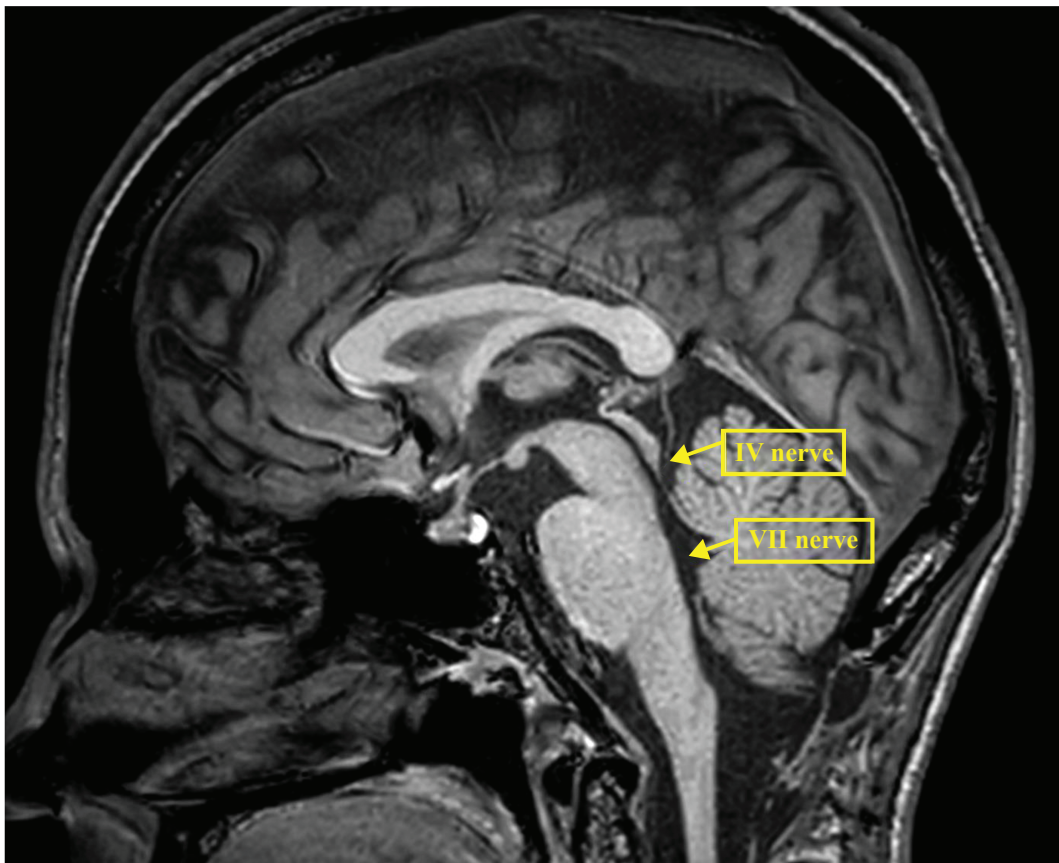
*Injury*

LMNL of VII nerve

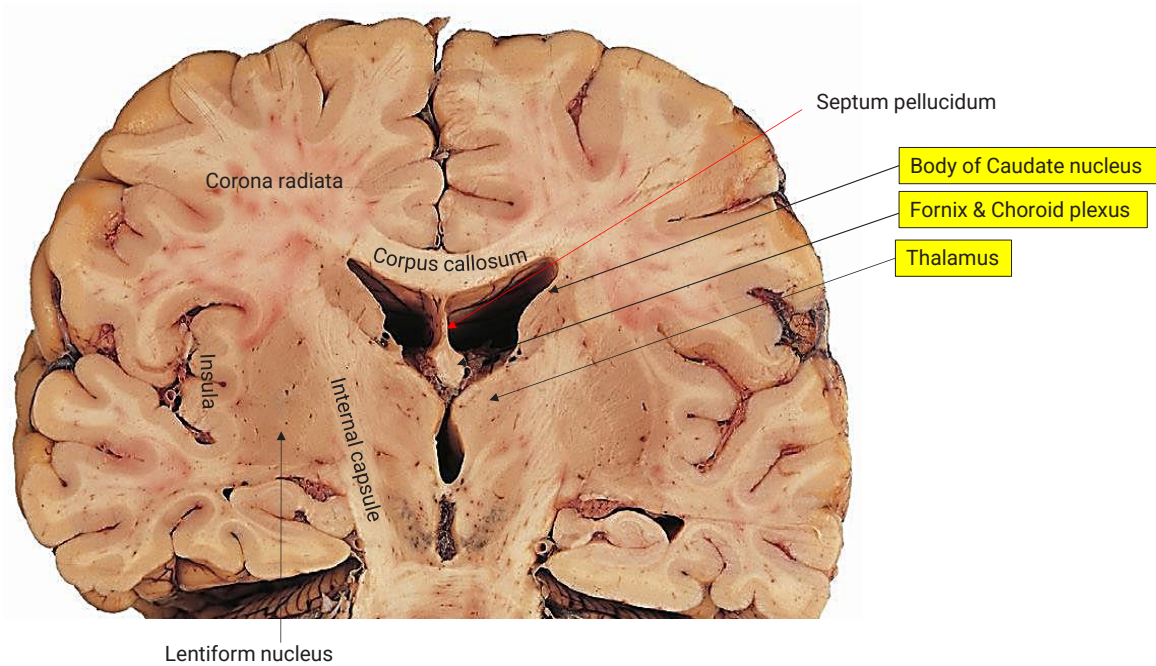
I/L facial paralysis

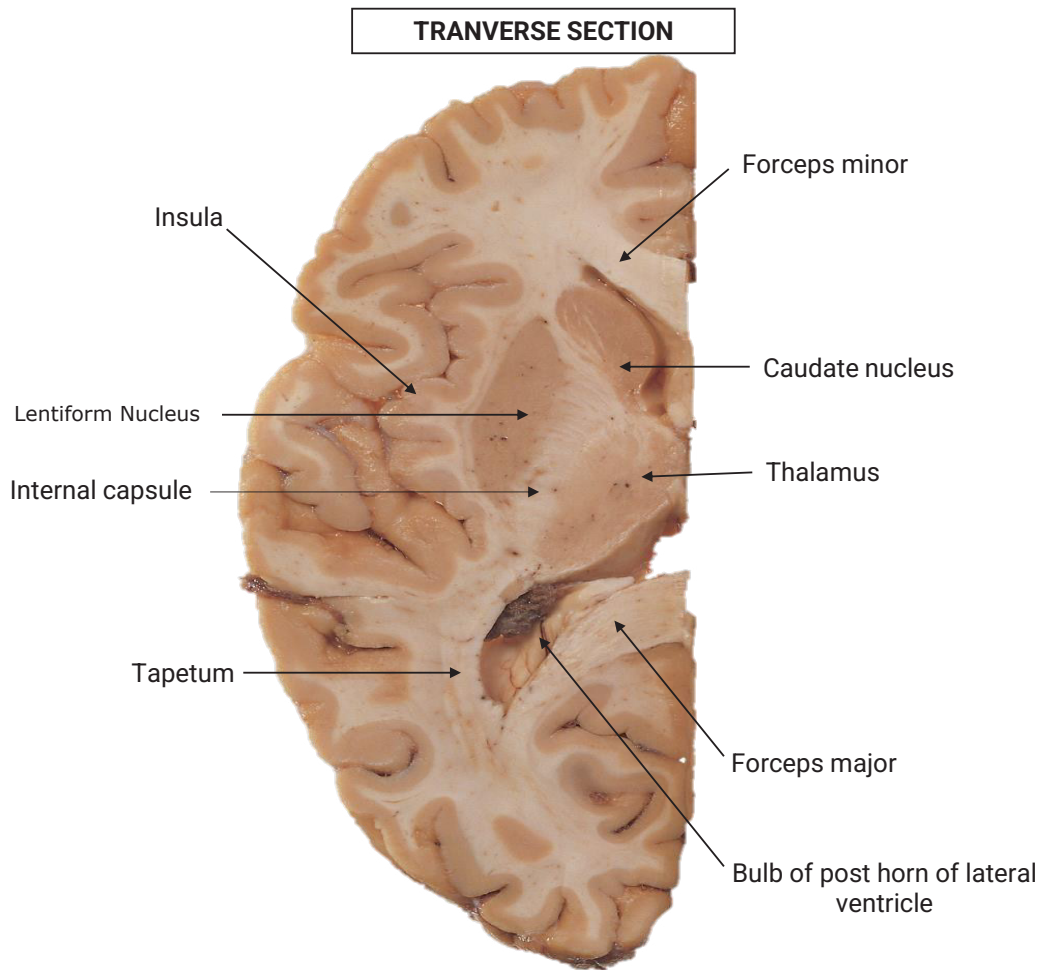
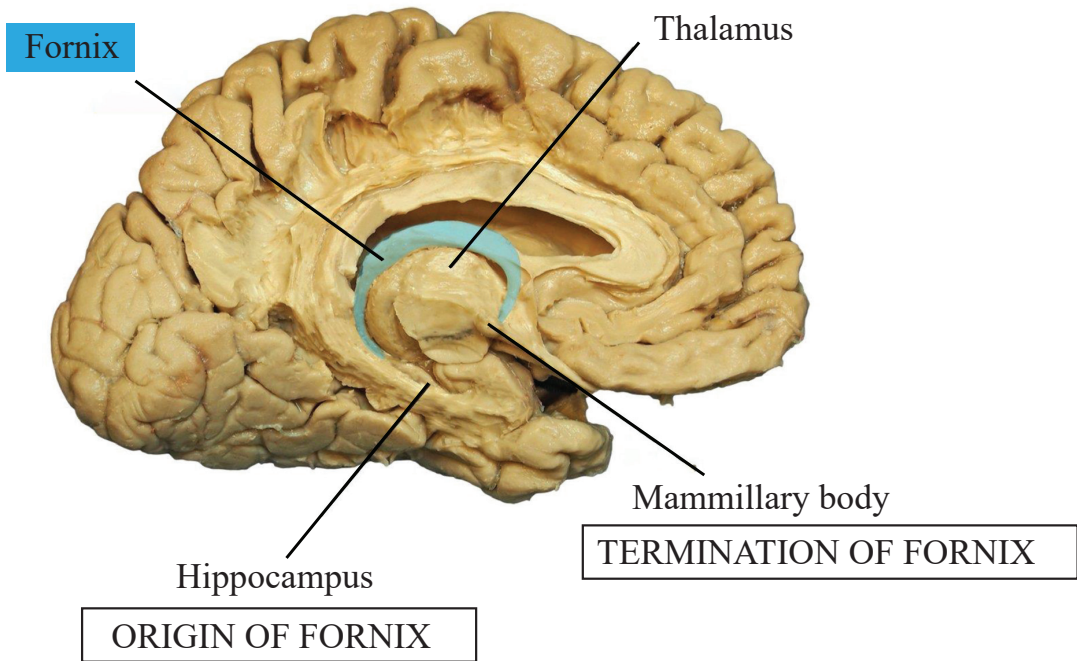


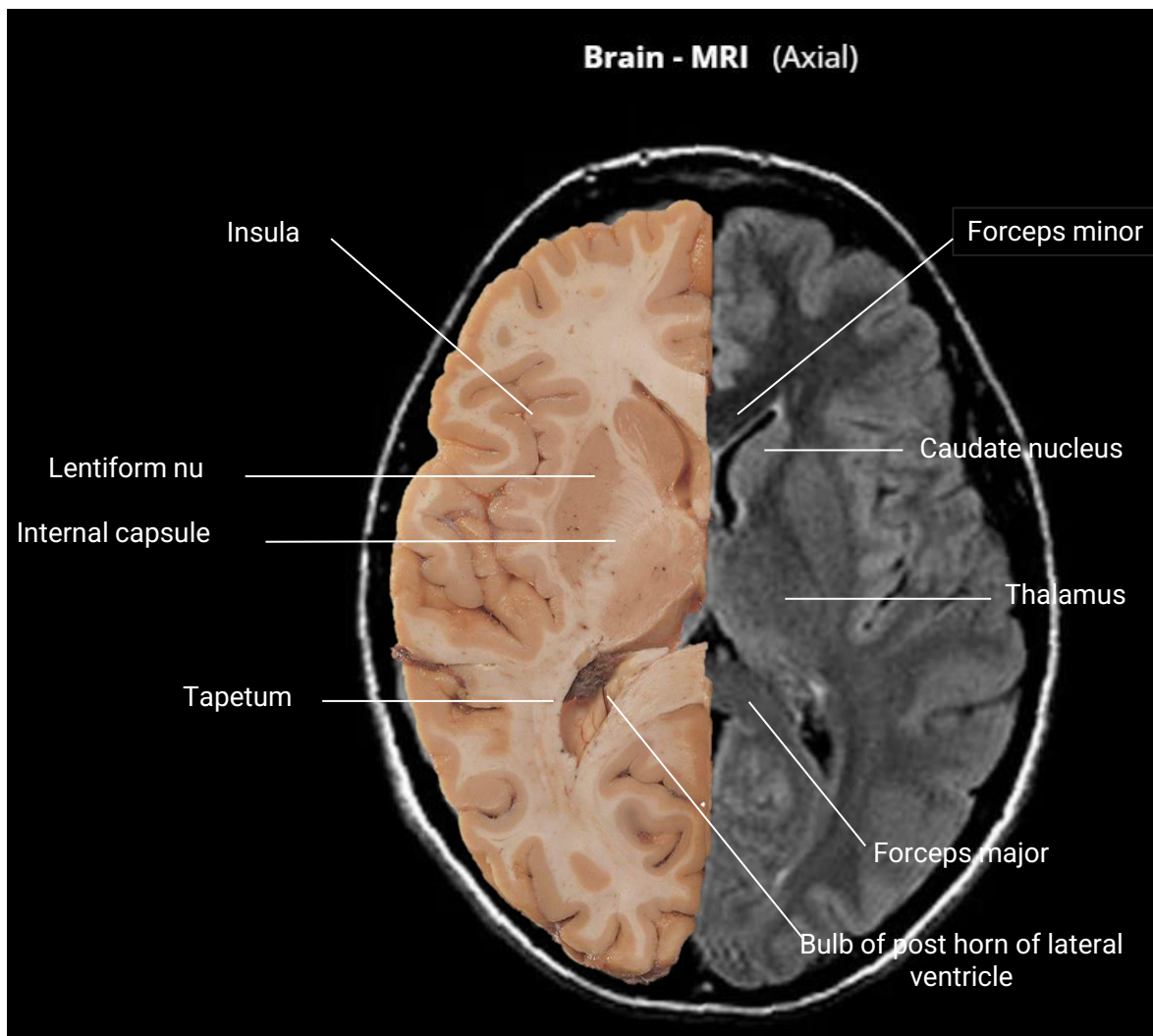




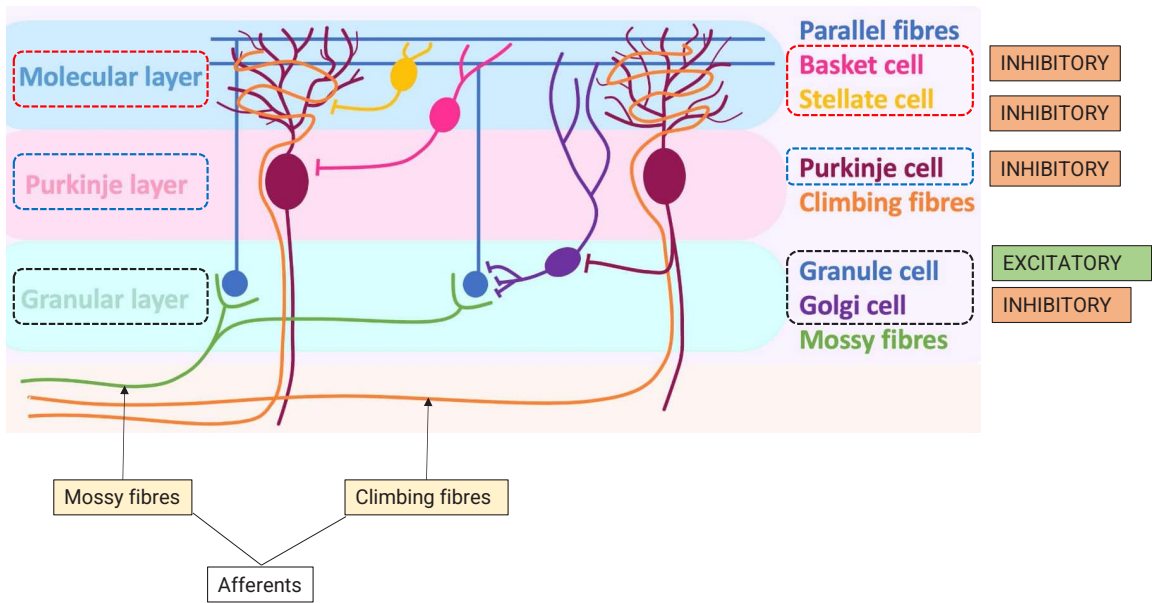
CORONAL SECTION- LATERAL VENTRICLE



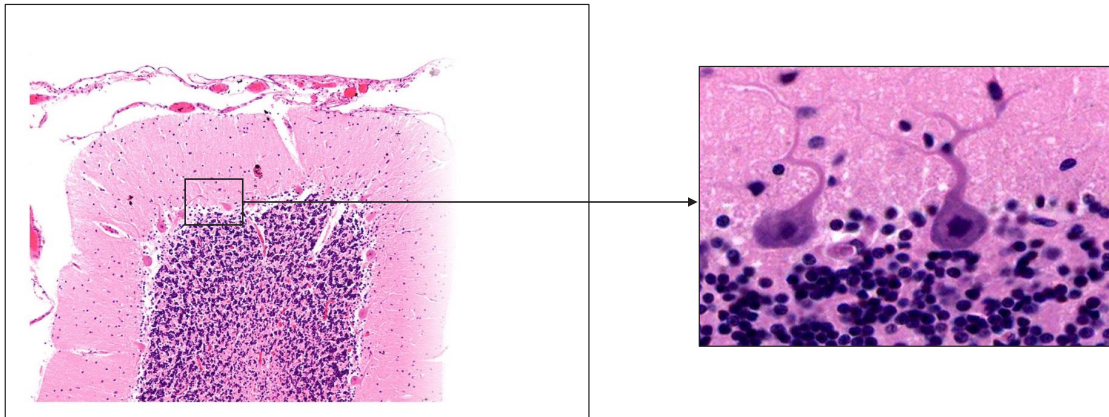




**CEREBELLAR CORTEX**



- Olivocerebellar & Para-olivocerebellar tract are CLIMBING FIBRES
- Rest all are Mossy

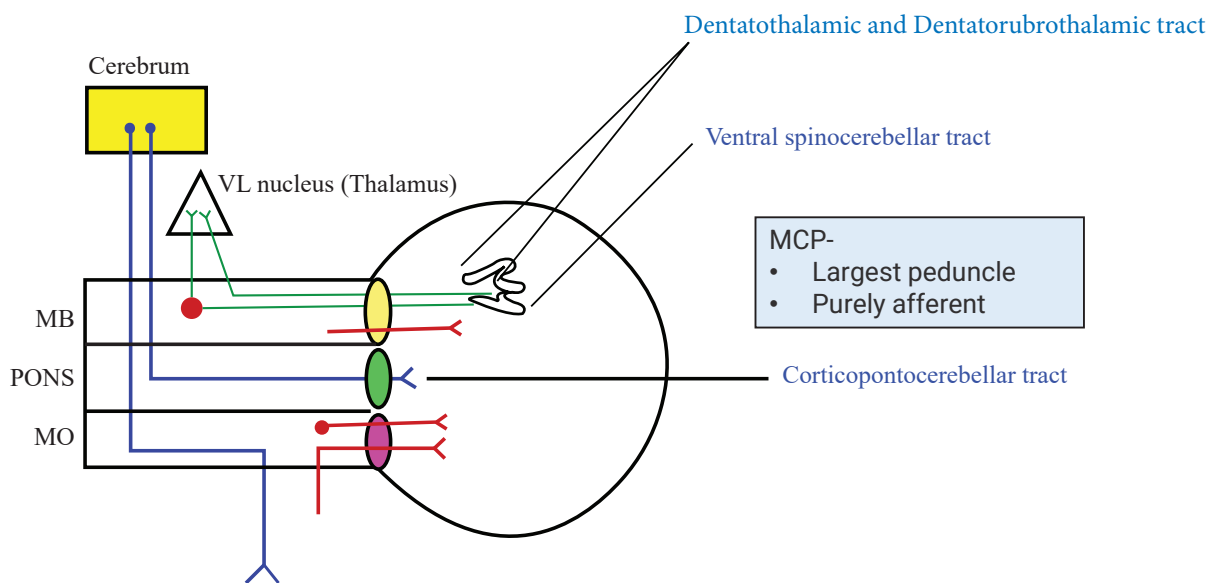


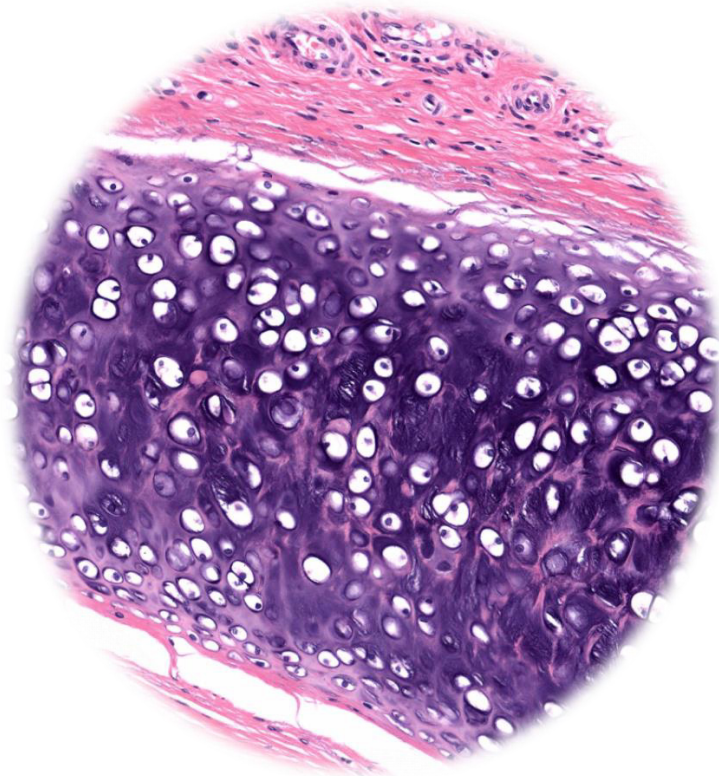
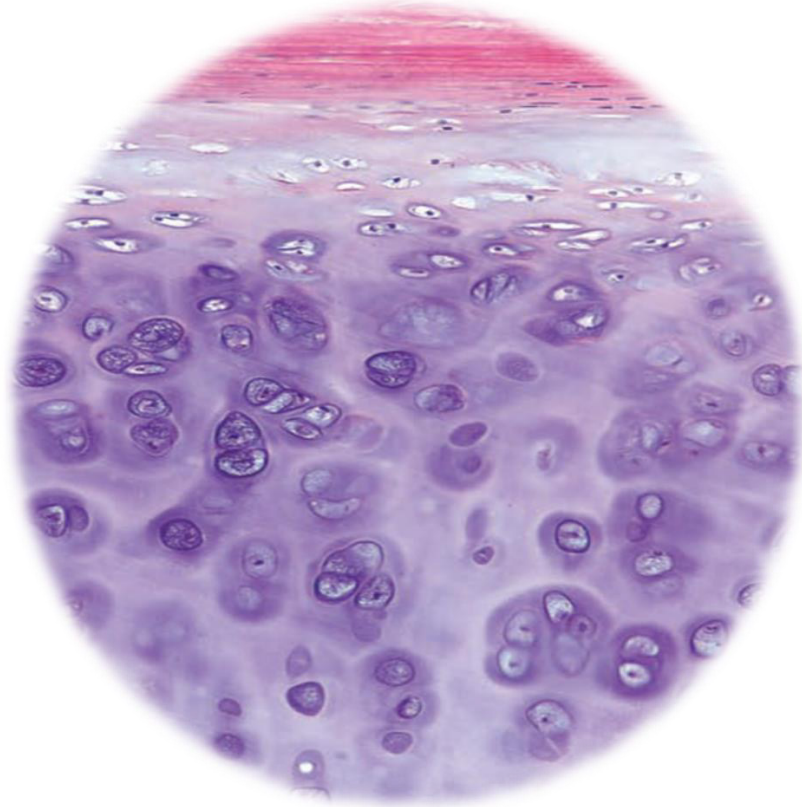
PURKINJE CELLS

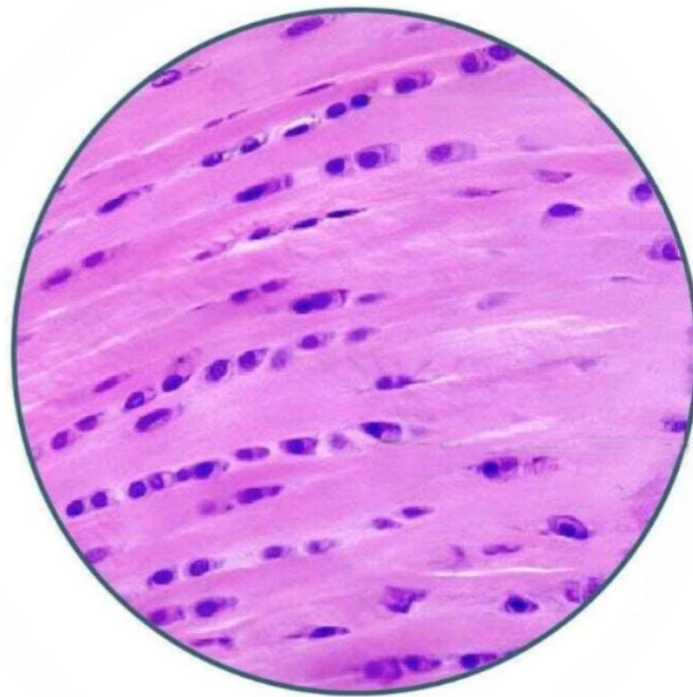ONLY EFFERENTS FROM  
CORTEX

EFFERENTS FROM  
CEREBELLUM

DEEP CEREBELLAR NUCLEI  
(mainly Dentate nucleus)





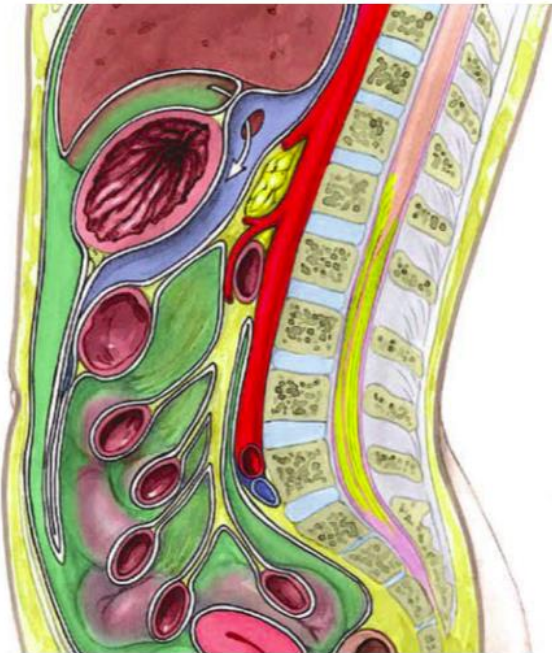
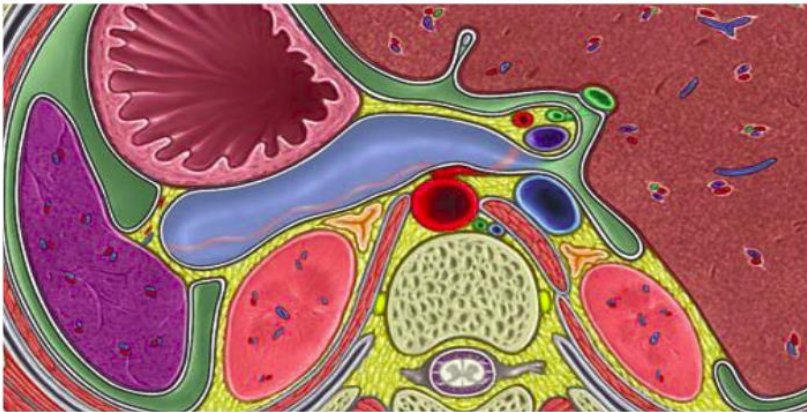




## NOTES



ABDOMEN & PERINEUM

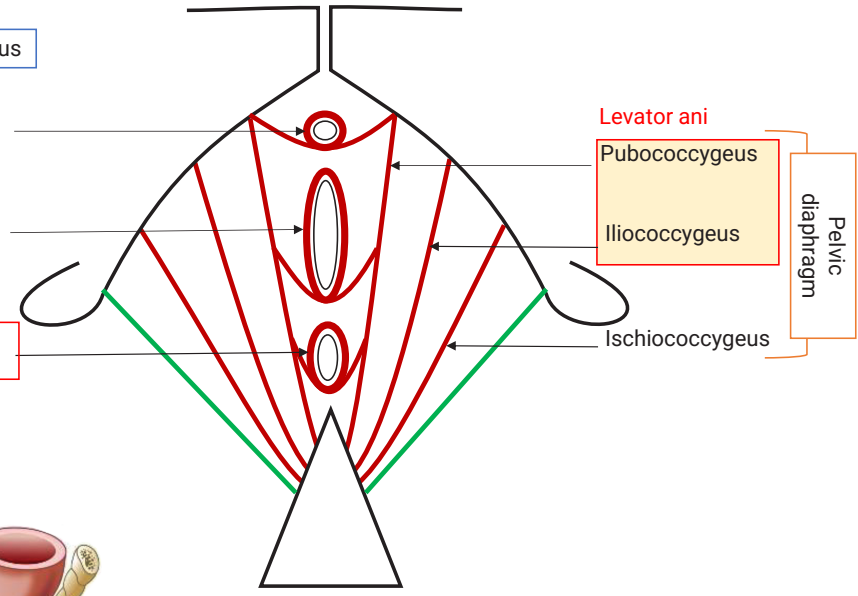
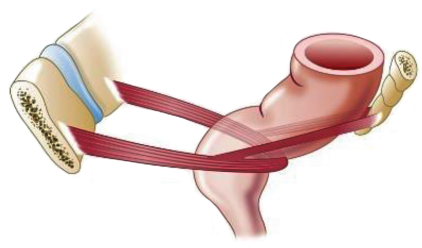


# Pelvic Diaphragm

## Modifications of Pubococcygeus

1. Pubourethralis
2. Pubovaginalis
3. Puborectalis

Muscle of continence



Perineal membrane  
Inferior layer of UGD

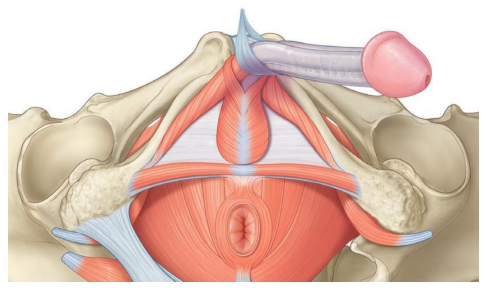
Bulb/ bulbospongiosus

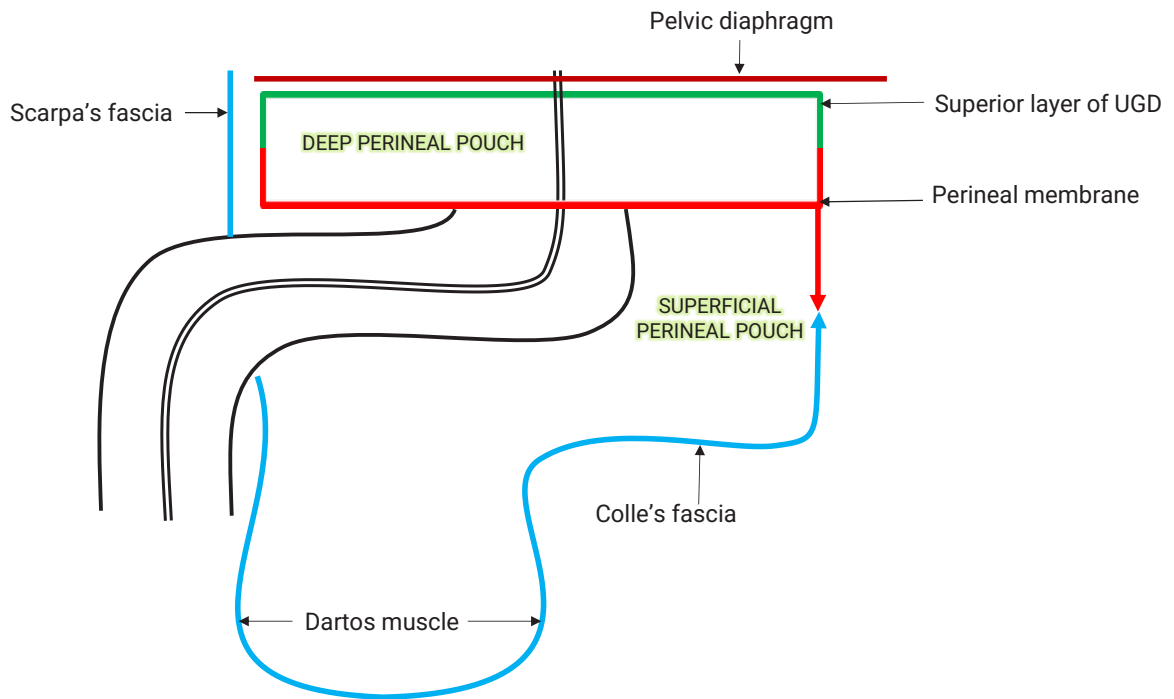
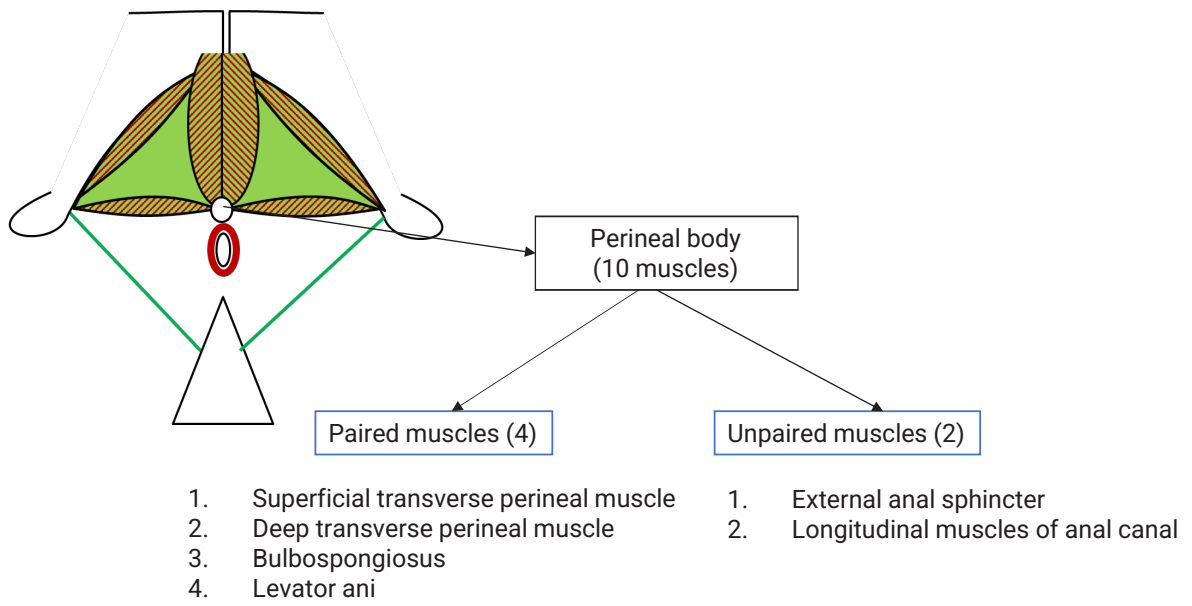
Crus/ Ischiocavernosus

Superficial transverse perineal muscle

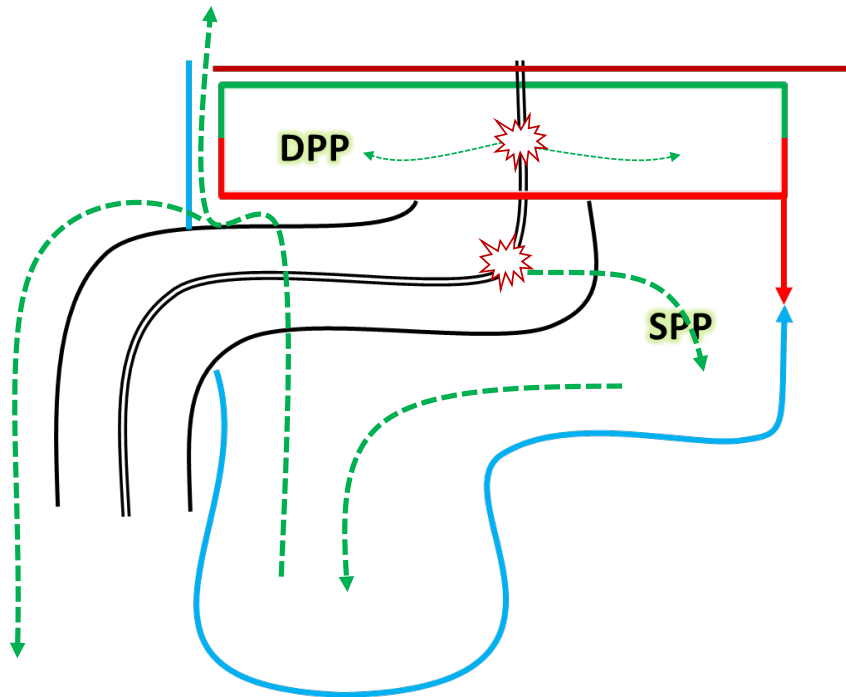
Perineal body

External anal sphincter

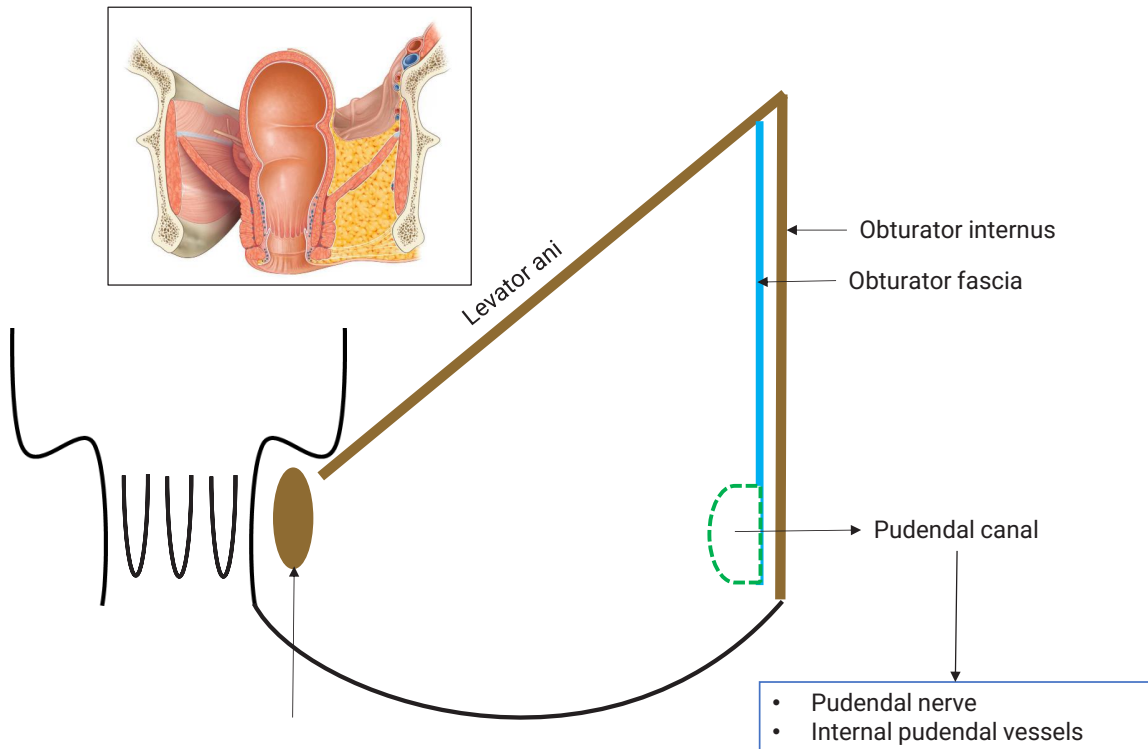




EXTRAVASATION OF URINE



ISCHIORECTAL FOSSA/ ISCHIOANAL FOSSA

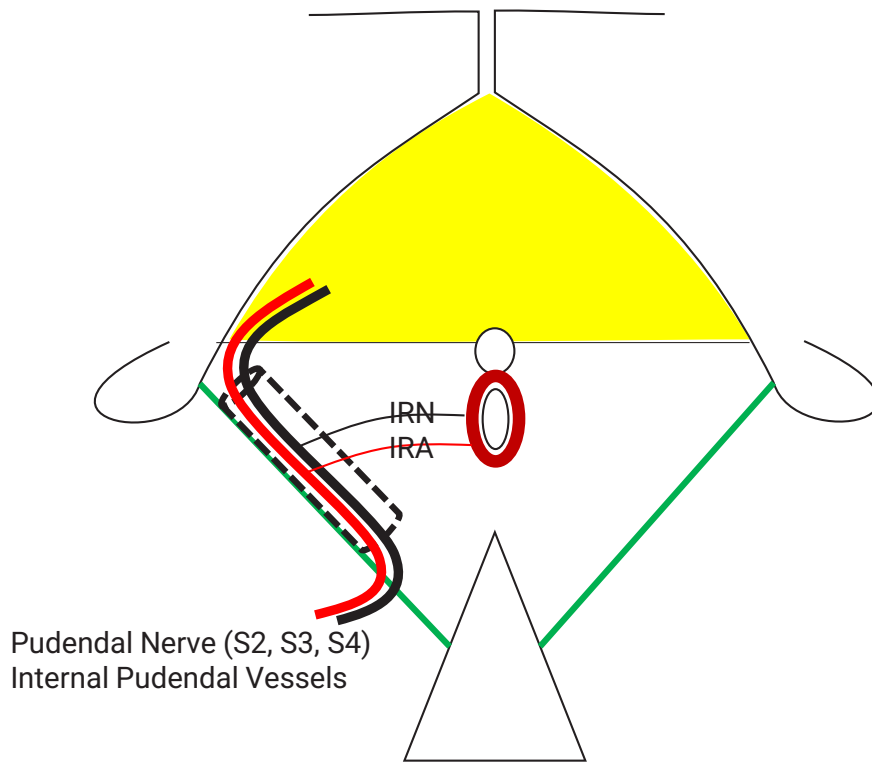


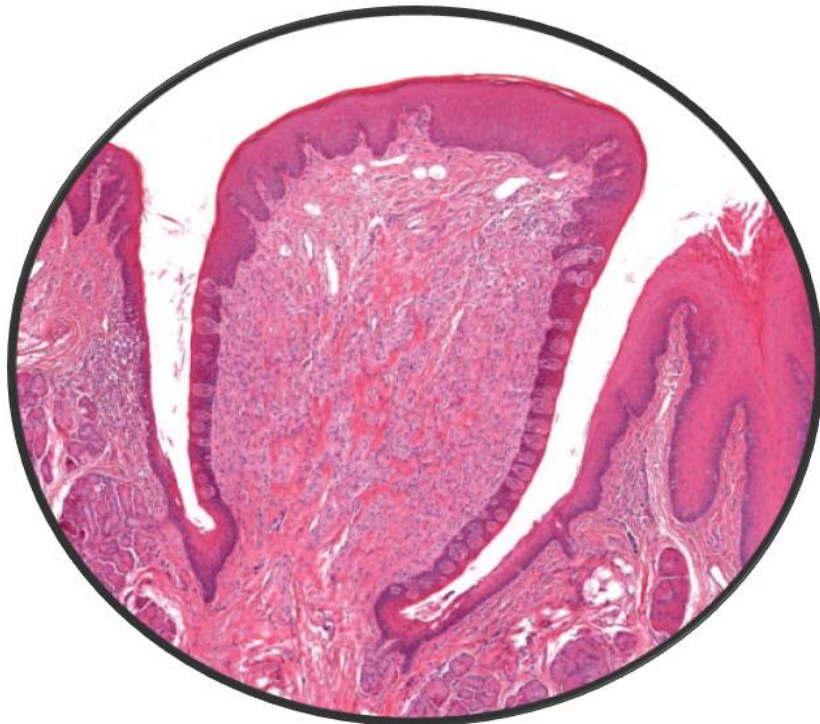
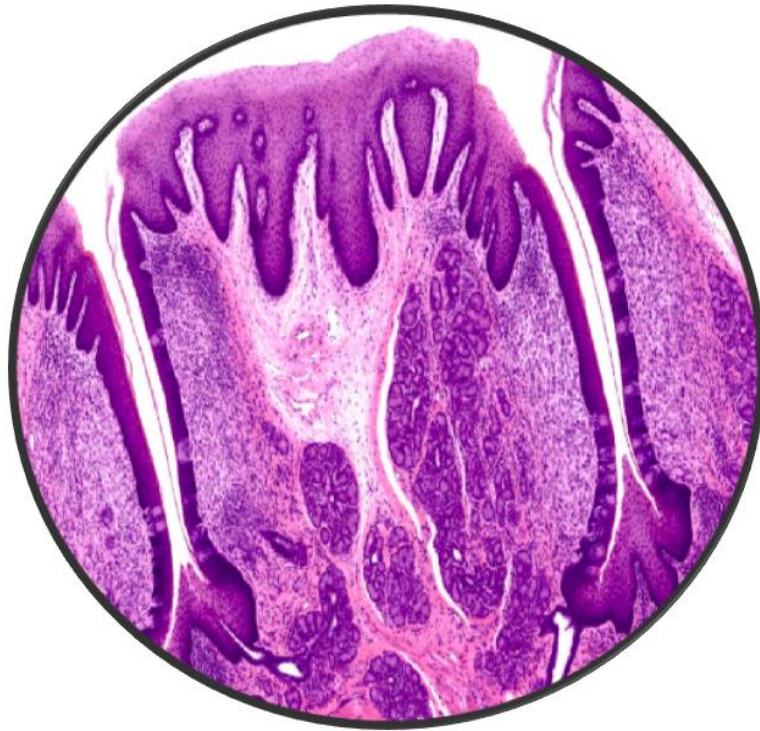

Contents of IRF

1. Fat
2. Pudendal canal and its contents
3. Inferior rectal nerves & vessels

→ Can be injured in drainage of IRF infections







## NOTES



## NOTES