



OneShot 4.0
Microbiology



MICROBIOLOGY

<i>Sl. No.</i>	<i>CHAPTER</i>	<i>Page No.</i>
1.	<i>General Microbiology</i>	43
2.	<i>Immunology</i>	53
3.	<i>Bacteriology</i>	57
4.	<i>Mycology</i>	65
5.	<i>Virology</i>	73
6.	<i>Parasitology</i>	79

“

Where there
is a will, there
are several
ways.

- Dr. Abdul Naseer

”

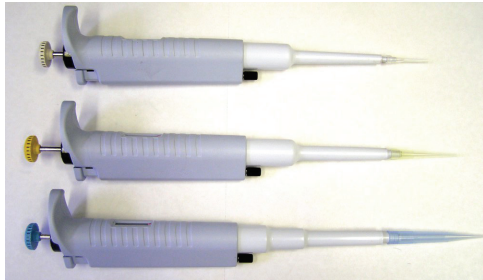




GENERAL MICROBIOLOGY

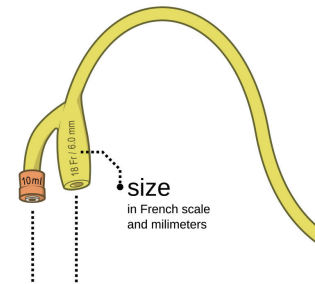
Sterilization

Pipette Tips



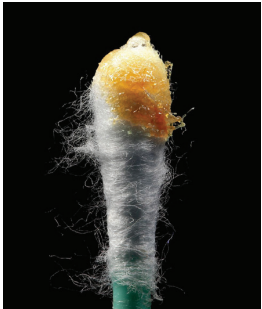
Plastic

Foley's Catheter



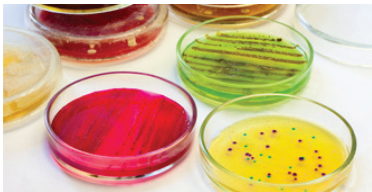Rubber

Cotton swab



Cotton

Culture Media

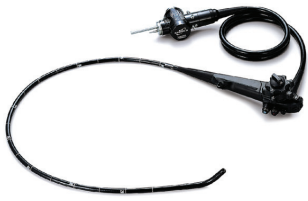

- Most → CM → _____
- Serum / Egg CM → _____
 - ↓ LSS
 - ↓ LJ



Disinfection

Endoscope



All scopes →

except

Laproscope and Arthroscope } →

Blood Spill

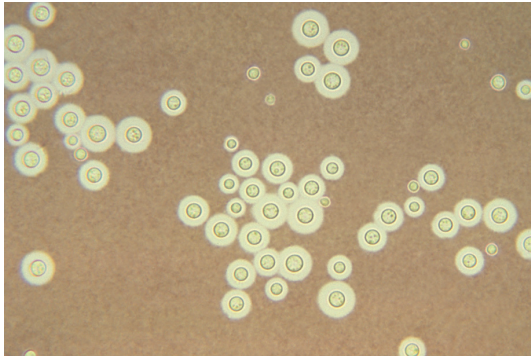


Hands





Morphology → Capsule



Polysaccharide Capsule

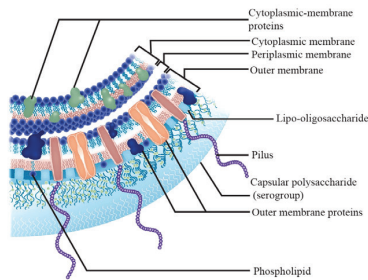
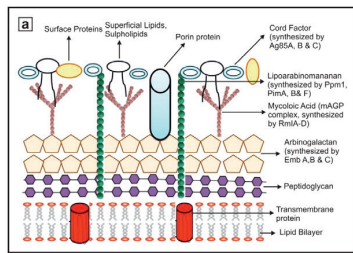
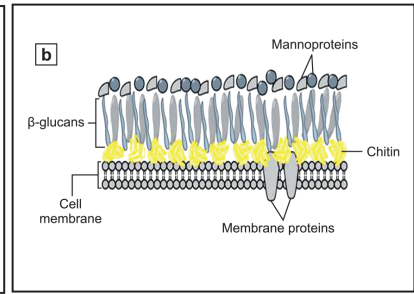
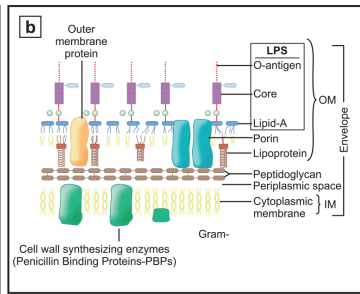
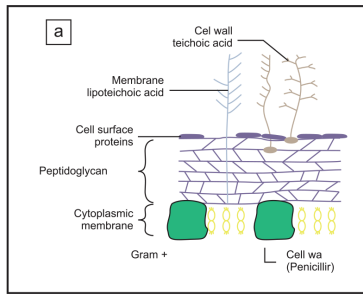
- *Pneumococcus, Meningococcus, H. influenzae b*
-

Polypeptide Capsule

- *Bacillus Anthracis*
-

Hyaluronic acid Capsule

- *Streptococcus*
-



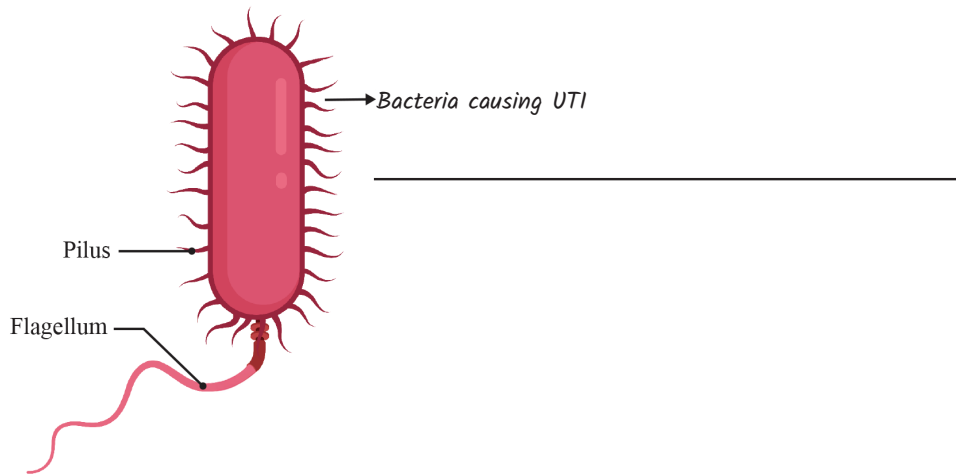
Morphology



Cell wall



Morphology → **Fimbriae/Pili**



Microscopy

Bright Field Microscopy



Thick organisms

Dark Field Microscope



Phase contrast microscope



Thin organisms



Culture Media → **Transport Media**



Keeps stool pathogens alive



Culture Media → **Enrichment Media**



Inhibits Stool Commensals



Alkaline Peptone H₂O




Selenite -F
broth

Tetra thionate
broth

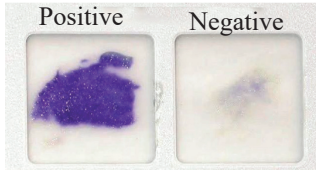


Biochemical Tests



Catalase test → No bubbles → - ve

Catalase test -ve → _____



Oxidase test → blue color → +ve

Oxidase +ve →

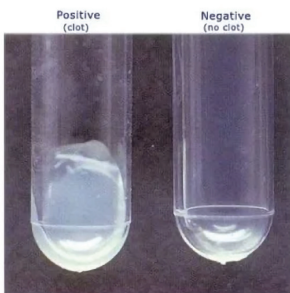
→ _____



Urease test → pink color → +ve

Urease +ve → _____

→ _____




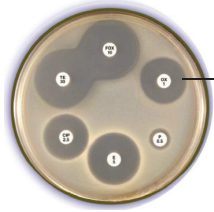
Coagulase test → coagulum → +ve

Coagulase +ve → _____


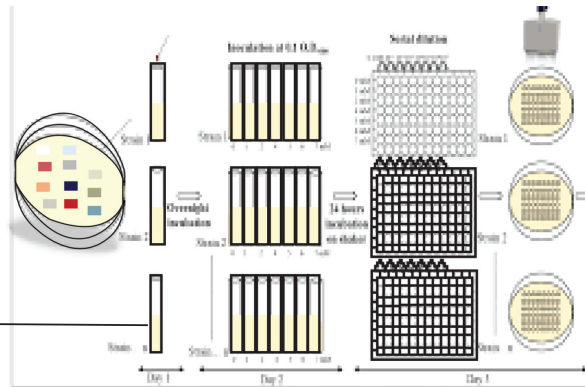


AST - Antimicrobial Susceptibility Testing

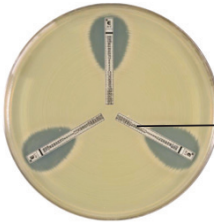KIRBY BAUER'S Disk Diffusion



AGAR/BROTH Dilution



E-Strip





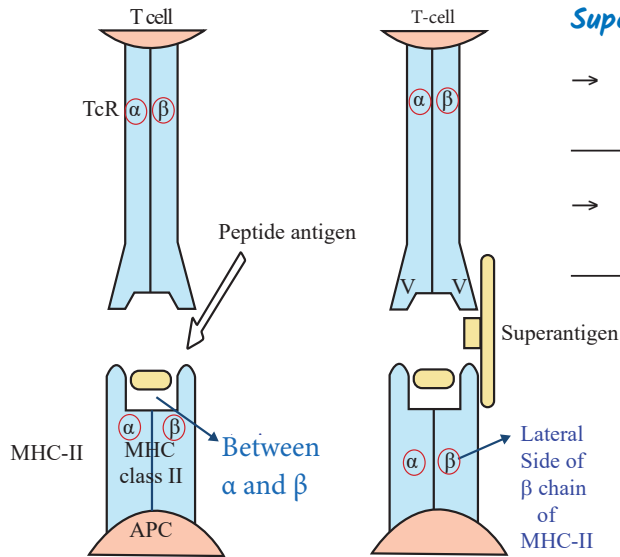
NOTES



NOTES



IMMUNOLOGY



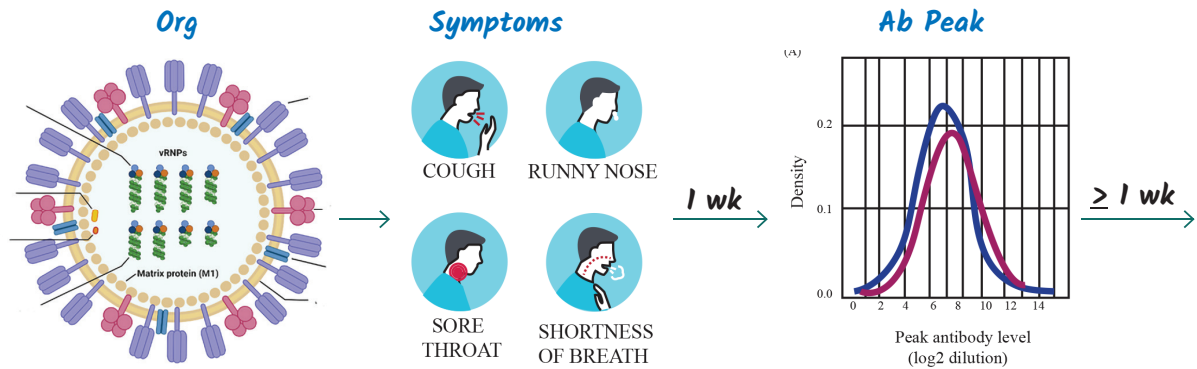
Super Antigen

→ *TSST/ Pyrogenic exotoxin*

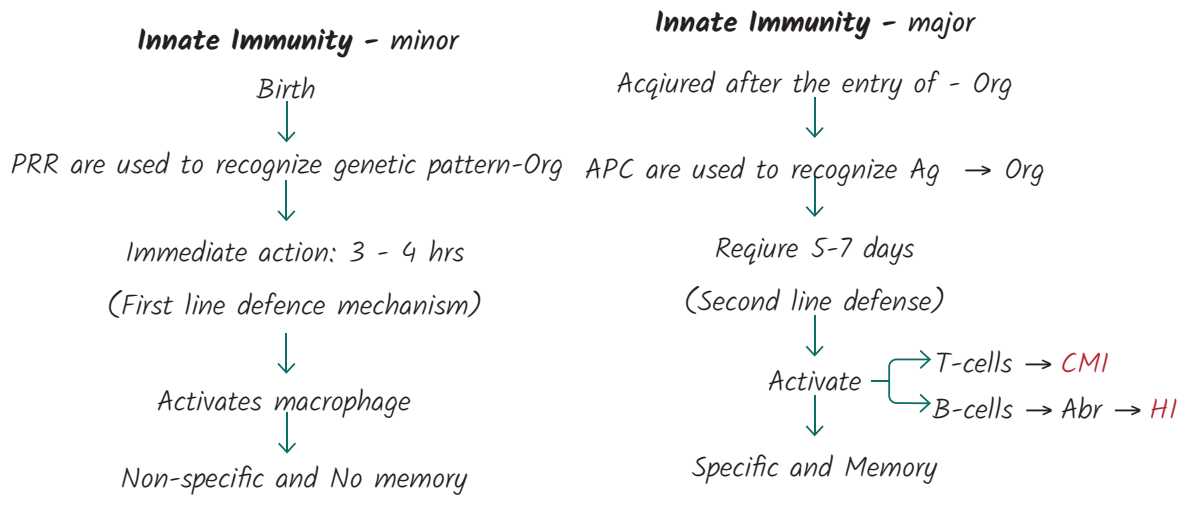
→ *Enterotoxin*



Antibody → Plasma cells (Activated B cells)



Immunity → Defense systems





Acquired Immunity

Active

Ag enter the host
↓
Abs are produced

-
- Infection
 - Vaccination

Passive

Abs are directly received
↓
By the host

-
- IgG from mother to Baby
 - IgG as PEP
 - IgG via blood transfusion

Immuno Deficiency Disorders

HUMORAL IDD

- Bruton's disease - X-linked →

CELLULAR IDD

- Di George syndrome - AD →

COMBINED IDD

- SCID - X-linked > AR →
- Wiskott- Aldrich syndrome - X-linked →
- Ataxia Telangiectasia - AR →

PHAGOCYTIC IDD

- Chronic Granulomatous disease - X-linked →
- Chediak-Higashi disease - AR →

Compliment Deficiency Disorders

C1, C2, C4 →

C3 →

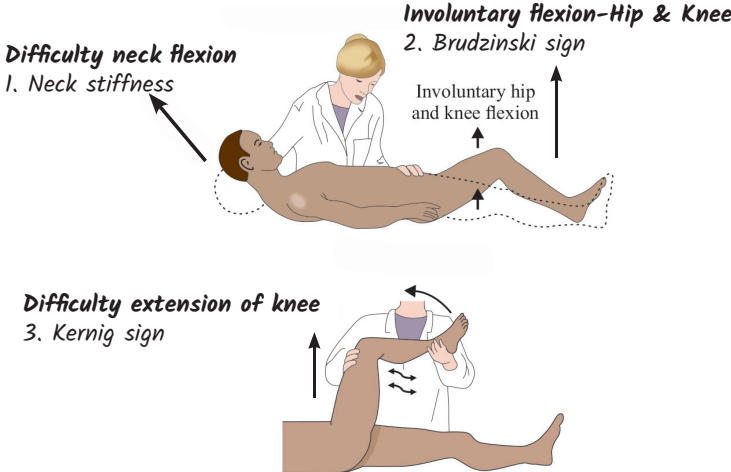
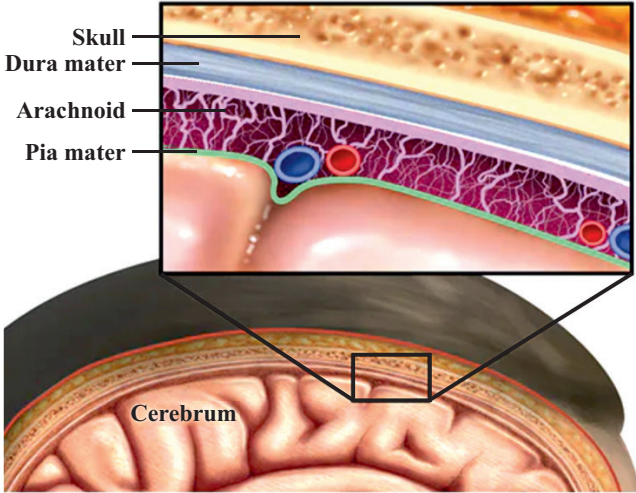
C5b, 6, 7, 8, 9 [MAC] →



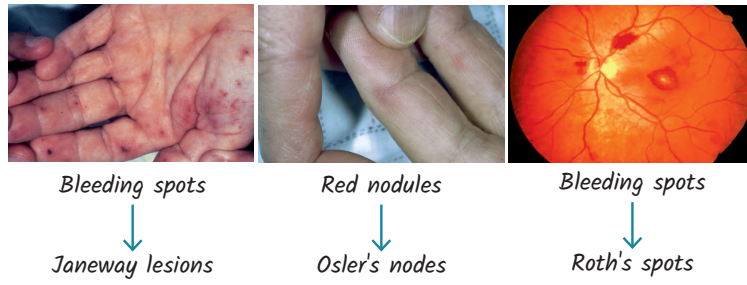
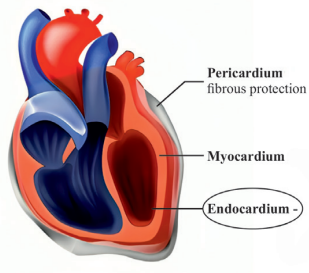
NOTES



BACTERIOLOGY

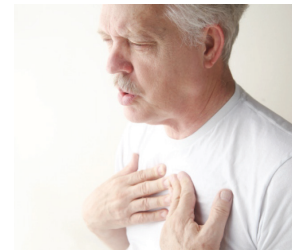
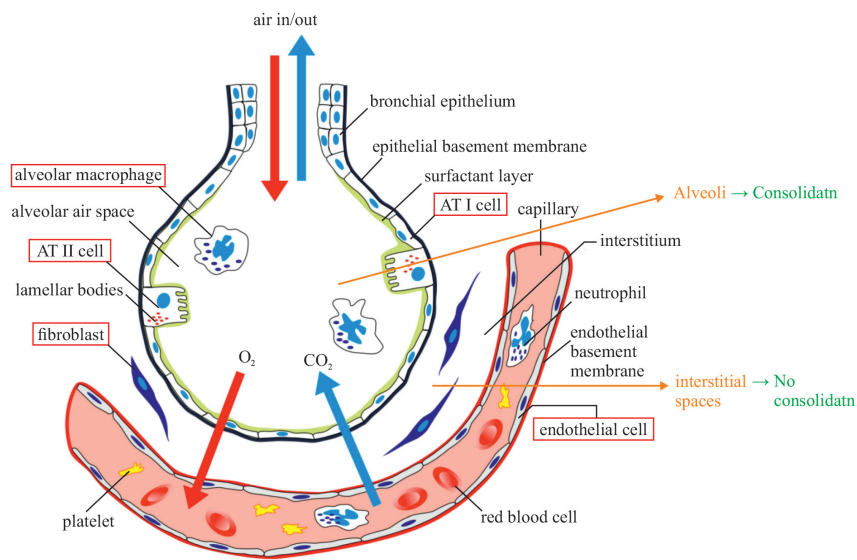


Cells	Glucose	Proteins	Treatment
Highly Increased PMN	Highly decreased Glucose	Slightly Elevated Protein	
Increased Lymphocytes	Slightly decreased Glucose	Highly elevated Protein	



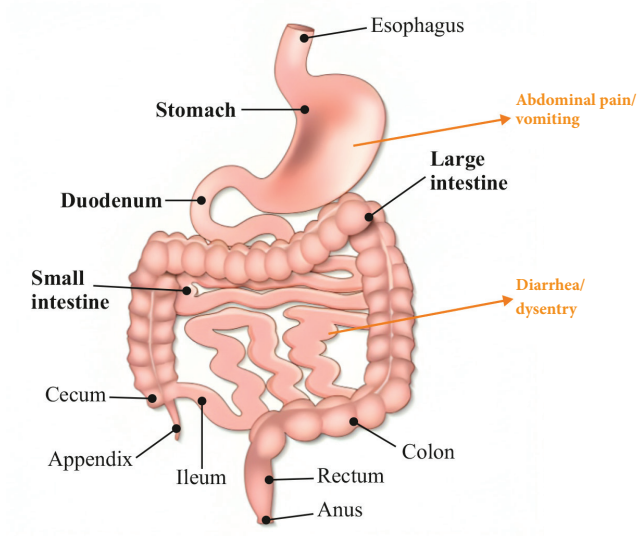
TYPES OF I.E	Native Valve I.E	Early Prosthetic Valve I.E (<1yr of Surgery)	Late Prosthetic Valve I.E (>1yr of Surgery)
Most common Bacteria org →			

Rx → _____




Breathing difficulty

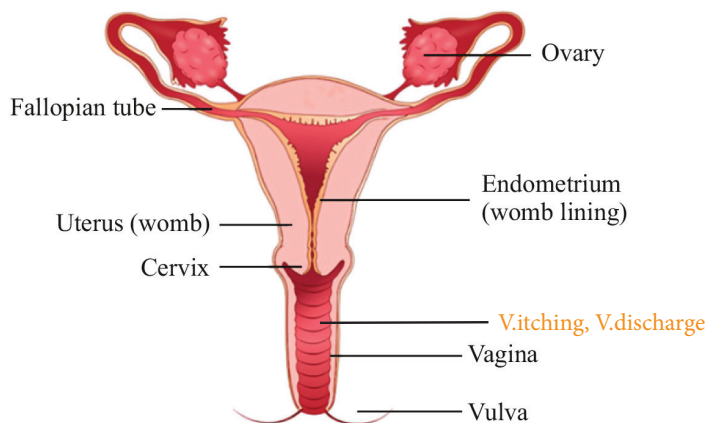
TYPICAL PNEUMONIA (Consolidation)		ATYPICAL PNEUMONIA (No Consolidation)	
BACTERIAL		BACTERIAL	VIRAL/FUNGAL/Parasitic
m.c overall-		m.c-	m.c V-
m.c nosocomial-			
m.c - Cystic fibrosis-			m.c F-
m.c - VAP-			m.c F CD<200-
			m.c P-



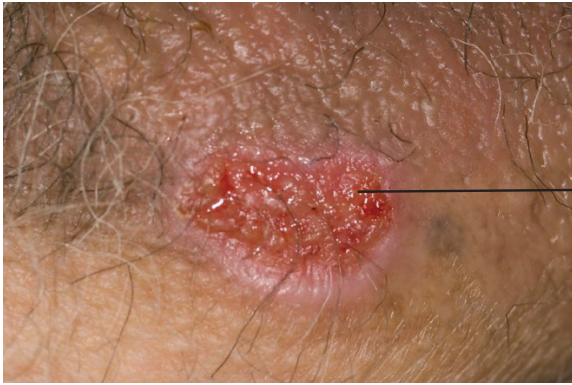BACTERIAL G.E				
<i>Pre-formed TOXINS-Heat stable</i>				<i>Post formed TOXINS (I.P > 8 hrs) Heat labile</i>
<i>I.P < 6 hrs</i>		<i>I.P > 16 hrs</i>		
<i>Staph aureus</i>	<i>Bacillus cereus</i>	<i>Clostridium botulinum</i>		<i>Rest all</i>
<i>Enterotoxin</i>	<i>Emetic toxin</i>	<i>C2 botulinum toxin</i>		
_____	_____	_____		



Gonococcal Urethritis (GU)	Non-Gonococcal Urethritis(NGU)	
BACTERIAL	BACTERIAL	V / F/ P
Gonococcus	m.c - Chlamydia	V- HSV-2
GIS	Mycoplasma	F- C.albicans
Rx	Ureaplasma	P- T.vaginalis



Vaginal itching	No	Mild	Severe
Vaginal discharge	White - fishy smell	Green - fishy smell	Curdy white -no smell
Diagnosis			
Diagnosis			
Treatment			



Genital Ulcer/Bubos

<i>Painless ulcer</i>	<i>Painful ulcer</i>	<i>Painless ulcer</i>	<i>Painless ulcer</i>
<i>Painless pseudobubos</i>	<i>Painful bubos</i>	<i>Painless bubos</i>	<i>Painful bubos</i>

Bacterial Toxins

Increase cAMP
↓
Bacillus anthracis
Anthrax toxin

Inhibiting EF2
↓
Coryne diphtheriae
Diphtheria toxin

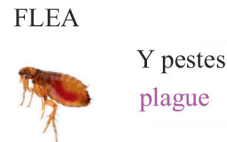


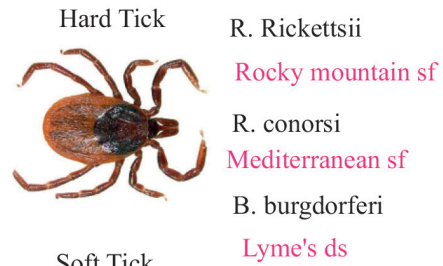
Inhibiting Ach Neurotransmitter
↓
Cl. botulinum
Botulinum toxin

Vibrio cholerae
Cholera toxin

Pseudomonas
Exotoxin A

Inhibiting GABA Neurotransmitter
Cl. tetani
Tetanospasmin

Bacterial Vector Transmitted Diseases



Bacterial Zoonotic Diseases



→ Calf m/s tenderness, conjunctival suffusion, hepato-renal syndrome

→ Test - Microscopic Agg Test (MAT) +ve

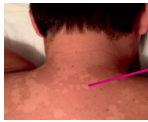→ Rx -



NOTES

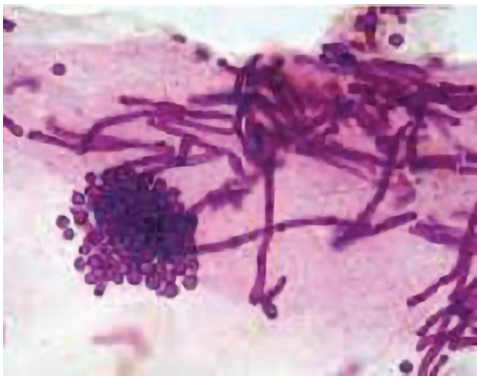


MYCOLOGY



Hypopigmented patches

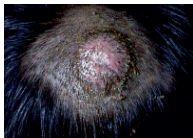Wood's lamp examination
Golden yellow fluorescence



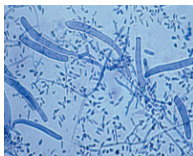Yeast cells & hyphae

Meat ball & Spaghetti app

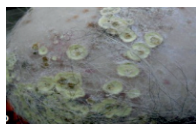
- Rx
- Oral →
 - Topical →



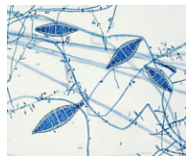
Boggy lesion



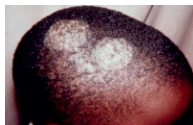Pencil-shaped conidia



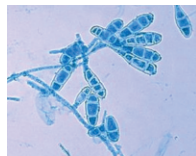
Cup-like crusts



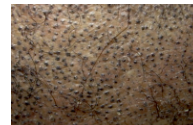
Boat shaped conidia



Grey patch

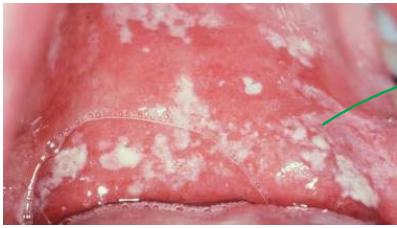

Club shaped conidia



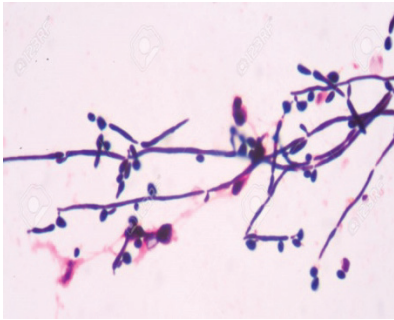
Grey patch with black dots

- Rx
- Oral →
 - Topical →



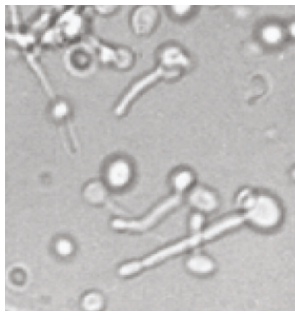White colour membrane
may be scraped off on repeated rubbing
On skin & muscles membrane

G/S



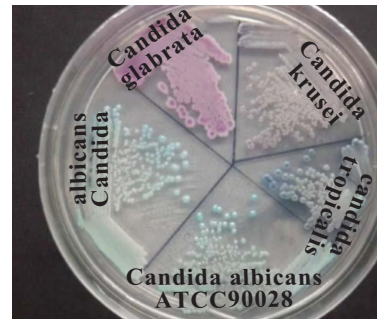
Yeast cells with pseudohyphae

GTT



Germ tube formation

Chronic agar




Different coloured colonies
identifying different species

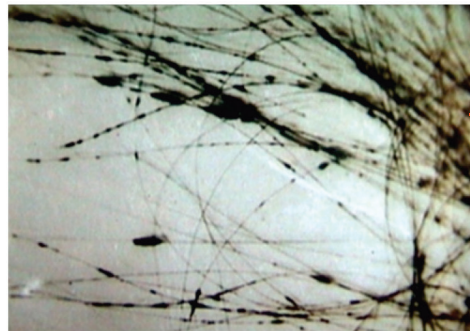
Rx

• Oral →

• Topical →

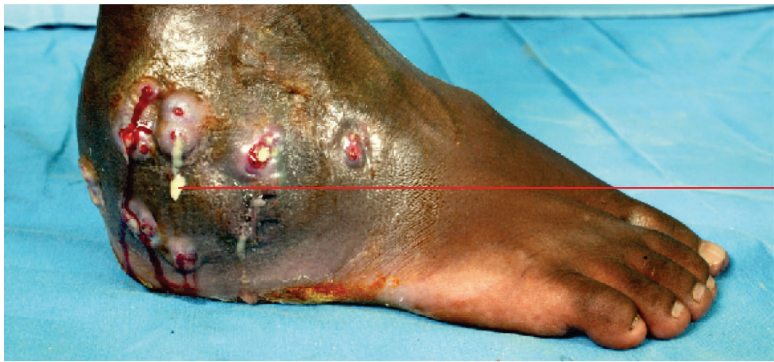


White nodules



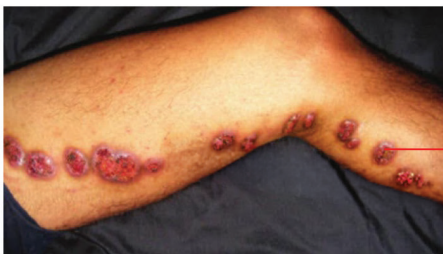Black nodules





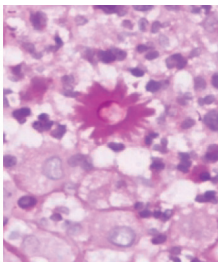
S/c nodules with discharging granules

<i>Eumycetoma (Fungi)</i>		<i>Actinomycetoma (Bacteria)</i>	
GRANULES		GRANULES	
Black	White	Whitish Yellow	Pinkish Red



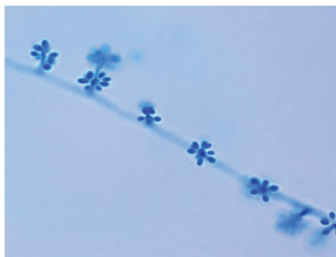
s/c nodules along the lymphatics

Yeast form

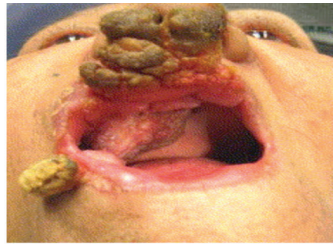


Asteroid body

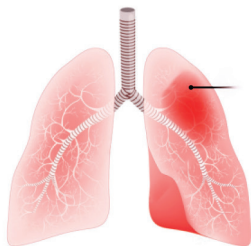
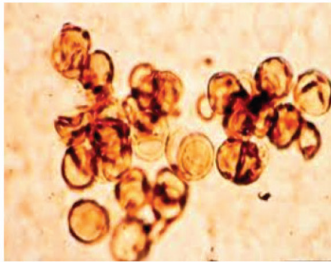
Sept. mould form



Rosette formation-conidia

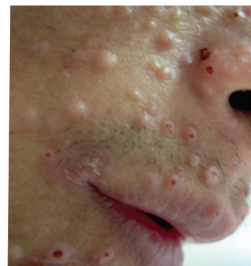

Verrucous lesions (Wart/Califlower like lesions)



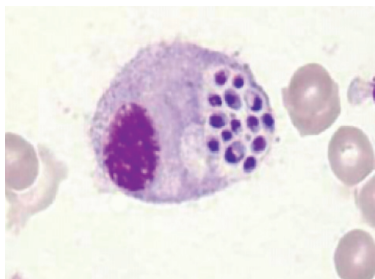
Pneumonia lung nodules

Yeast form

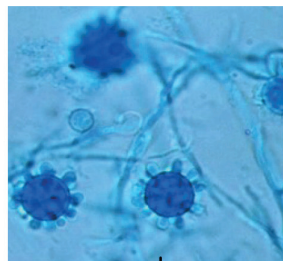


Skin papules/nodules

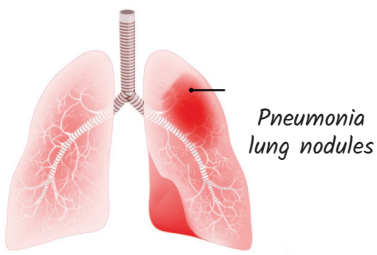
Septate mould



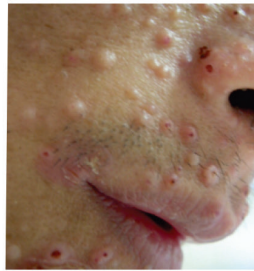Yeast cells within macrophages



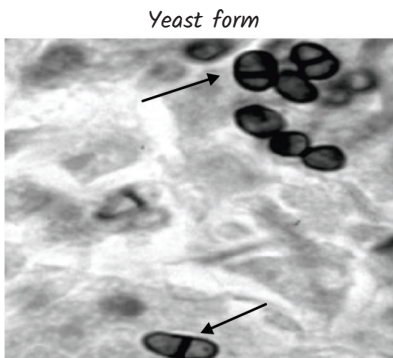
Narrow hyphae with tuberculate conidia



Pneumonia lung nodules

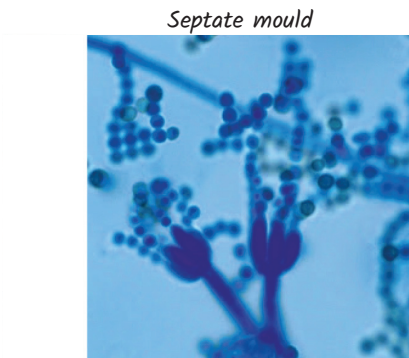


Skin papules/nodules



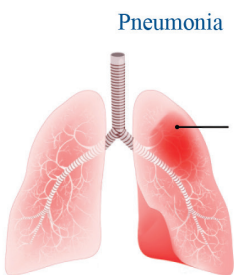
Yeast form

Oval yeast with septum inside

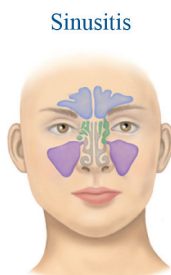


Septate mould

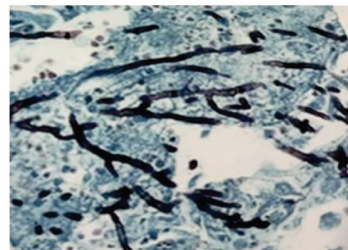
Conidia with bottle brush appearance



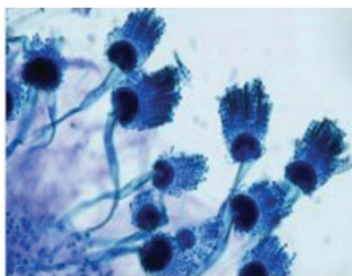
Pneumonia



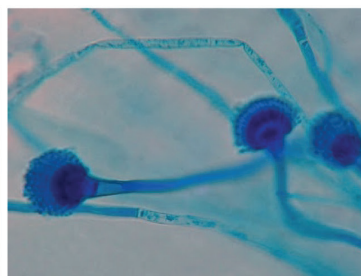Sinusitis



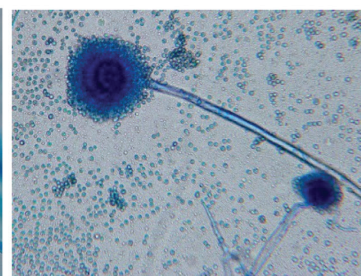*Sample microscopy
Acute angle with dichotomous branching*



1/3rd vesicle



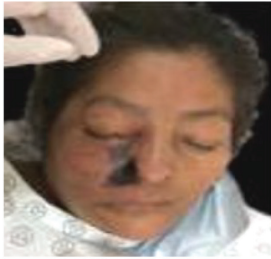2/3rd vesicle



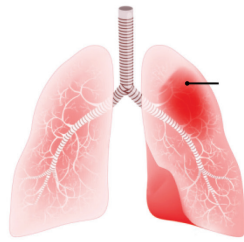
Complete vesicle



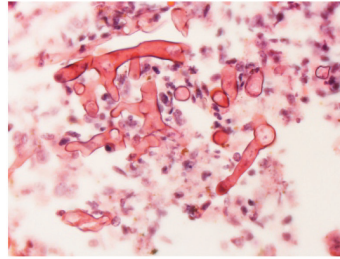
Paranasal pain



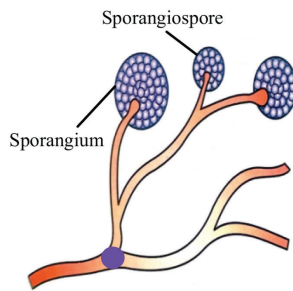
Pneumonia



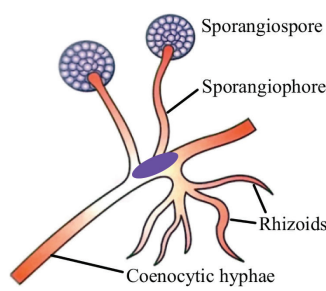
Sample microscopy



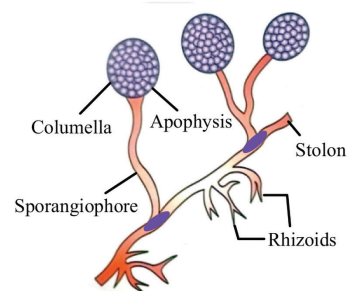
*Broad/
ribbon-like
hyphae with
right angle
branching*



No Rhizoids



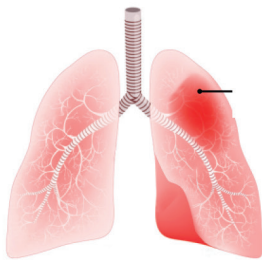
Nodal Rhizoids



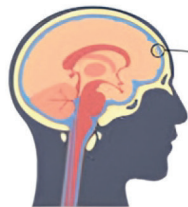
Internodal Rhizoids

Rx

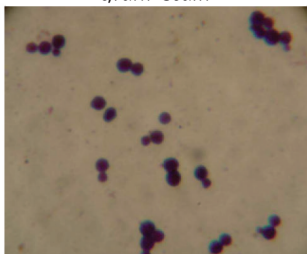
Pneumonia



Meningitis

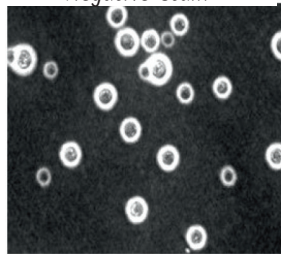


Gram stain



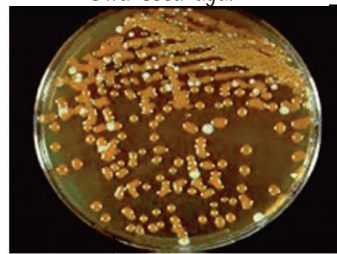
Budding yeast cells

Negative stain



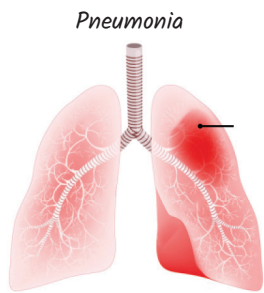
Halo capsule

Bird seed agar



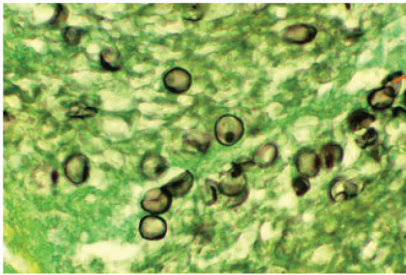
Brown colour - melanin pigment

Rx



→ Non-cultivable fungus

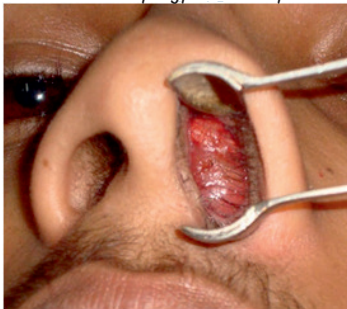GMS stain



Black cysts

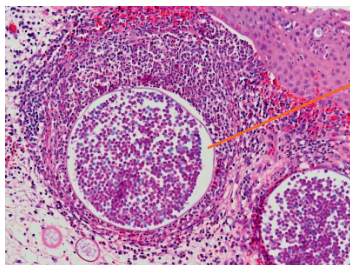
Rx

Nasal polyps with epistaxis



→ Non - cultivable aquatic protozoa

Sample microscopy



Spherule
(Sporangium containing endospores)

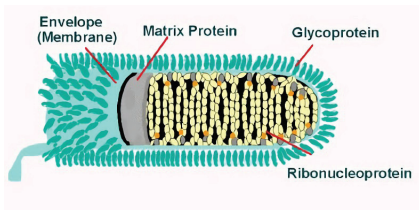
Rx



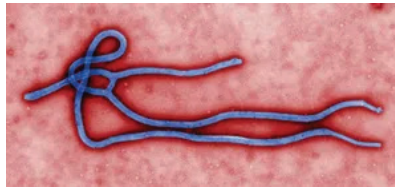
NOTES



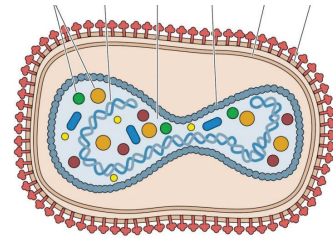
VIROLOGY



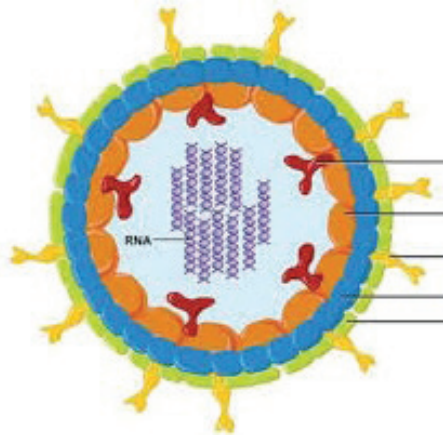
Bullet Shape



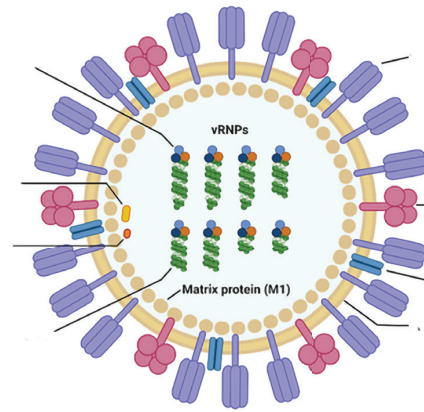
Filamentous



Box Shape

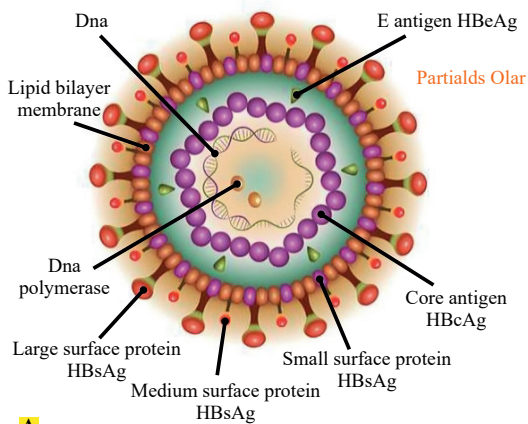


11 segmented RNA



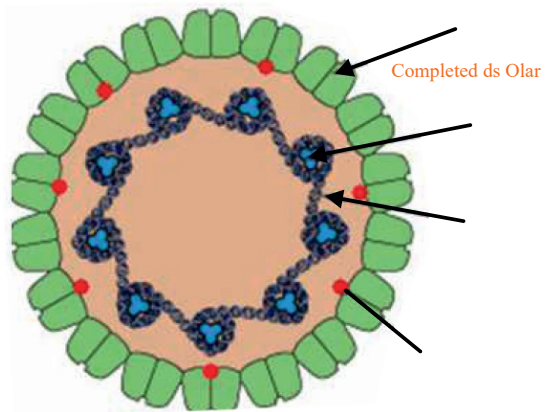
8 segmented RNA

(VIRUSES → Circular Nucleic acid)



A

Partially ds circular DNA



B

Completely ds circular DNA

Herpes V (HHV) → Vesicles → Tzanck smear → MNGs

- Vesicles → temporal lobe encephalitis → upper body
- Vesicles → Genital Herpes → Genital Ulcers → Neonatal Herpes → Mollaret's meningitis
- Vesicles →
 - Entire body → Primary infection → Chicken pox
 - Dermatomes → Reactivation infection → Herpes Zoster/Shingles

- IMN →
 - Gastric Ca, Nasopharyngeal Ca
 - Burkitt's and Hodgkin's lymphoma
- IMN → Post transplant infection → any disease except nephropathy
 - ↓
 - BKV

- Encephalitis →

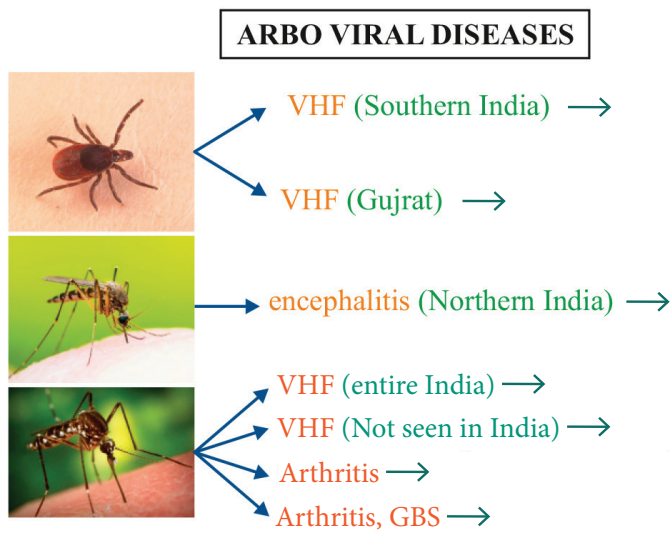
- Kaposi sarcoma → Reddish vascular tumours

HPV Infections

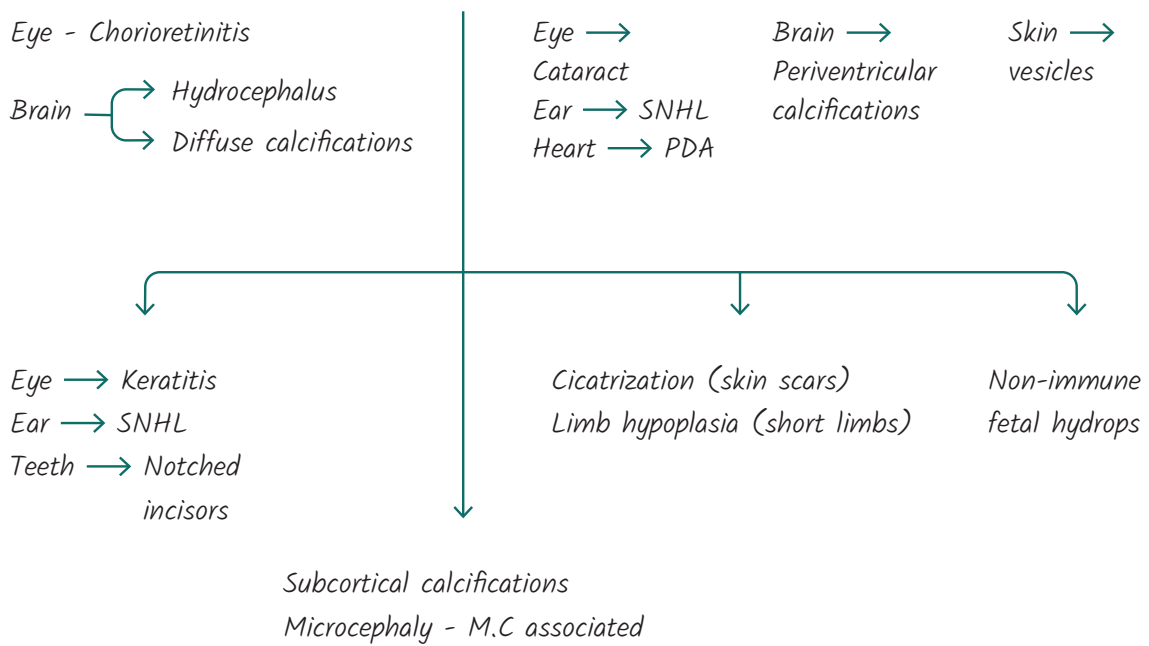
- - Anogenital warts → Low-risk serotypes (Condyloma acuminata)
 - Oropharyngeal cancer → High-risk serotypes
 - Uro-genital cancer (Penile Ca, Cervical Ca)
- Oncogenes →
- Vaccine → Gardasil-9 → Subunit

Parvovirus B-19 Serotype Infections

- - Children →
 - Adult →
 - Sickle cell anemia →
 - Immunocompromised →
- Congenital Infections →



Congenital infections





Lab diagnosis of Viral Infection

H →	AR →	HPR-JWM →	Others →
Hepatitis B	Adenovirus Rotavirus	Hepatitis (A, C, D, E) HIV and Hanta Parvovirus and Rubella J.E, West Nile, Measles	Remaining viruses

Duration from symptoms given



Treatment of Viral Infections

- 1. Hepatitis — { → HBV
 → HCV
- 2. Herpes -
- 3. HIV -
- 4. Influenza -



NOTES

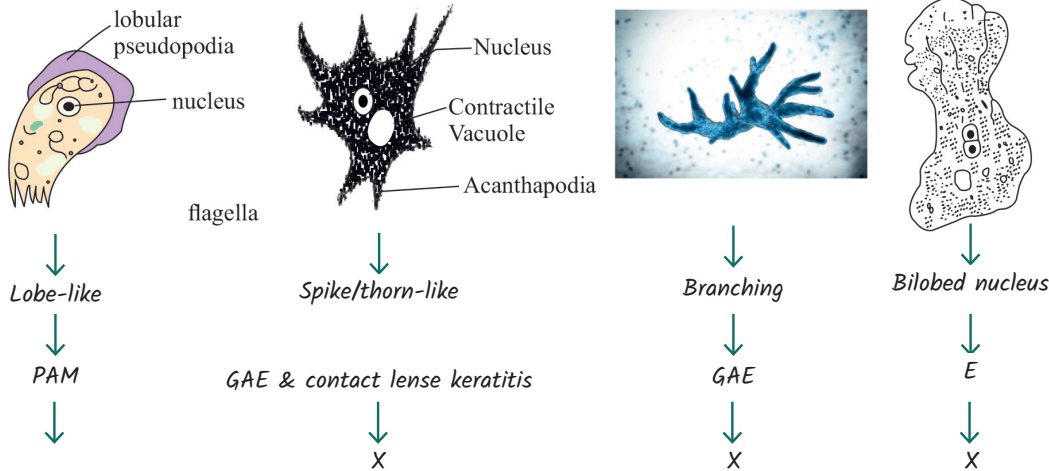


NOTES



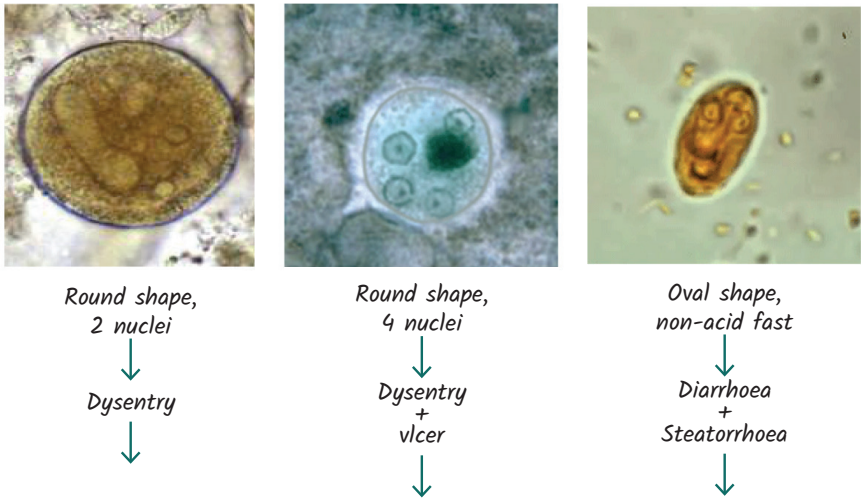
PARASITOLOGY

Free Living protozoa → Soil & H₂O → via swimming



Rx →

Non-acid fast intestinal protozoa

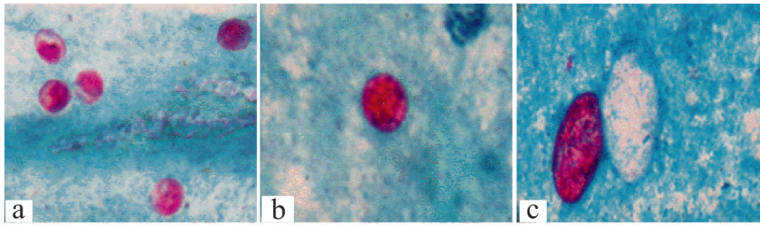


Symptomatic
Asymptomatic

Rx →



Acid fast intestinal protozoa



Round 4-5 micron

Diarrhoea



Round 8-10 micron

Diarrhoea



Oval acid-fast

Diarrhoea



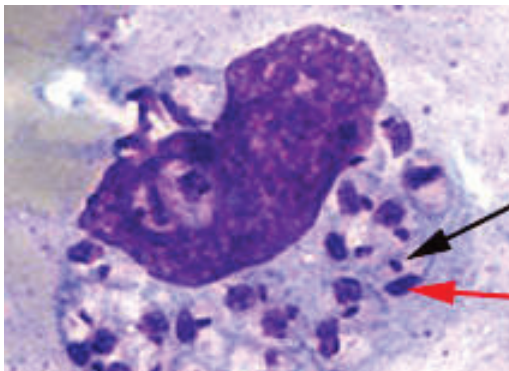
Rx →



Sand fly

PBS → Amstigote form

HCM with hyperpigmentation
MC seen in Bihar



Round shape with
Kinetoplast and
rk39 Ag within
macrophage

Rx →

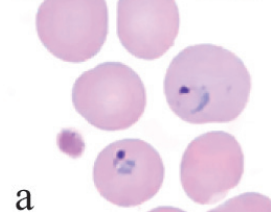
- Oral →
- IV →



Fever, chills, HSM

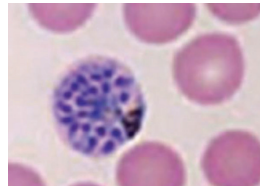
Anopheles mosquito

Single ring forms



a

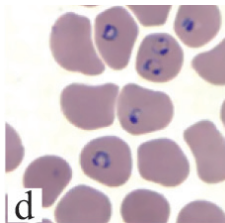
Schizont



Only pLDH Ag

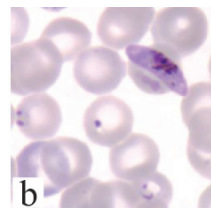
Round shape

Multiple ring forms



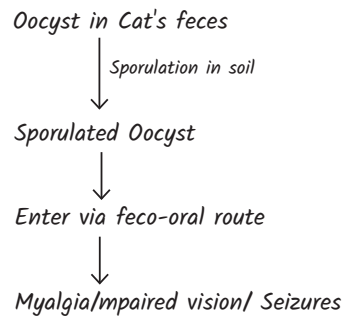
d

Gametocyte

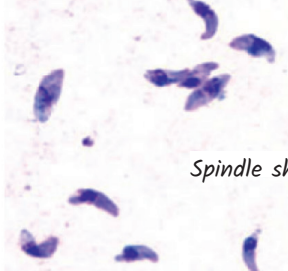


pLDH + HRP-2 Ag

Banana shap

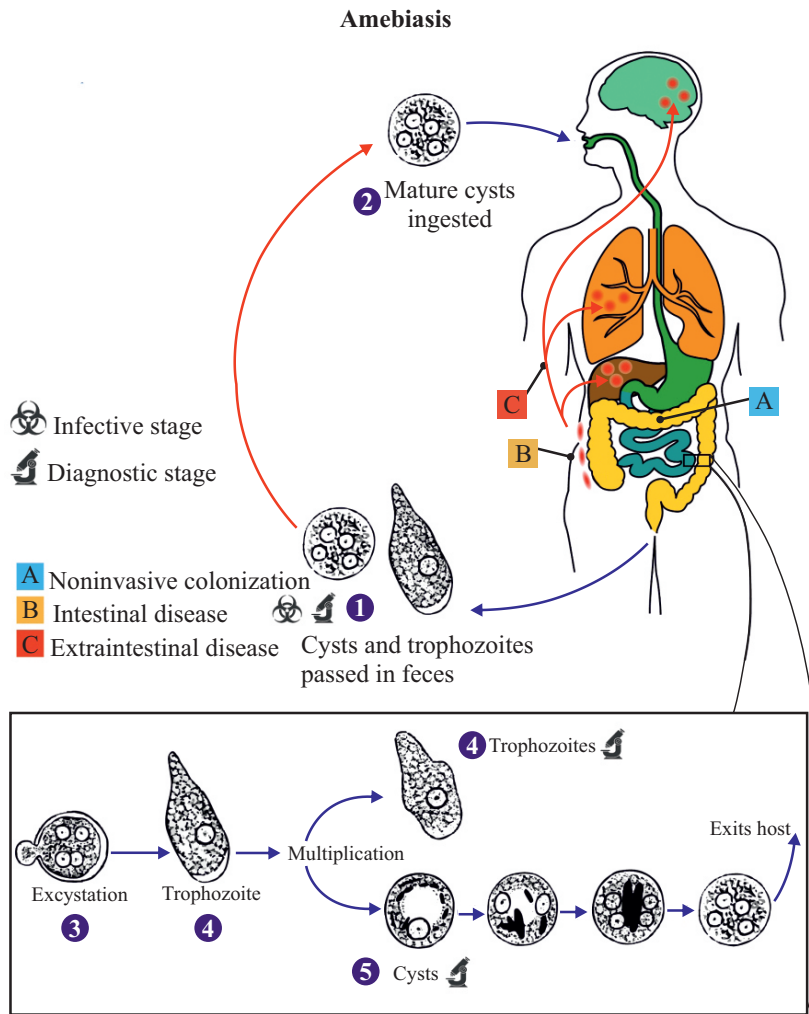


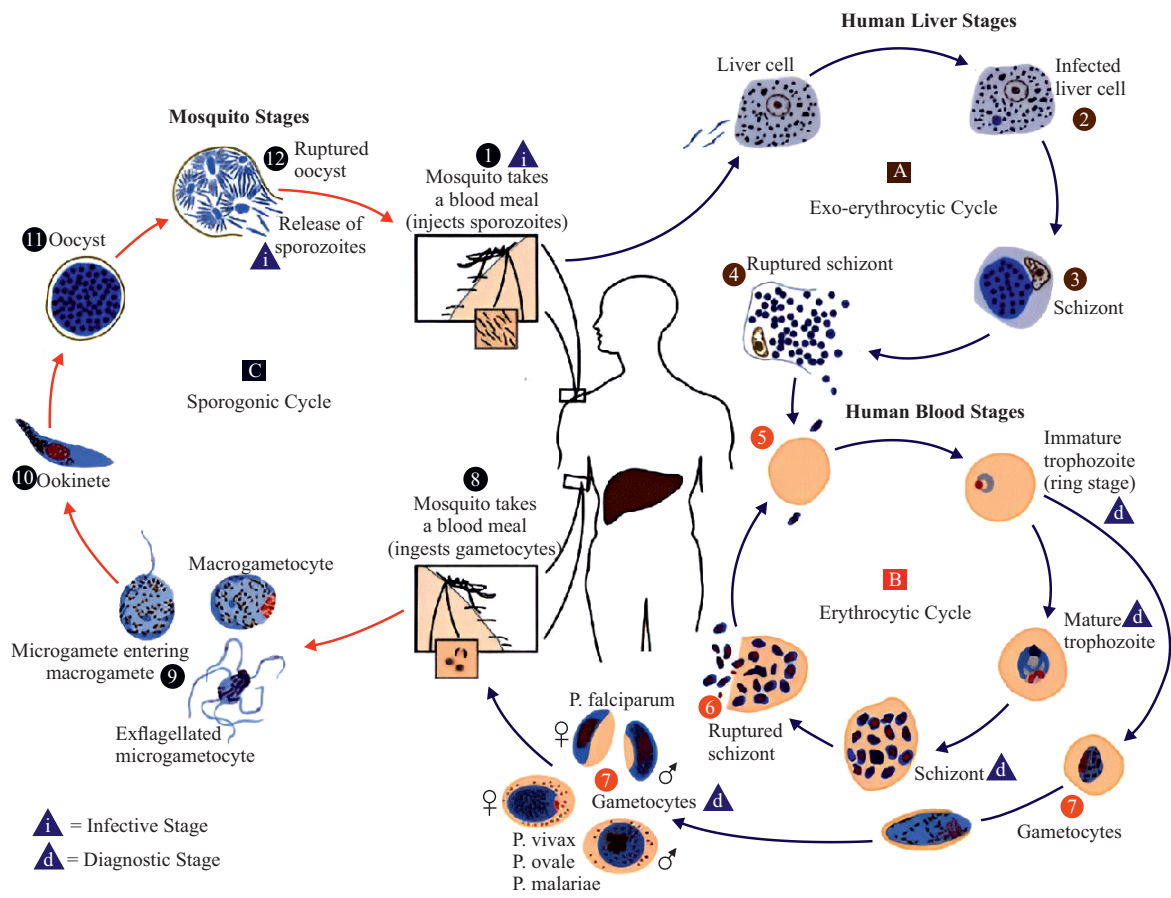
PBS → Tachyzoites

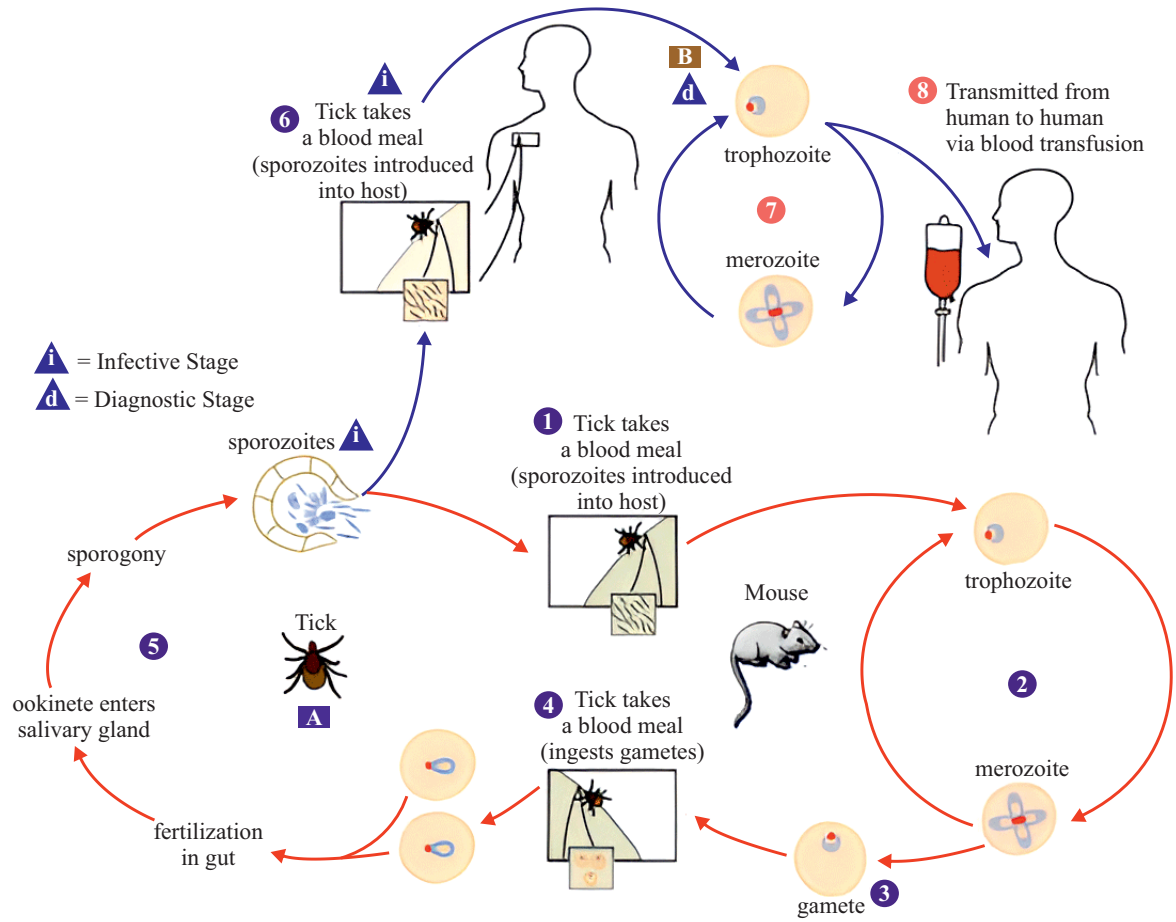


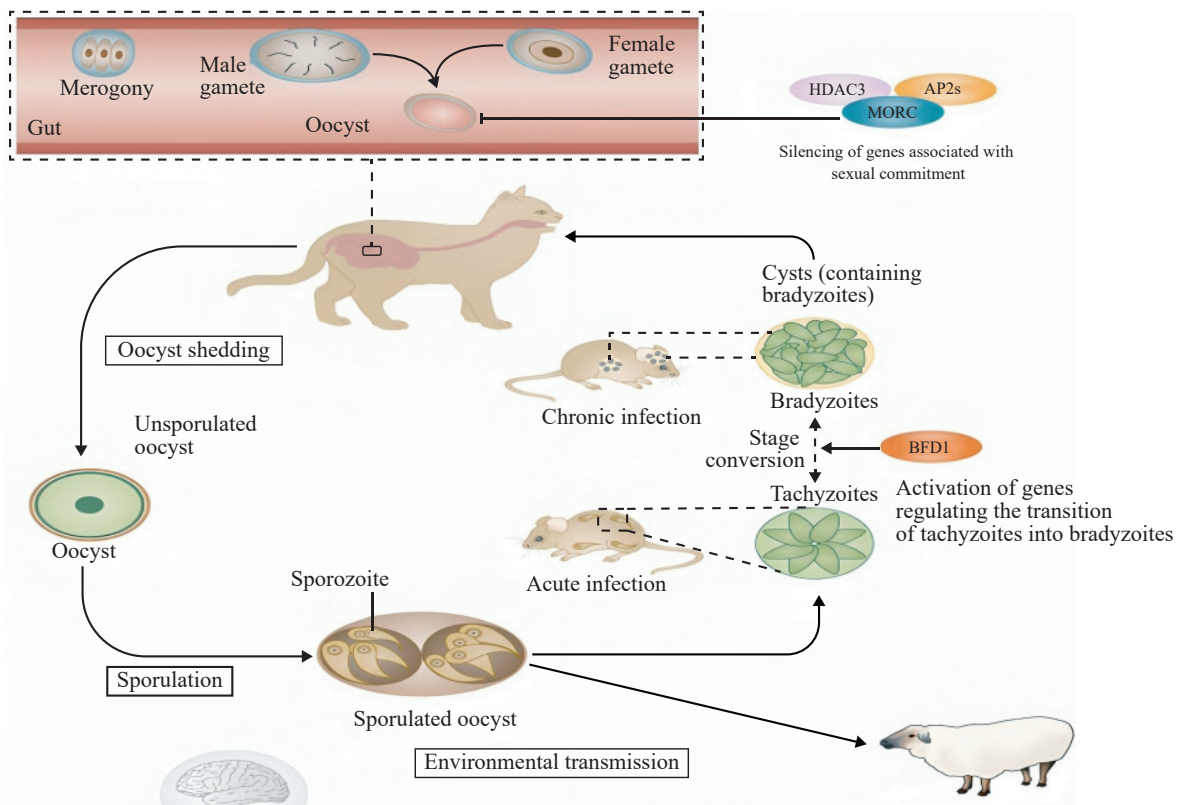
Spindle shaped

Rx

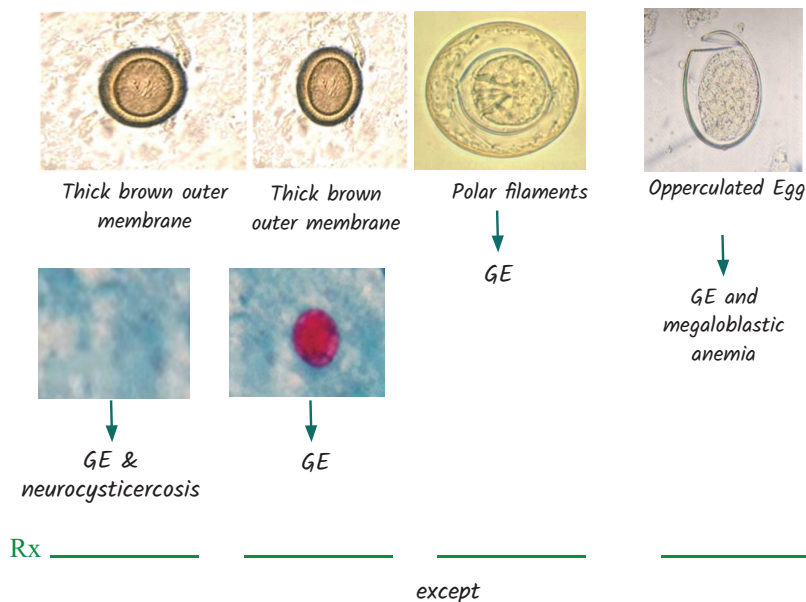








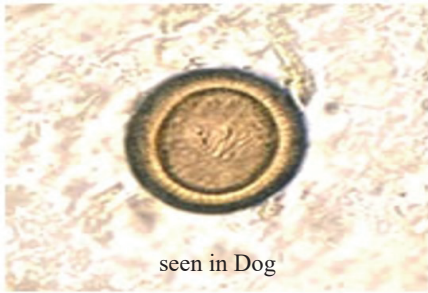Intestinal Cestodes



Neurocysticercosis →



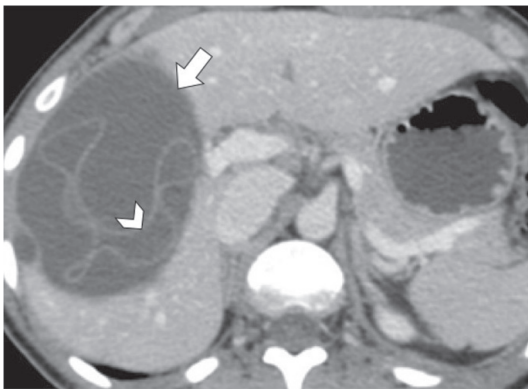
Tissue Cestode



Formation of hydatid cysts
In Liver > Lung
↓ ↓
Jaundice Penumonia

Imaging - USG/CT - Hydatid Cyst with Water Lily Sign

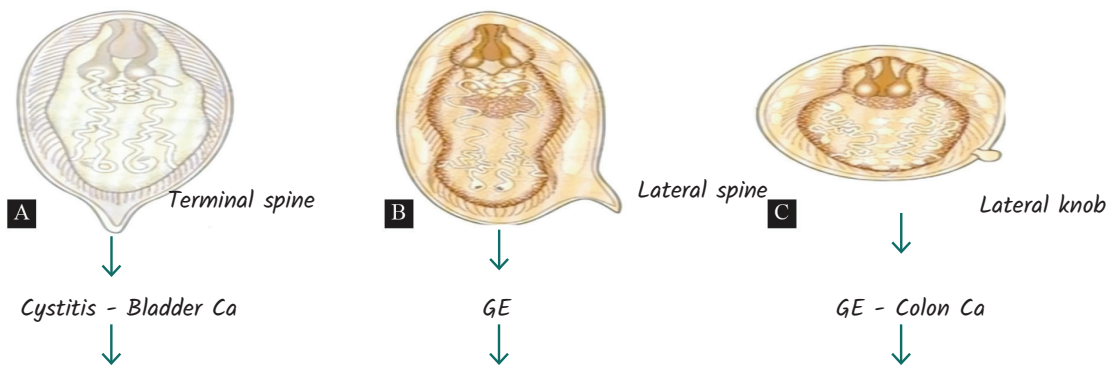
↓
Ab-ELISA



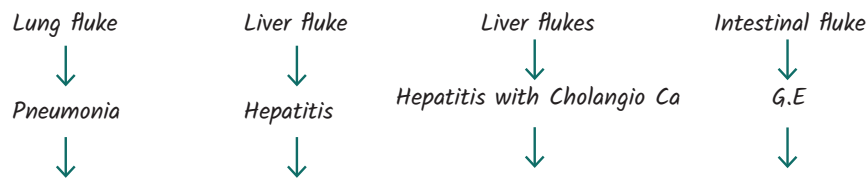
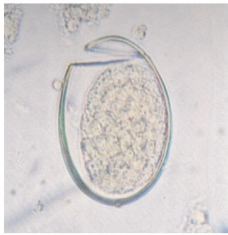
Rx { PAIR > Surgery (If PAIR fails)
+ }



Trematode → Egg with Spine/knob → Rx



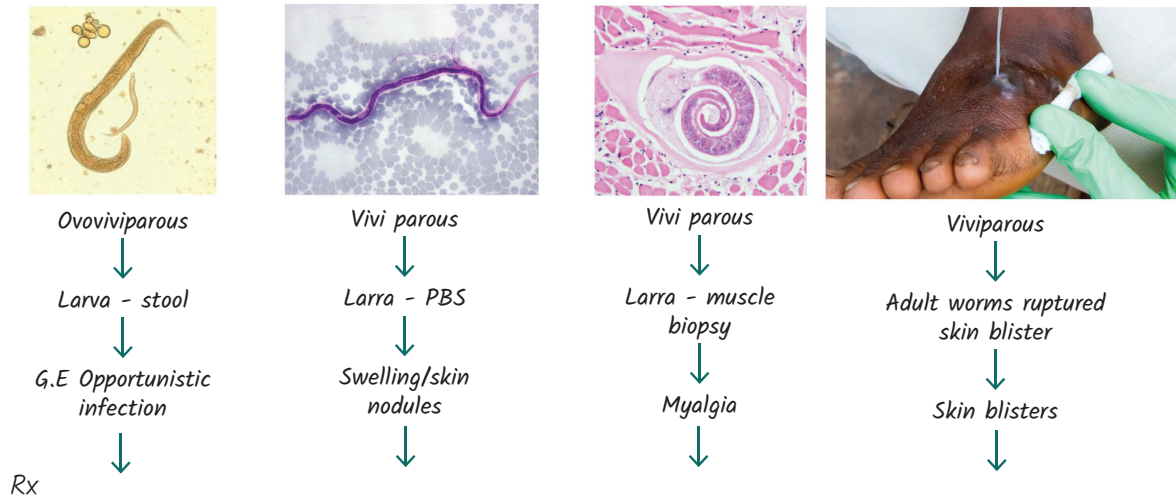
Trematodes → Egg with operculum



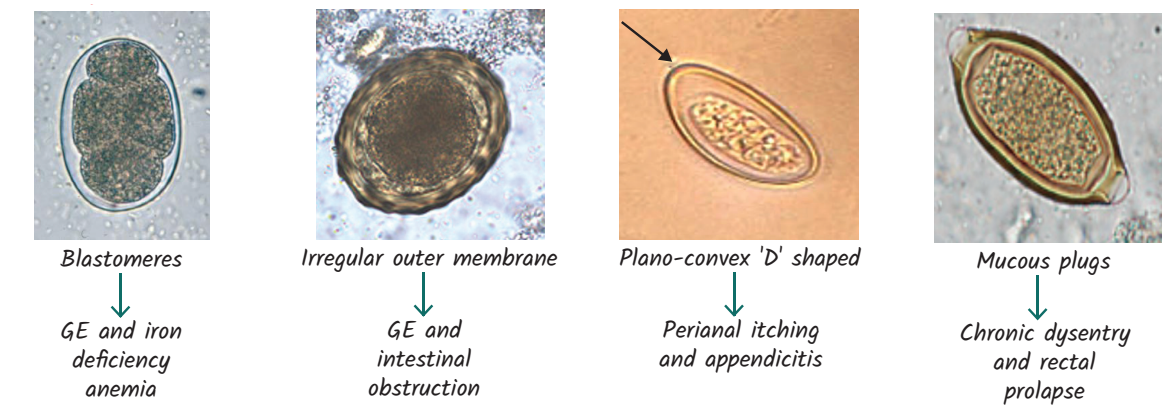
Rx



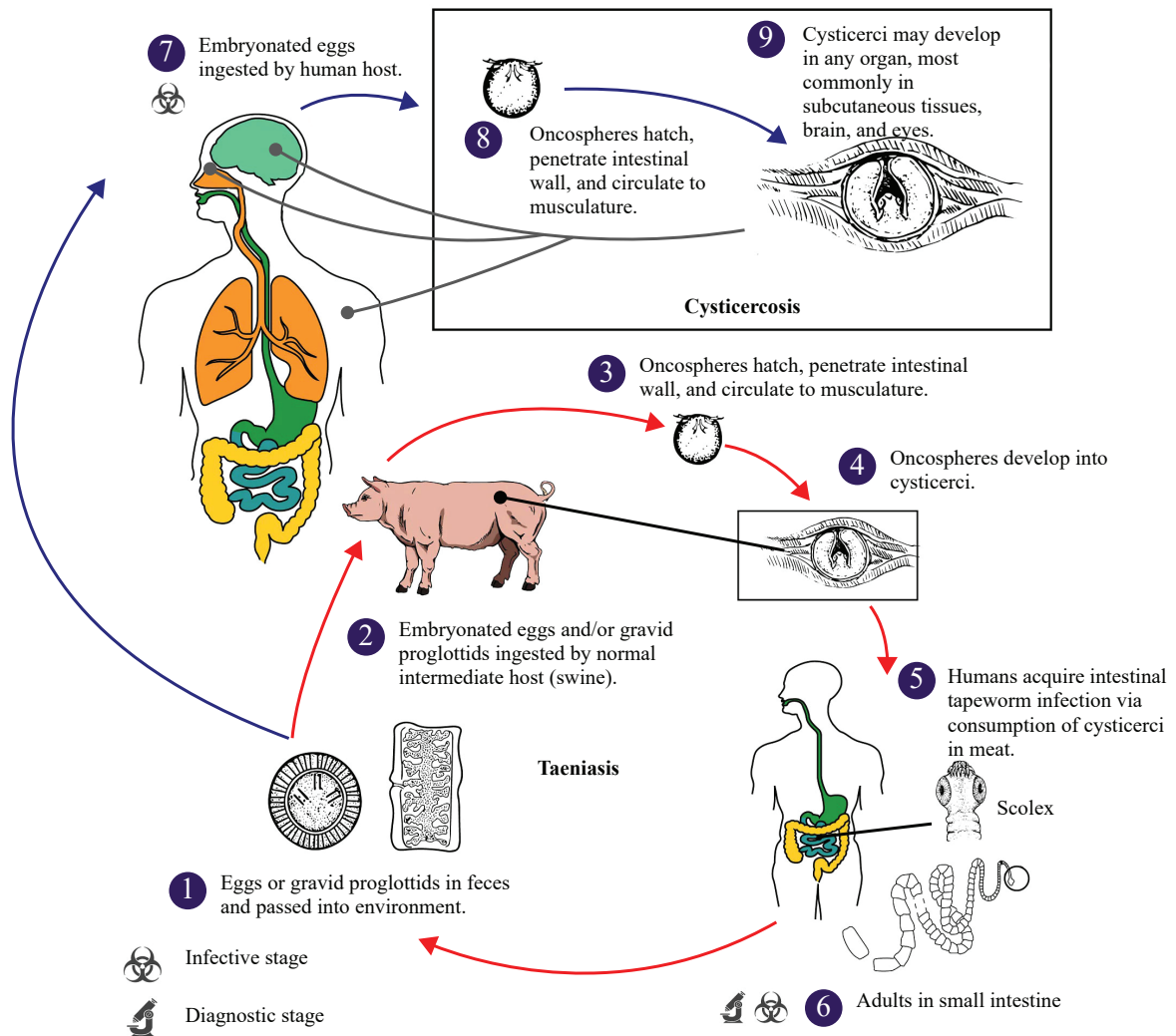
Nematodes → Larval/adult worm as diagnostic forms

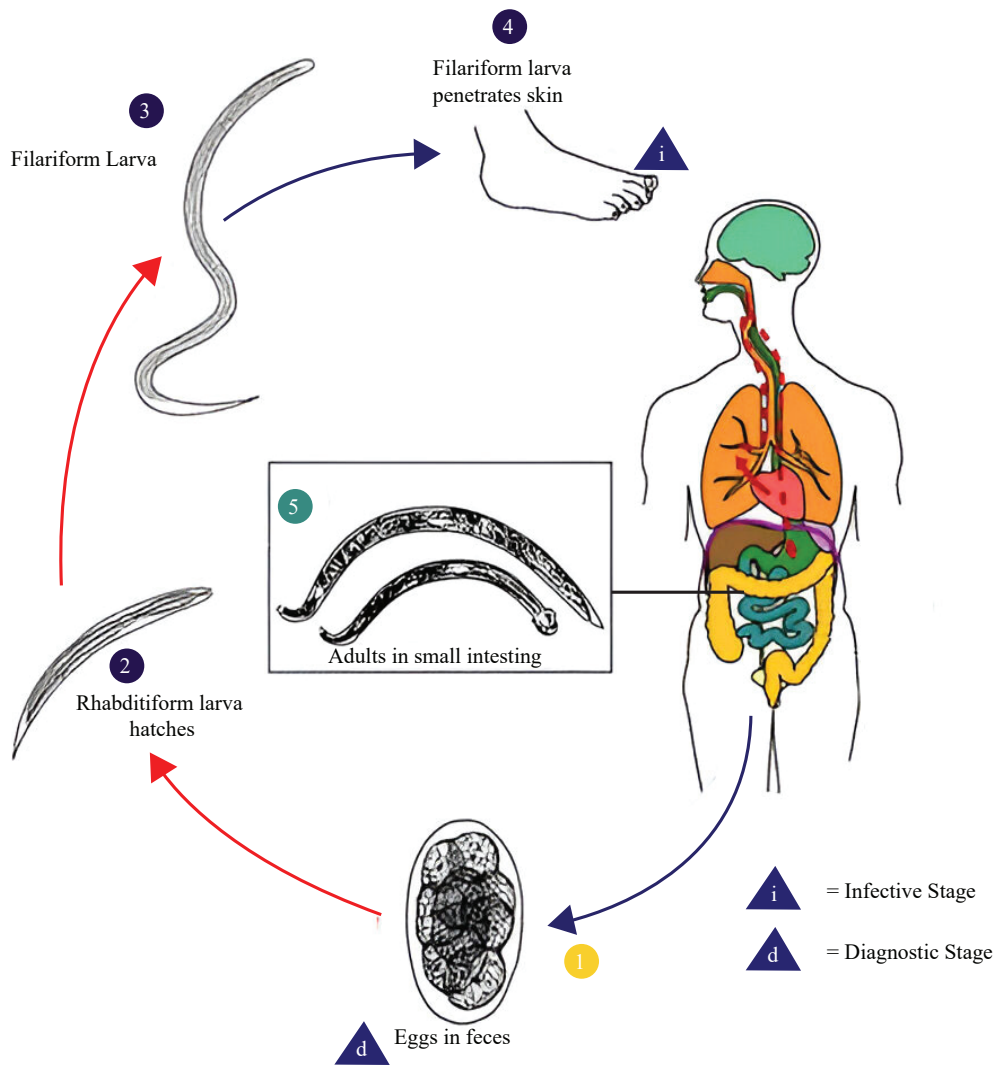


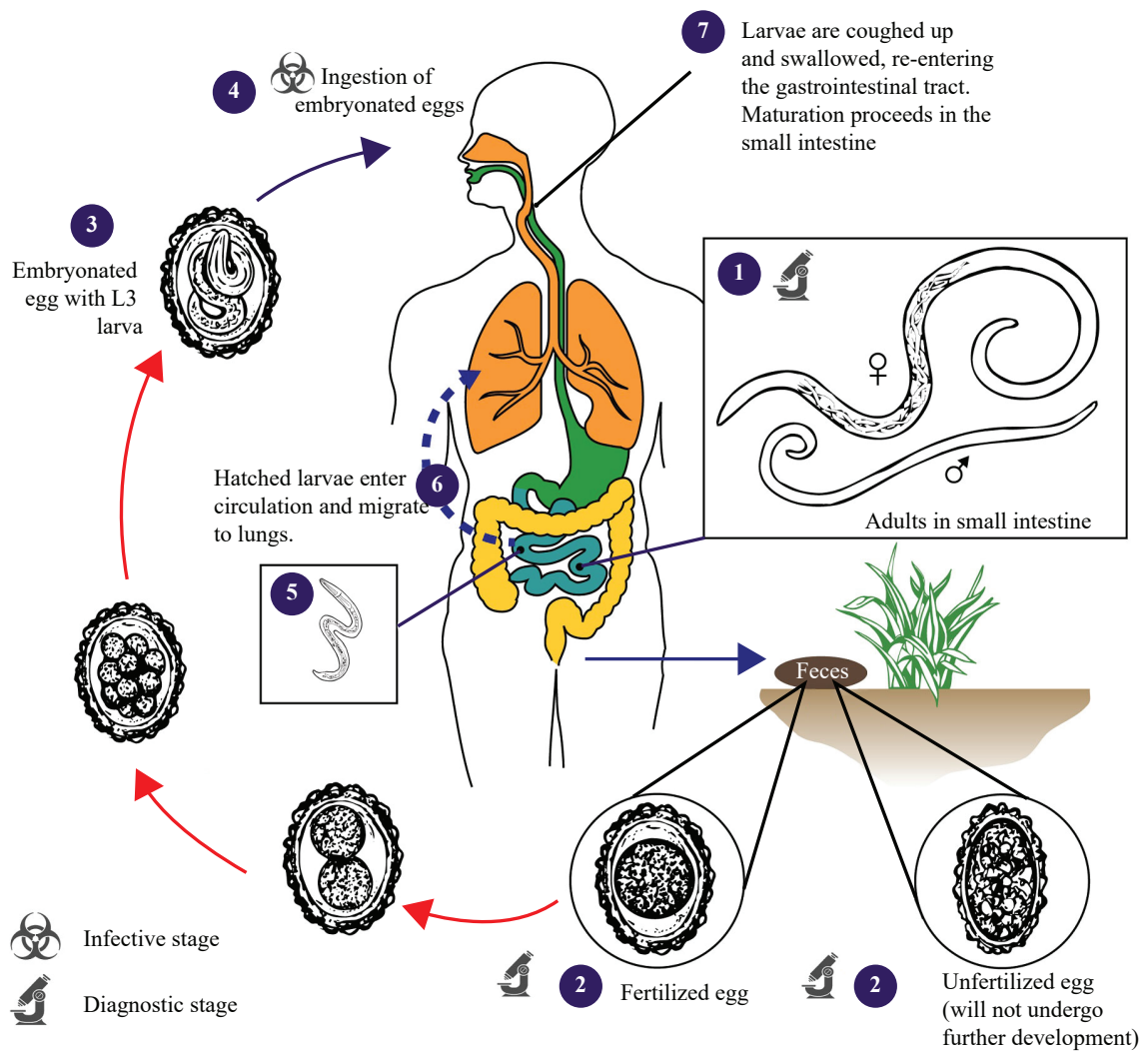
Nematodes → Egg act as diagnostic form

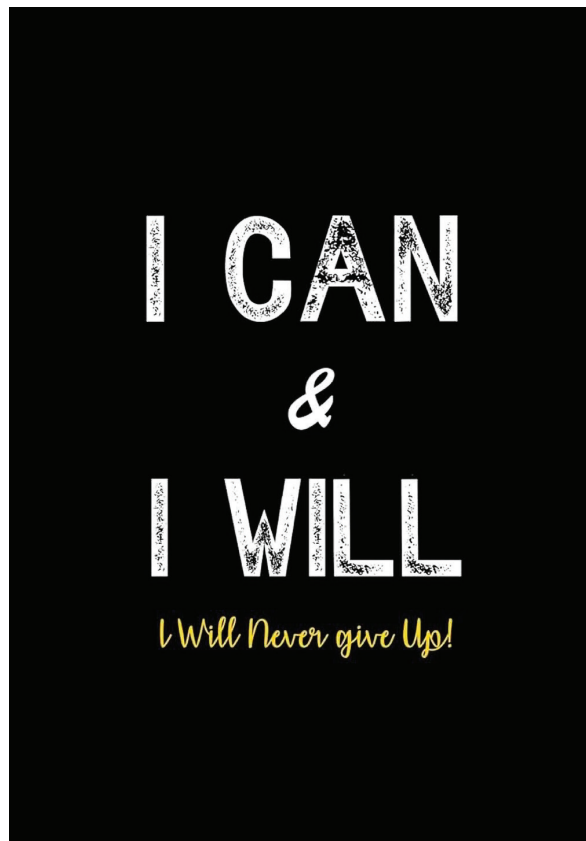


Rx _____









THANK YOU
AND
ALL THE BEST!



NOTES



NOTES