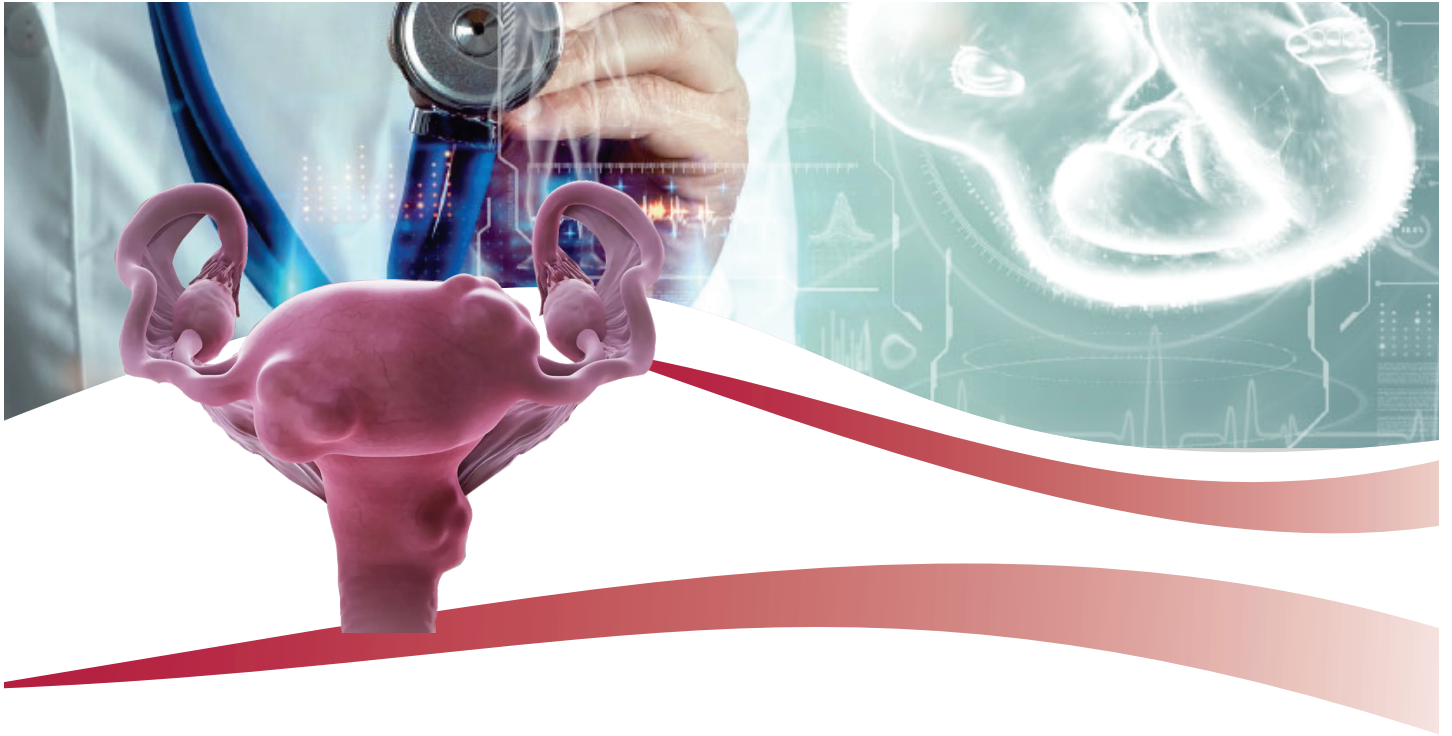


OneShot 4.0  
**Obstetrics &  
Gynaecology**



# OBSTETRICS & GYNAECOLOGY

<i>Sl. No.</i>	<i>CHAPTER</i>	<i>Page No.</i>
1	<i>Obstetrics</i>	229
2	<i>Gynaecology</i>	274

“

Success in medicine isn't just about intelligence; it's about resilience. Keep pushing, keep learning, and remember: every challenge you overcome brings you closer to saving lives.

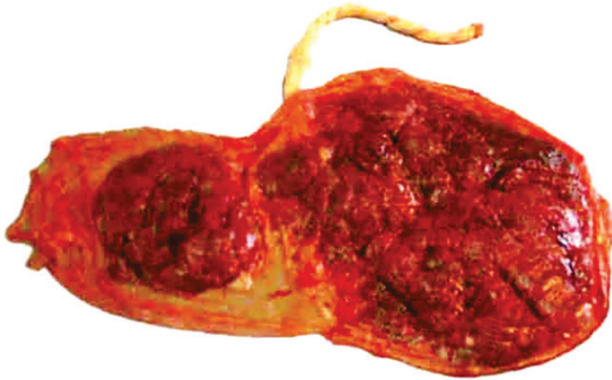- Dr. Ramyasree B

”



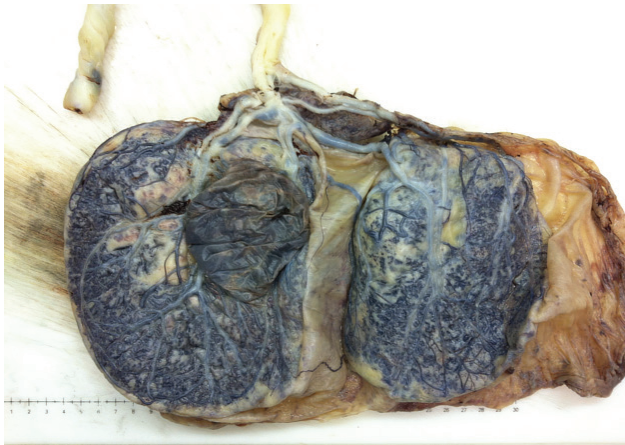
## OBSTETRICS

### *Succenturiate lobes*



#### *Risks:*

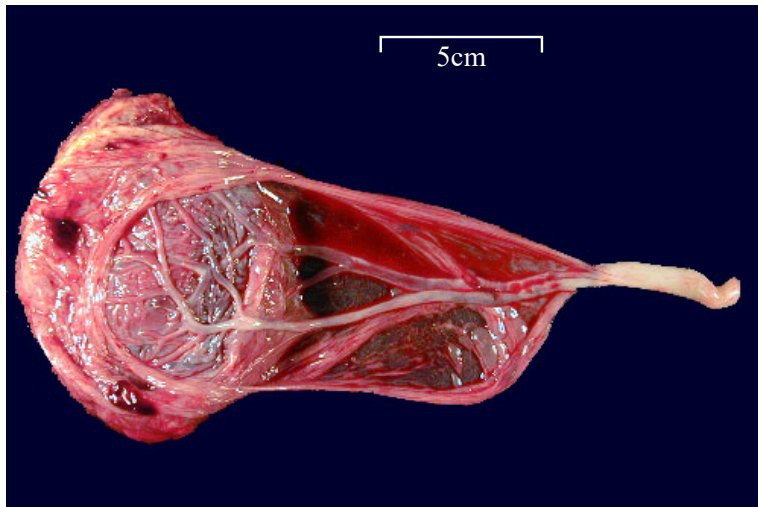
- 1. Vasa previa*
- 2. Sepsis*
- 3. Subinvolution*
- 4. PPH*



*Placenta bilobate*

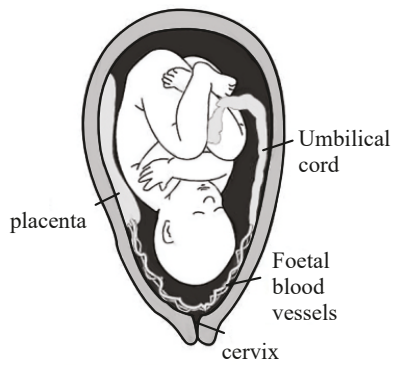


*Velamentous placenta*

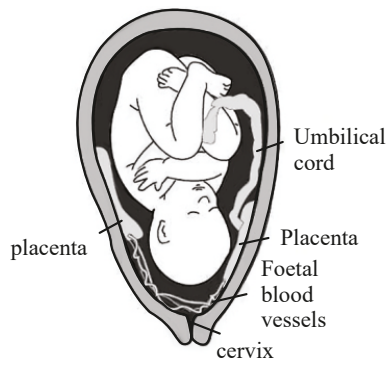


- *Fetal hemorrhage*
- *Fetal death*
- *Vasa Previa*

*Vasa previa*



*Vasa previa with velamentous umbilical cord insertion*



*Vasa previa with Multi-lobed placenta*

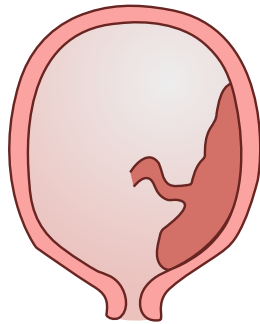
- *Fetal hemorrhage*
- *Succenturiate*
- *Bilobata*
- *Velamentous Placenta*

*DSIS - TUS with doppler*

*Rx - EL LSCS*



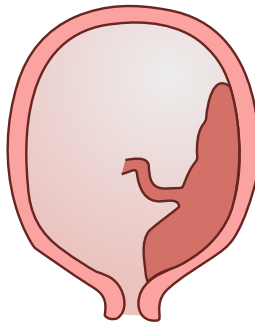
### Placenta Previa



Type I

Low lying

Within 2 cm from internal os

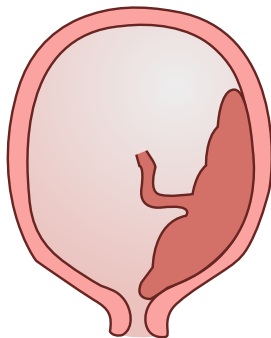


Type II (Marginal)

IIa - anterior

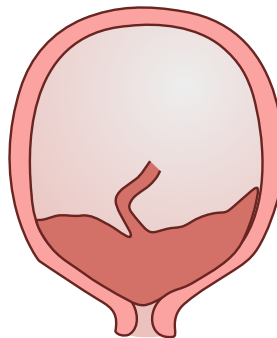
IIb - posterior (Dangerous)

### Low Lying Placenta



Type III

Partial Placenta Previa



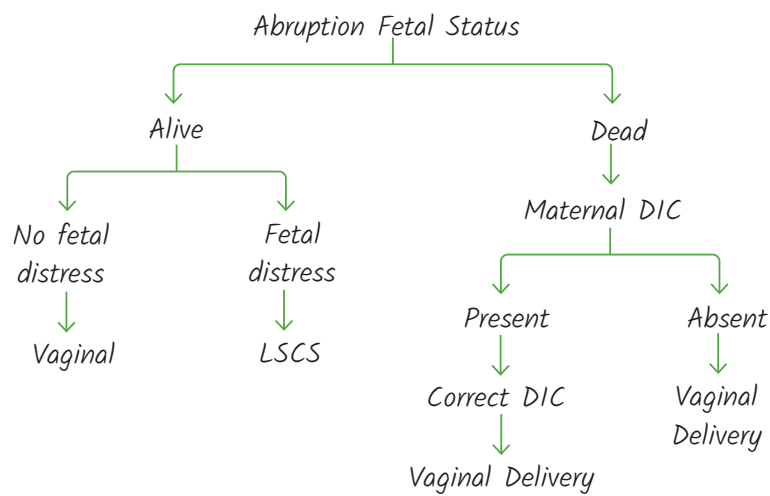
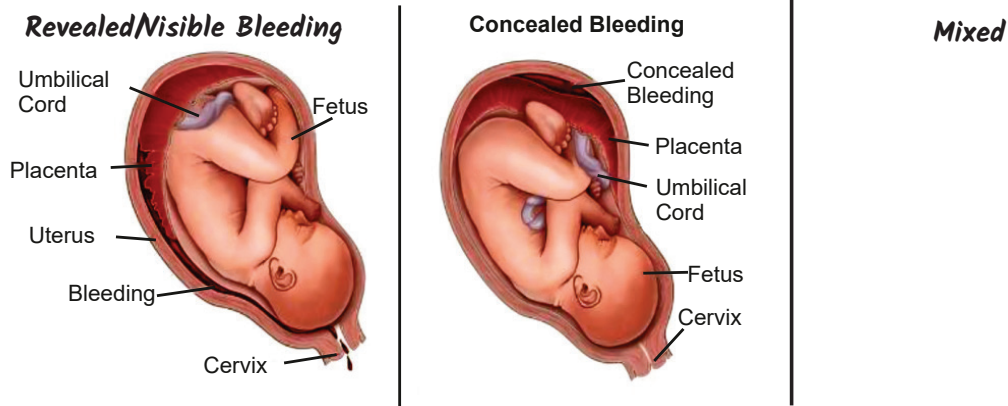
Type IV

Total Placenta Previa

### Management :

< 37 weeks - Macafee and Johnson

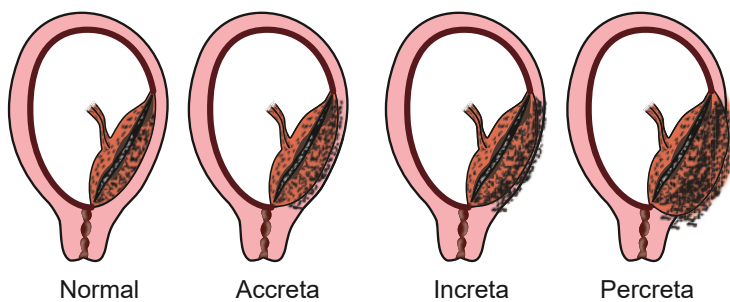
> 37 weeks - EL LSCS



<b>Clinical Features</b>	<b>Placenta Previa</b>	<b>Abruption Placenta</b>
Nature of bleeding	a. Painless, profuse	a. Painful
	b. Bleeding is always revealed	b. Revealed, concealed, or usually mixed
	c. Periodic	c. Progressive
General condition and anemia	Proportional to visible blood loss	Out of proportion to the visible blood loss in concealed or mixed variety
Features of preeclampsia	Unrelated	Very likely to be present
Height of uterus	Proportionate height	May be disproportionately enlarged in concealed type
Feel of uterus	Soft and relaxed	Tonically contracted uterus
Malpresentation	Malpresentation is common (breech, transverse lie). The head is high floating	Unrelated, the head may be engaged
Placentography	Placenta in lower segment	Placenta in upper segment
Tocolysis	Can be given	Never
Wait and watch	Can be done	Never
Delivery	LSCS	LSCS or vaginal delivery
DIC	Less common	More common

- Q. A primigravida presents to casualty at 35 weeks gestation with acute pain abdomen for 2 hours, vaginal bleeding and decreased fetal movements. She should be managed by:
- Immediate cesarean section
  - Immediate induction of labour
  - Tocolytic therapy
  - Magnesium sulphate therapy
- Q. A lady with 35 weeks pregnancy, presented with bleeding per vagina. Investigation shows severe degree of placenta previa. The treatment is:
- Immediate Caesarean section
  - Blood transfusion
  - Conservative
  - Medical induction of labour

### Morbidly Adherent Placenta/PAS



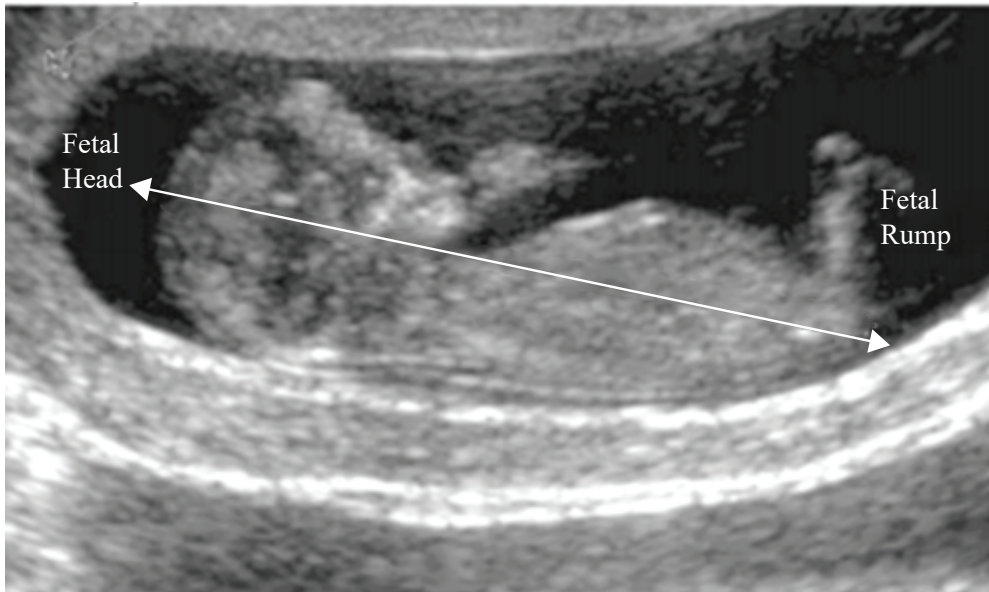
Absence of Nitabuchs fibrinoid layer/decidua basalis  
 ↓  
 Cause - trauma to uterine wall  
 ↓  
 Rx - Classical C - section  
 ↓  
 Fetal extraction  
 ↓  
 Cesarean hysterectomy

### Pregnancy and Antenatal Care

- Q. All of the following can be used for determining EOD of delivery in IVF pregnancy except ?
- From the day of oocyte retrieval +266 days
  - From day 3 of embryo transfer + 263 days
  - From day 5 of embryo transfer + 261 days
  - From LMP + 9 months + 7 days

*For irregular cycles*

- *First trimester*



Q. *A mid aged women came to OPD with a twin pregnancy. She already had 2 first trimester abortion and she has a 3-year-old female child who was born at the end of ninth month of gestation. Which of the following is her accurate representation?*

*G=gravid, P = para*

- a. *G4P1L1 A3*
- b. *G5P1L1A2*
- c. *G4P1L1A2*
- d. *G5P0L1A2*

**Preterm** <37 weeks

**Early term** 37 - 38 weeks +6 days

**Mid term** 39 - 40+ 6 days

**Late term** 41 - 42 weeks

**Four Trimesters :**

1st trimester - upto 14 weeks

2nd trimester - 14 - 28 weeks

3rd trimester - 28 - 42 weeks

4th trimester - post delivery 12 weeks



## Preterm Labour

### Diagnostic Criteria :

	Early preterm	Late preterm
	< 34 weeks	34 - 37 weeks

4 contractions in 20 mins / 8 contractions in 60 min + cx > 2 cm dilated 80% effaced

### Predictor

On TVS cervical length < 2.5 cm 16 - 24 weeks of gestation

Fetal fibrinogen > 50 ng/ml between 24 - 34 weeks

### Prevention

Cerclage - McDonald cerclage

Micronised progesterone

### Management

All patients high vaginal swab for group b streptococcus

Positive inj benzyl penicillin the onset of labour

< 34 weeks

Steroids

Tocolysis

MgSO<sub>4</sub> for neuroprotection of fetus

> 34 weeks

Delivery

Can consider steroids  
upto  $\geq$  6 weeks

### Steroids:

Inj Dexamethasone 6 mg 4 doses 12 hours apart IM

Inj Betamethasone 12 mg 2 doses 24 hours apart IM

Tocolysis of choice - Nifedipine

Tocolysis of choice in heart disease - Atosiban

Max SE to fetus - indomethacin

Max SE to mother - beta adrenergics

**Postterm labour**

42 weeks

10L at 41 weeks

**Bishops Score :**

	0	1	2	3
Dilatation	Closed	1 - 2	3 - 4	> 5
Length	4	3 - 4	1 - 2	0 cm
Position	Posterior	Mid	Anterior	
Consistency	Firm	Medium	Soft	
Station	- 3	- 2	0, - 1	+ 1, + 2

**Folic acid**

Start 3 months	1 month prior
Prophylactic	Therapeutic
India 500 micro gm / day	5 mg / day
WHO 400 micro gm / day	4 mg / day
Upto end of first trimester	Previous NTD
	Family h/o NTD
	Patient on anti-epileptic
	Sickle cell anaemia

**2nd trimester Iron :** 60 mg elemental iron + 500 micro mg of folic acid for 180 days post partum

**Calcium :**

**Vaccination :**

2 doses td 4 weeks apart

First dose at first visit

Optional - tdap

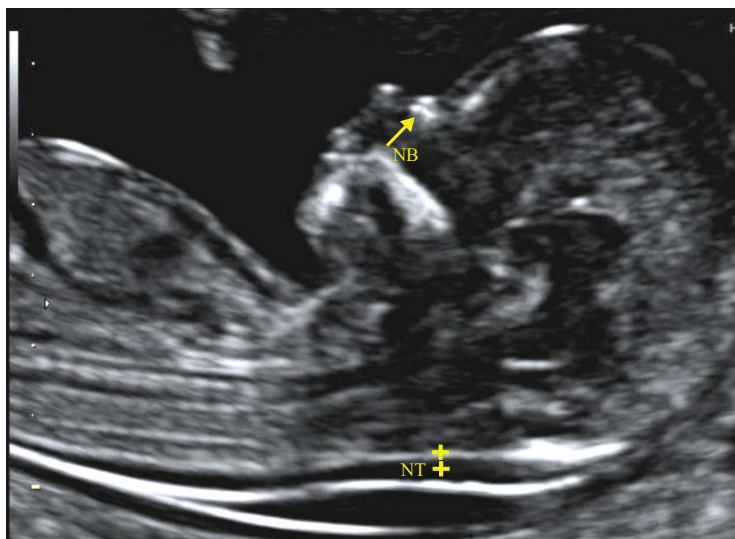
flu



**Aneuploidy screening**

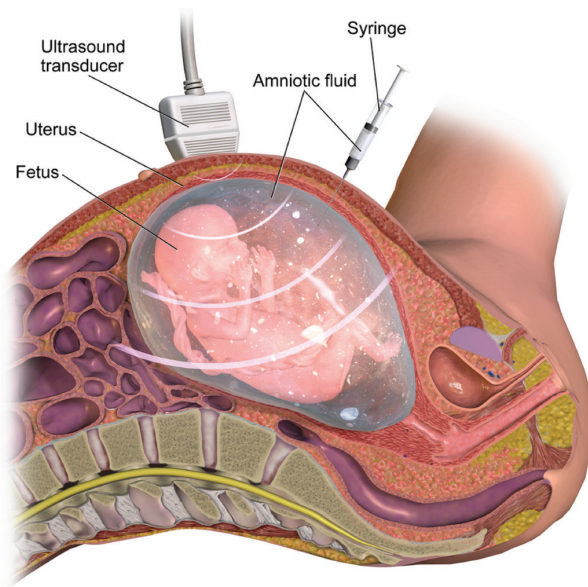
<b>First trimester</b>	11 to 14 weeks
<b>Double marker</b>	↑ hcg + PAPPA
<b>Combined screening method</b>	↑ hcg + PAPPA + NT scan

Nuchal translucency scan - 11 - 14 weeks of gestation when CRL is 45 - 84 mm



NT < 3 mm - normal  
 NT ≥ 3 mm - mc aneuploidy  
 Increased NT - Down's, Turners Syndrome  
 M/c congenital malformation - CVS  
 2nd trimester nuchal fold thickness 6 mm

<b>Second trimester</b>	15-20weeks			
<b>Triple marker</b>	↑ hcg	Unconjugated estriol	AFP	
<b>Quadruple marker</b>	↑ hcg	Unconjugated estriol	Afp	Inhibin A



**Confirmatory test :**

*Amniocentesis :*

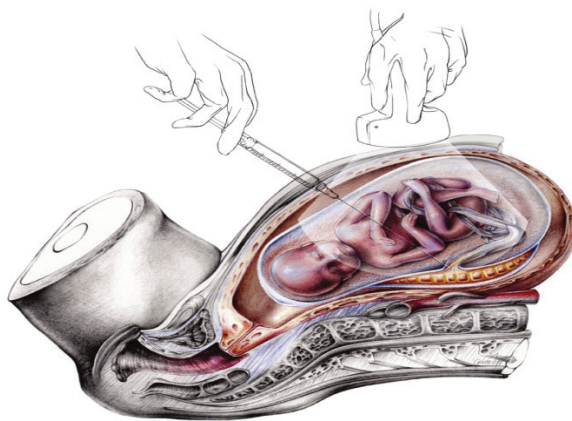
*15 - 20 weeks*

*Amniocytes*

*FISH results within 48 hours*

*Culture results 1 week*

*Abortion - < 0.5 %*



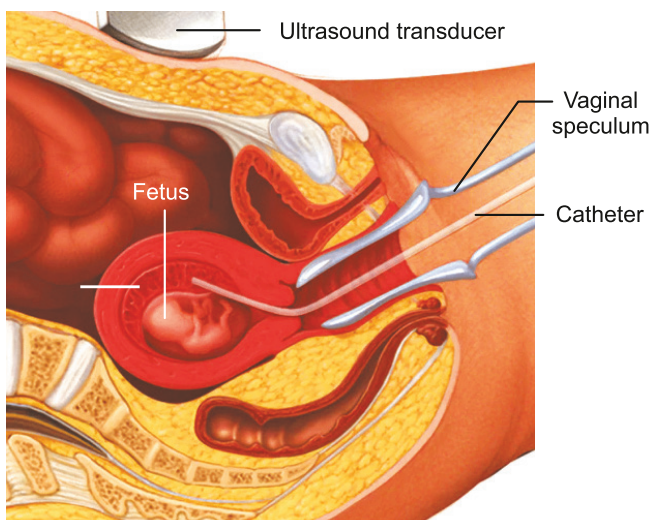
**Cordocentesis :**

*18 - 20 weeks*

*Fetal WBC*

*Culture within 48 hours*

*Abortion - 2- 3 %*



**Chorionic villous sampling:**

*Trophoblasts for kary*

*11 - 13 weeks*

*Culture ? 1 week*

*MC abortion 0.5 - 1 %*

*Most specific - oromandibular defect,  
limb reduction defect*



- Q. *What is the optimum method of screening for chromosomal abnormality in a pregnancy at 13 weeks of gestation?*
- a. *Amniocentesis*
  - b. *Combined screening test*
  - c. *Non-invasive prenatal testing*
  - d. *Nuchal translucency measurement*
  - e. *Quadruple test*

**Miscarriage**

- It is the expulsion or extraction of an embryo or fetus weighing 500gms or less when it is not capable of independent survival.(WHO)

M/C cause in first trimester Euploidy and Aneuploidy,

M/C Aneuploidy : Autosomal Trisomy 16

Most specific : Turner's Syndrome

**M/c cause of second trimester :** Anatomical abnormalities

**M/c cause of recurrent abortion :** Idiopathic

Mc cause of recurrent abortion in 1st trimester - endocrine abnormalities

Mc cause of recurrent abortion in 2nd trimester - uterine abnormalities

Single mc cause for RPL - APLA

**Most common cause of abortion:**

- Ovofetal factor
- Maternal hypoxia
- Uterine fibroid
- Cervical incompetence

**Antiphospholipid Syndrome Criteria**

1 Clinical + 1 Lab Criteria

Clinical Criteria	Lab Criteria
1. Vascular Thrombosis	1. Anti-Cardiolipin IgG / IgM
Pregnancy Morbidity: Obstetric Criteria (2023) <ul style="list-style-type: none"> <li>• ≥ 3 consecutive abortion &lt; 16 weeks</li> <li>• Death of normal fetus between 16 - 34 weeks in the absence of PE/PI</li> <li>• Preterm labour &lt; 34 in view of severe PE or PI</li> <li>• Preterm labour &lt; 34 weeks in view of severe PE and PI</li> </ul>	Anti-beta-2 glycoprotein I (GPI) Lupus anticoagulant (LAC) medium to high titer at least X 2 times 12 wks apart



**Types of abortion :** Amenorrhea + Bleeding per vaginum + pain abdomen


**Missed miscarriage**

**Sonographic Findings**

- CRL > 7 mm and no heartbeat
- MSD > 25 mm and no embryo
- An initial US scan shows a gestational sac with yolk sac, and after > 11 days no embryo with a heartbeat is seen
- An initial US scan shows a gestational sac without a yolk sac, and after > 2 weeks no embryo with a heartbeat is seen

**Medical termination of pregnancy**




- The MTP act was passed in August 1971 and came into effect from April 1972 and revised in 1975
- REVISED bill 2020
- Mtp (amendment) act 2021 came into effect from March 2021
- MTP upto 24 weeks eugenics, humanitarian, change in marital status
- For contraception failure - MTP upto 20 weeks
- No upper limit of termination for lethal anomalies
- < 20 weeks - 1 doctor opinion
- 20 - 24 weeks - 2 doctor opinion
- Married women replaced by women
- Privacy will be maintained
- Only women consent is enough
- < 18 years - inform police guardian consent

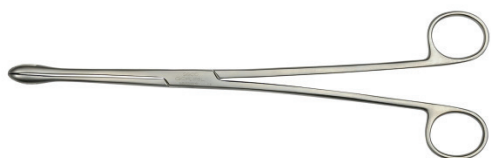**New MTP bill**

**Methods of termination**

<b>First Trimester</b>
<p><i>Mifepristone/Misoprostol</i></p> <p><i>Mifepristone, 200mg orally, and after 48 hr provide Misoprostol 800 µgm</i></p> <p><i>Misoprostol Alone</i></p> <p><i>800 µgm and then may repeat every 3 hr upto 3 total doses</i></p>
<b>Second Trimester</b>
<p><b>Mifepristone/Misoprostol</b></p> <p><i>Mifepristone, 200mg orally, and after 24hr provide Misoprostol 400µg every 3 hr up to 5 total doses</i></p> <p><b>Misoprostol Alone</b></p> <p><i>400µg every 3hr upto 5 total doses</i></p> <p><b>Dinoprostone</b></p> <p><i>20 mg vaginal suppository every 4 hr</i></p> <p><b>Concentrated Oxytocin</b></p> <p><i>Intraamniotic instillation of hypertonic urea and normal saline</i></p> <p><i>Extraamniotic instillation of ethacrydine lactate and prostaglandins</i></p> <p><i>Upto 9 weeks - Mifipristone + misoprostol</i></p> <p><i>9 - 12 weeks - manual vaccum aspiration/suction and evacuation</i></p> <p><i>&gt; 12 weeks - misoprostol</i></p>

### Surgical methods

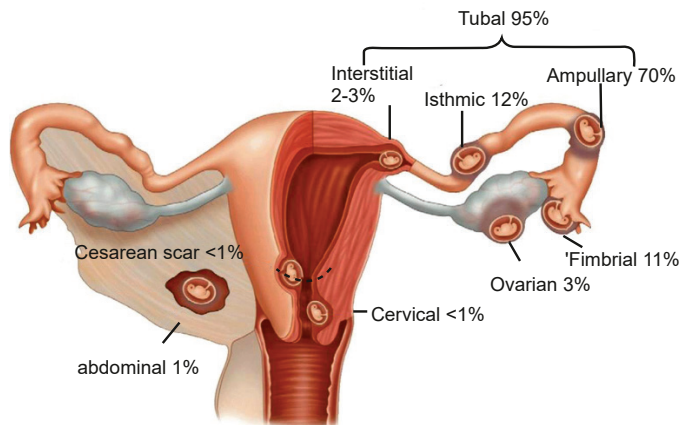
Menstrual regulation syringe	Manual vacuum aspiration syringe	Suction and evacuation
 <p>50 ml syringe with 6 mm Karman cannula</p>	 <p>Upto 12 weeks mild sedation 60 ml syringe with double valve piston to create a negative pressure of 660 mm Hg</p>	 <p>Upto 12 weeks</p>



**Q.** A 32 year old women presents for her 12 week scan. She has been pregnant once before but had a 1<sup>st</sup> trimester miscarriage. She reports no problems with this pregnancy and has had no vaginal bleeding or spotting. The scan shows no fetal cardiac activity and a small gestational sac. What is the likely diagnosis?

- Recurrent Miscarriage
- Complete Miscarriage
- Missed Miscarriage
- Inevitable Miscarriage

**Ectopic pregnancy**



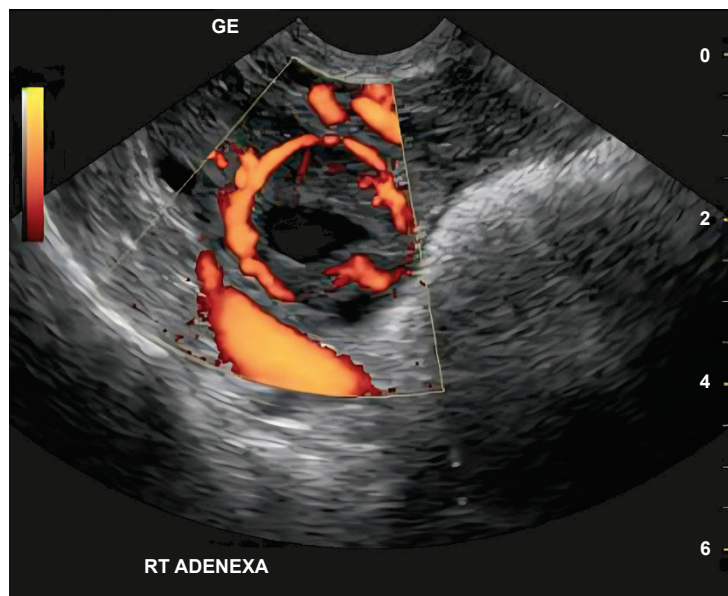*Mc site rupture and earliest to rupture isthmus (6 weeks)*

*Last to rupture - interstitial 42 weeks*

*Mc ectopic - PID > Previous ectopic*

*Highest risk - previous tubal surgeries*

**Diagnosis of ectopic pregnancy (RING OF FIRE APPEARANCE)**



*IOC - TVS*

*Pseudosac in uterus*

*g.sac in f.tube*



*Bagel sign*

*Doppler - Ring of fire appearance*

**Gold standard - laparoscopy**

*Rupture ectopic Amenorrhea → pain → Bleeding per vaginum*

*O/E - Patient in shock*

*PA - Hemoperitoneum*

*PV - Cervical motion tenderness +ve*

*Rx - immediate laparotomy - salpingectomy*

## PYQ

Expectant Management	Medical Management	Surgical Management
Not doing anything, Resolves by itself		
Follow-up	Methotrexate	
No / mild sac pain size < 3.5 cm		Significant pain GS>3.5 cm with FHR $\beta$ -hCG > 5000 IU/L
FHR absent ( $\beta$ ) - hcg < 1000 iu/L	Methotrexate 50 mg/m <sup>2</sup> (single dose is preferred) Check for $\beta$ -hCG- Day 2,4&7	<ul style="list-style-type: none"> <li>• Salpingectomy (Complete Removal)</li> <li>• Salpingotomy (incision → remove → suture)</li> <li>• Salpingostomy (Incise → remove → kept open)</li> </ul>
	<ul style="list-style-type: none"> <li>• Drop in 15% of <math>\beta</math>-hCG from previous value, she is responding</li> <li>• Less than 15% drop → Repeat (Maximum 3 doses) → Surgery</li> </ul>	Most preferred: Salpingectomy If only 1 tube → Salpingotomy or Salpingostomy (Recurrence is high)
If $\beta$ -hCG is 1500-5000 IU/L, Either medical or surgical management can be offered		

## Abdominal Pregnancy

Criteria for diagnosis: Studdiford's criteria

## Ovarian Pregnancy

Criteria for diagnosis-Spiegelberg criteria

## Cervical Pregnancy

- **Criteria for diagnosis-** Rubin's criteria or Palmaan McEllen criteria. These days USG criteria is used:
  - **MC symptom** - Painless vaginal bleeding
- Q. A 28-year-old presents in her first pregnancy at 16 weeks' gestation with severe hyperemesis. Her blood pressure is 150/96 mmHg with 3of proteinuria. Her booking blood pressure is noted to be 110/70 mmHg. Abdominal examination demonstrates that the symphysis-fundus height is equivalent to 22 cm what is the diagnosis?
- Inevitable miscarriage
  - Complete miscarriage
  - Hydatid form mole
  - Fibroid uterus

**Gestational Trophoblastic Disease**

**Gestational Trophoblastic Disease (GTD)** encompasses a spectrum of proliferative abnormalities of trophoblasts associated with pregnancy.



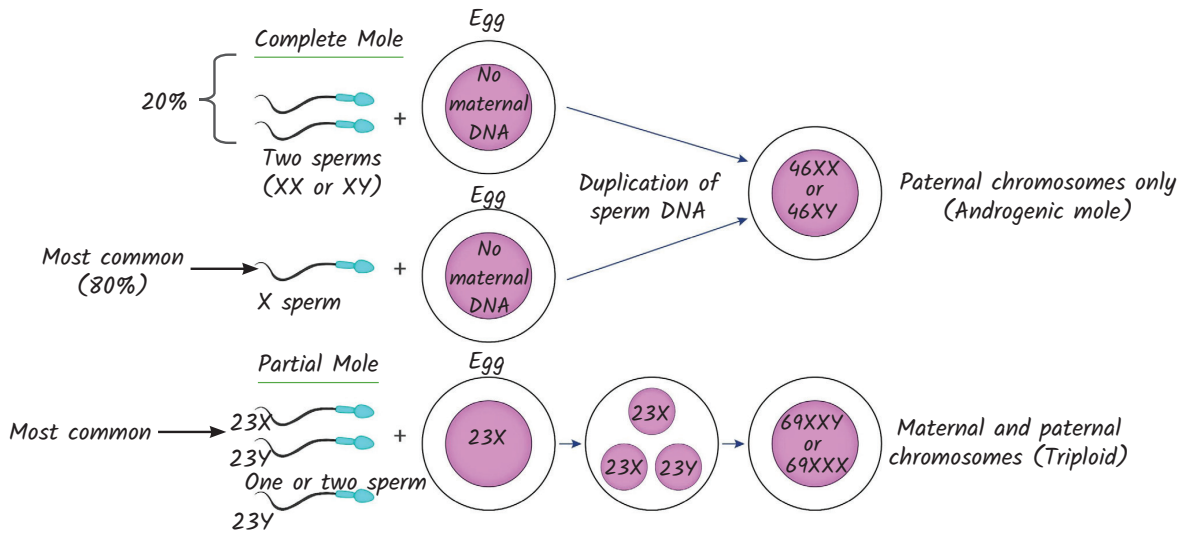
Complete mole  
Partial mole

**Complete Mole**

**Clp** : Amenorrhea → Bleeding per vaginum → pain abdo

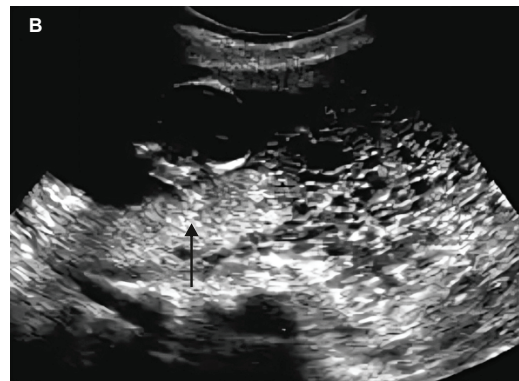
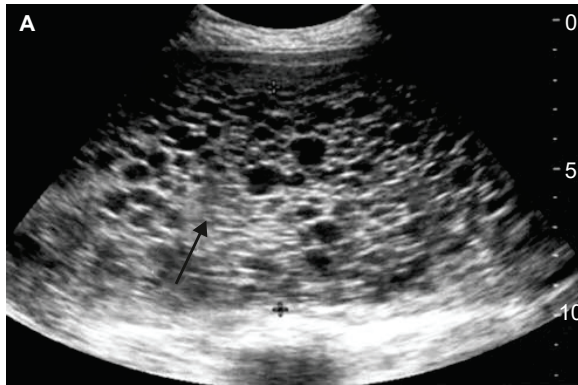
**O/e** :

	Patient stable	Partial mole
PA	Complete mole ut > pog soft doughy	Partial mole ut ≤ pog fetus +ve





10C



**MANAGEMENT**

*Contraceptive of choice being combined oral pills.*

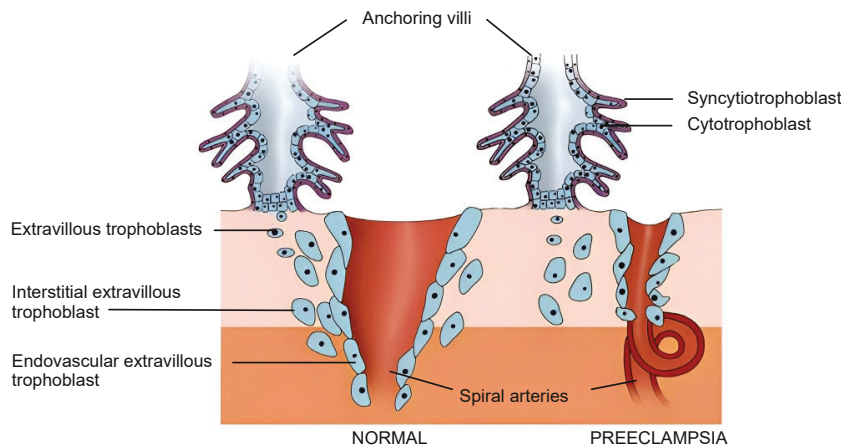
**Q.** *A 32-YEAR-OLD had blood pressure of 150 /100 at 32 weeks of gestation, there is headache or blurring of vision, proteinuria of 3 +. Her bp before pregnancy is 150 /90 mmhg. What is the diagnosis?*

- a. Chronic hypertension
- b. Mild preeclampsia
- c. Severe preeclampsia
- d. Chronic hypertension with superimposed preeclampsia

*Failure of secondary (2°) wave of trophoblastic invasion*

*Narrow spiral artery  
high resistance  
low velocity*

*UPI - Fetal hypoxia*



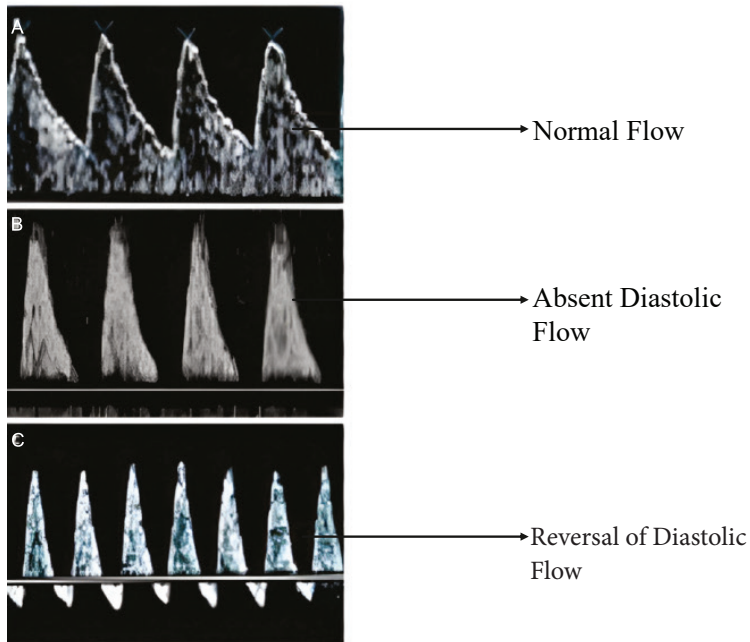
*VC  
Sf[t]  
thromboxane  
A2  
endoglins*

*VC  
NO  
Plgf  
prostacyclin*

*Htn  
Headache  
Vomitting  
Reversible  
blurring of vision  
Epigastric pain  
Oliguria*



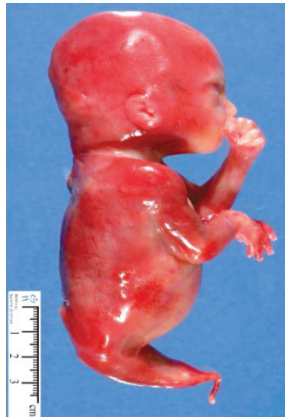## Umbilical Artery Velocimetry



- Q.** A 40-year-old woman presents at 32 weeks of gestation in her first pregnancy with a blood pressure of 143/90 mmHg. Blood pressure at the beginning of her pregnancy was 100/60 mmHg. Quantitative test is indicated, No proteinuria. She feels well, with no headaches or visual disturbance.
- Do not admit patient to hospital or treat hypertension; no indication for blood tests but monitor blood pressure weekly.
  - Treat hypertension with oral anti-hypertensives, take blood pressure at least twice per week, take blood tests.
  - Do not admit patient to hospital, treat hypertension with oral anti-hypertensives, take blood pressure at least twice per week, no need for blood tests.
  - Give iv  $MgSO_4$
- Q.** A pregnant lady at 32 weeks gestation period presents with a BP of 160/110 mm Hg, Proteinuria with Retinal Haemorrhage What is the Definitive Management of choice in this case?
- Ritodrine
  - Nifedipine
  - Magnesium sulphates
  - Termination of pregnancy

**Diabetes in Pregnancy and Shoulder Dystocia**

**Congenital Malformation in Diabetic Females**



Mc congenital malformation with overt DM - CVS > NTD

Mc CVS malformation - VSD

Lc CVS malformation - TOF

Most specific CVS. malformation - TGA

Most specific anomaly - Sacral agenesis

Overt DM Fbs > 126 mg/dl

Ppbs > 200 mg/dl

HbA1c > 6.5

**GDM** : At first visit, repeat at 24 - 28 weeks

	Fasting	1 hr	2 hr
<b>75 gms OGTT</b>	< 92	< 180	< 153
75 GMS OGCT -> DIPSI	measure blood sugar after 24 hours		

**Weight > 4 kg : lscs**

< 120 - N

**TIMING of delivery :**

121 - 139 - IGT

**GDM controlled on diet :** 40 - 40 weeks + 6 days

> 140 - GDM

**GDM/overt DM controlled on medication :** 39 - 39 weeks + 6 days

> 200 - overt DM

**GDM/overt DM poorly controlled on medication :** 37 weeks

**GDM/overt DM uncontrolled on medication :** 34 weeks

**Shoulder dystocia**

- A head-to-body delivery time exceeding 60 sec is used to define shoulder dystocia.
- Often described feature is **the turtle sign** which involves the appearance and retraction of the fetal head (analogous to a turtle withdrawing into its shell) and the erythematous, red puffy face indicative of facial flushing.

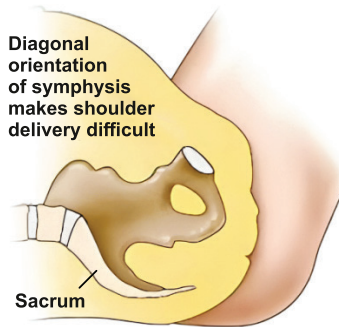
**Management of Shoulder Dystocia**

**CALL FOR HELP** : Bring patient to edge of table, empty bladder, episiotomy

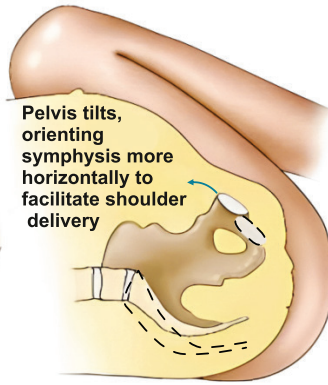
1. **The McRoberts maneuver** : The maneuver consists of removing the legs from the stirrups and sharply flexing them up onto the abdomen.
  - Decreases angle of inclination
  - Pelvis tilts cephalad



Before McRoberts Positioning

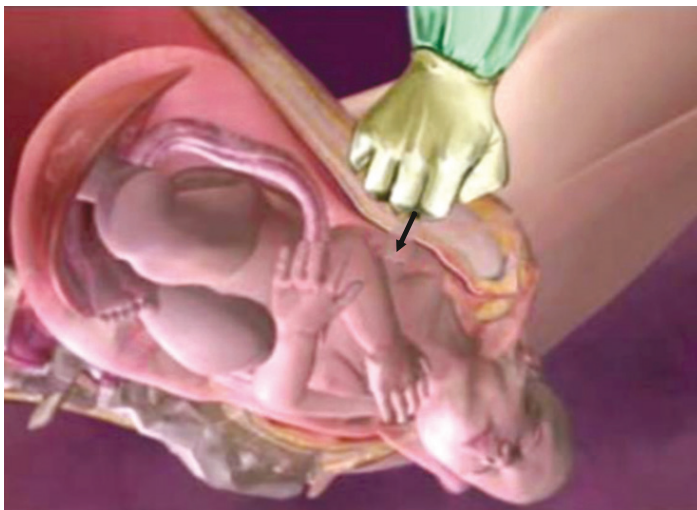


McRoberts Position



*Meralgia paresthesia*

**(2) Supra pubic pressure**




*AOF*

**(3) Rubins**

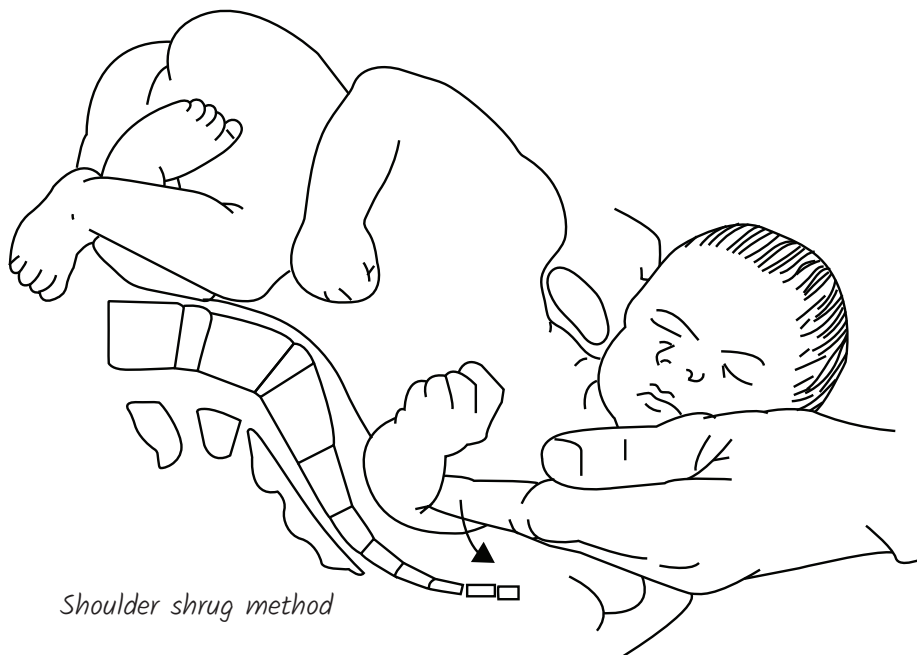
### Wood corkscrew method

- Woods reported that, by progressively rotating the posterior shoulder 180° in a corkscrew fashion, the impacted anterior shoulder could be released. This is frequently referred to as the Woods corkscrew maneuver.

- **Woods corkscrew**



### Posterior arm extraction



**If all the above methods fail : All fours or gaskins position and repeat all**

**Extreme methods :**

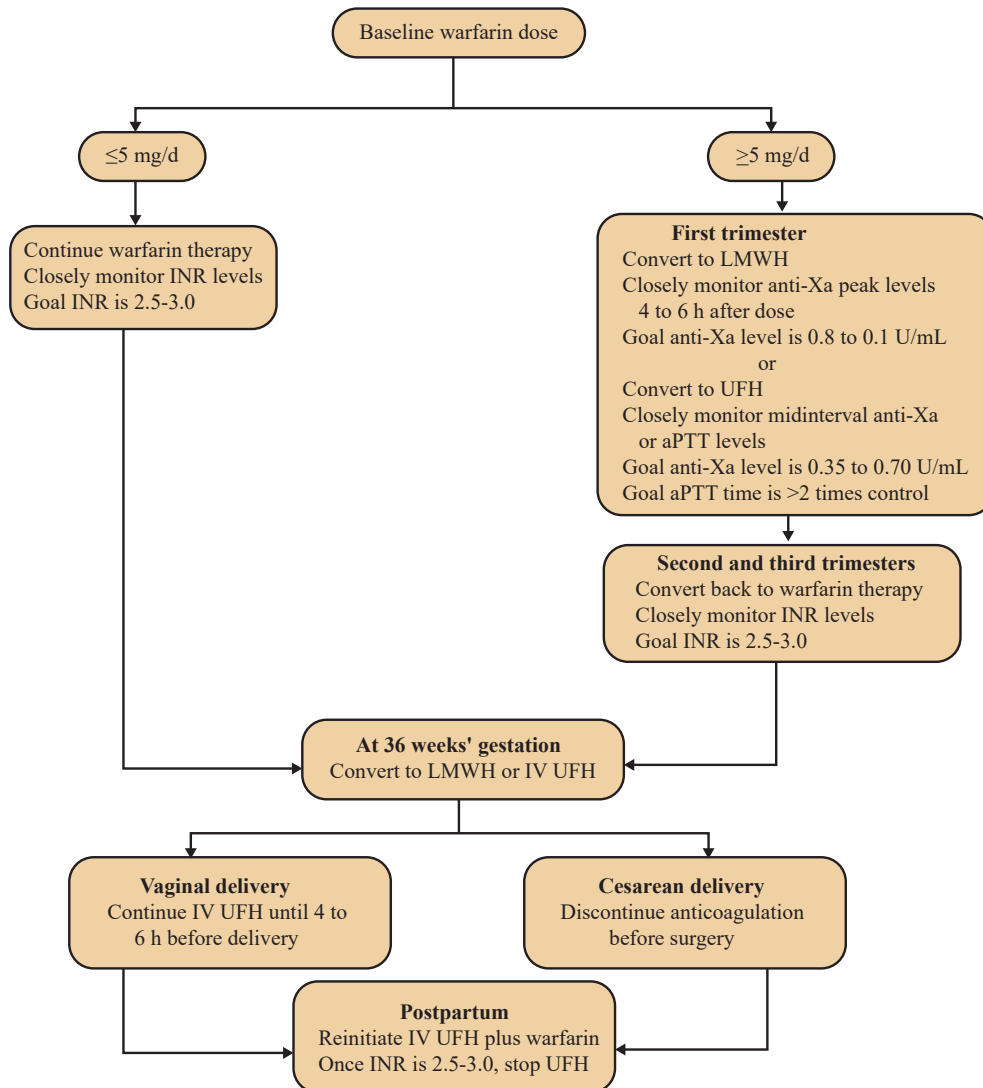
Push the fetus into pelvis - LSCS → Zavanelli

Fetal cleidotomy

Maternal symphysiotomy

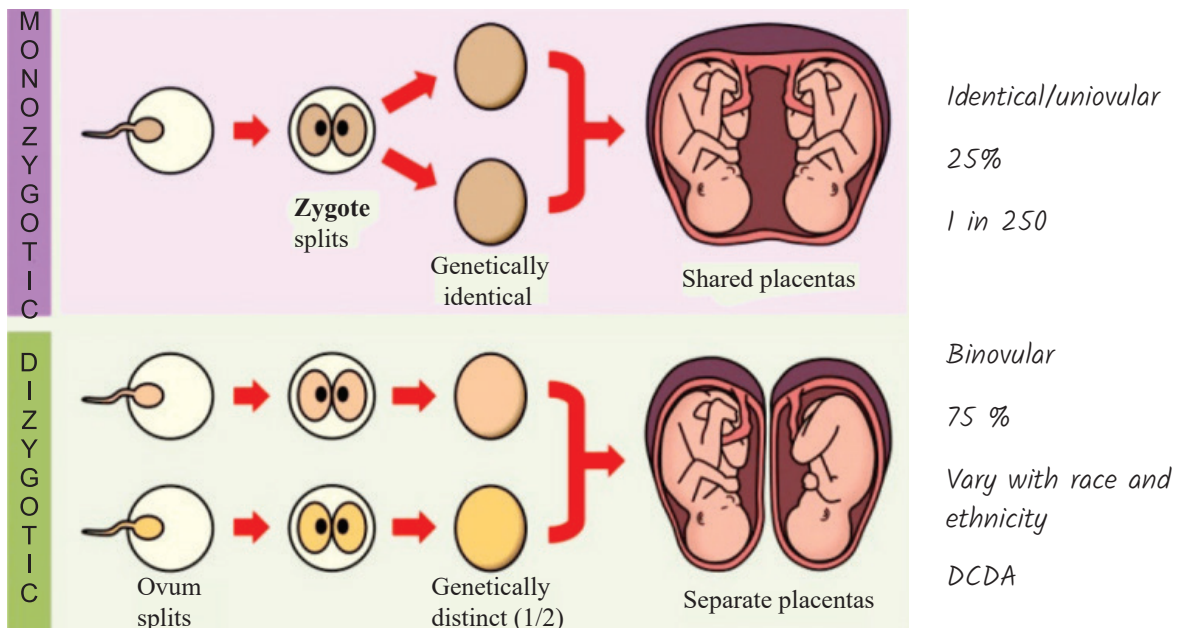
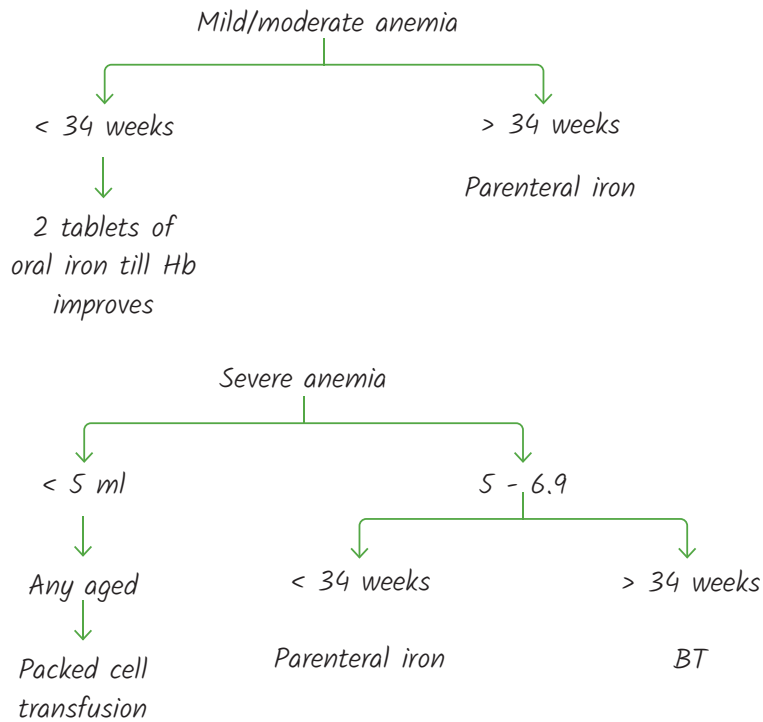


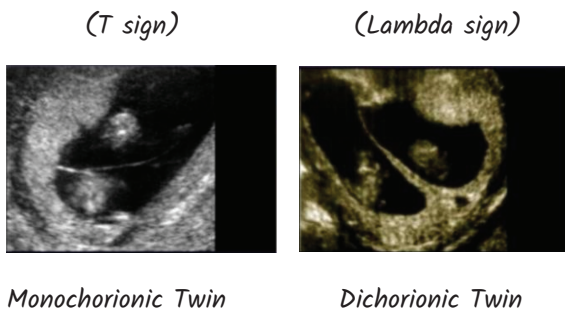
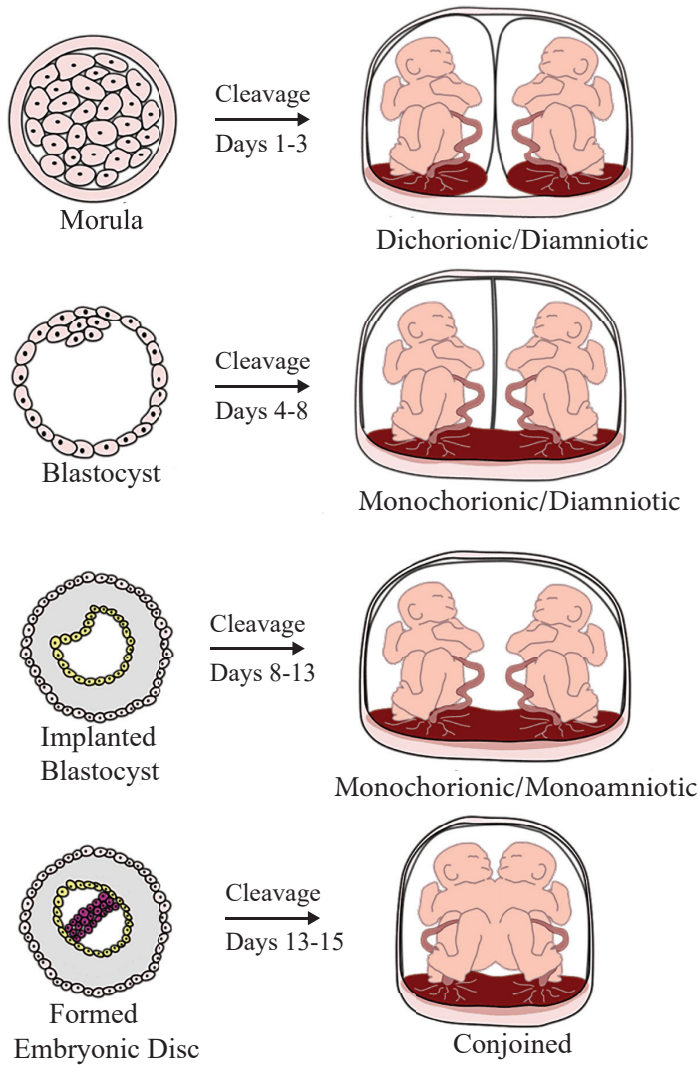
*Pt on prosthetic valves, risk of AF*



**Anemia in pregnancy :**

Anemia	Hb < 11 gm/dl
Mild	Hb 9 - 10.9 gm/dl
Moderate	7 - 9.9 gm/dl
Severe	< 7gm/dl





*Ind LSCS*

*1st twin non cephalic*

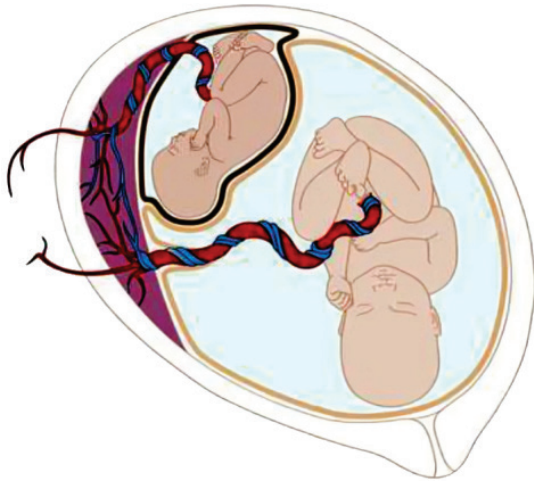
*MCMA*

*Saimese*

*TTTS*

*Triplets by 35 weeks*

*Discordant twin with 2nd twin larger than first*

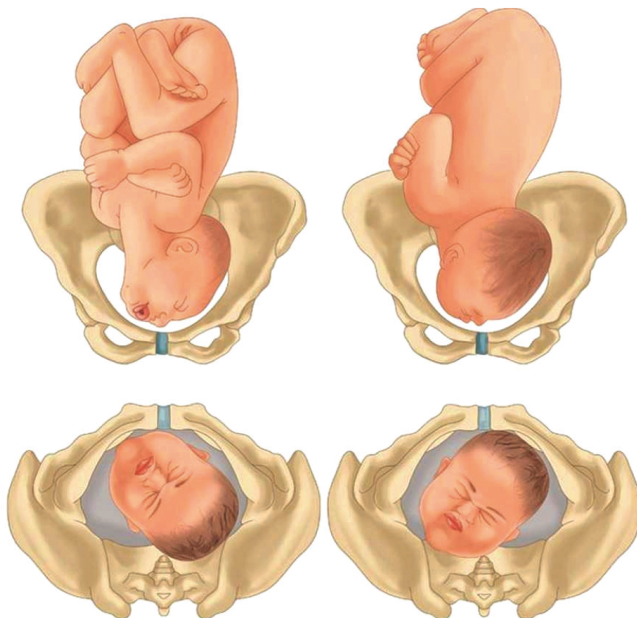


### Management of Labor

#### Time of Delivery

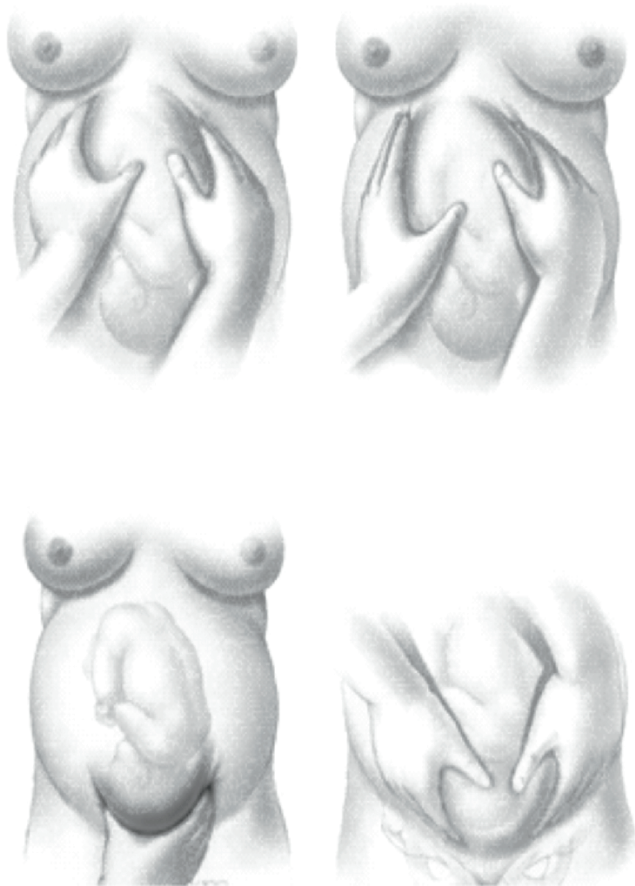
1. Monochorionic monoamniotic twins : Cesarean section at 32-34 weeks after giving corticosteroids.
2. Monochorionic diamniotic : Elective delivery at 36-37 weeks.
3. Dichorionic twins : Elective delivery at 37-38 weeks.
4. Triplet pregnancies : Elective cesarean at 35 weeks after giving corticosteroids.

### Labour

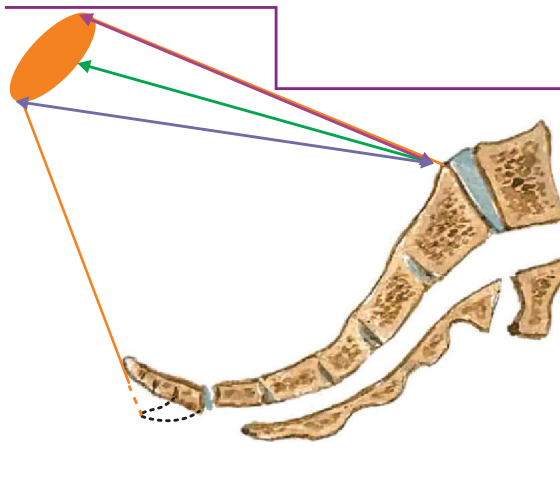
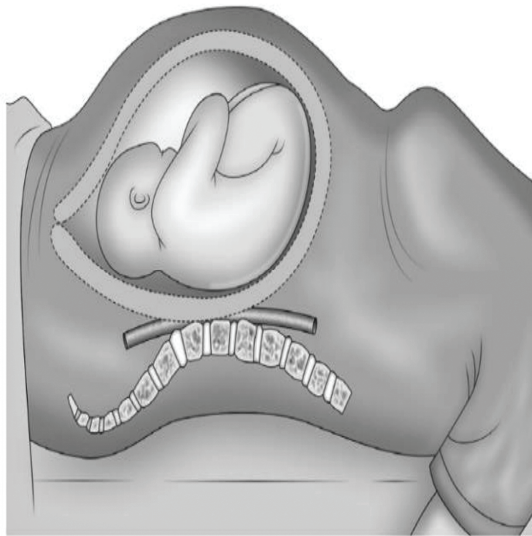




### Leopold Maneuvers



- Q. A pregnant lady was admitted for pregnancy induced hypertension for monitoring and bed rest. In supine position which of the following is a complication of the below representation?
- Abdominal aorta syndrome
  - Supine vena cava syndrome
  - Superior vena cava syndrome
  - Ascending aorta syndrome



Diagonal conjugate - 12 cm

Lower border of PS. to sacral promontory

OC - posterior surface of PS to sacral promontory

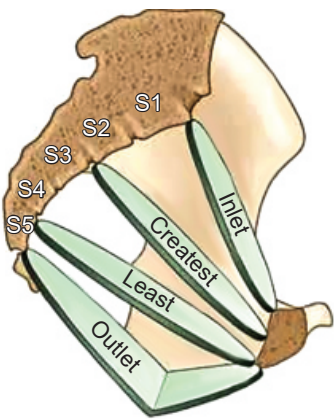
DC - 1.5 - OC - 10.5 cm

Anatomical conjugate

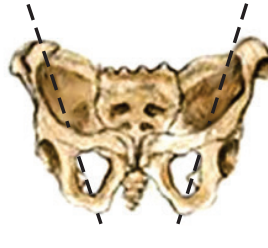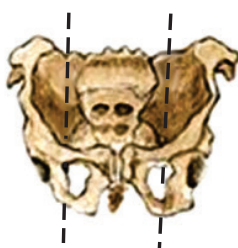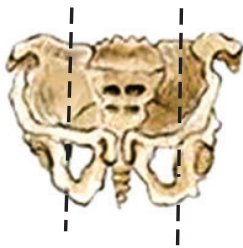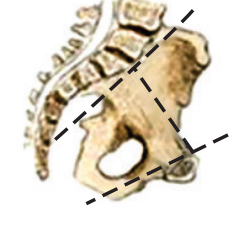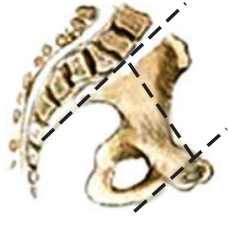
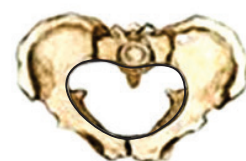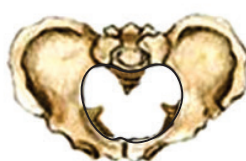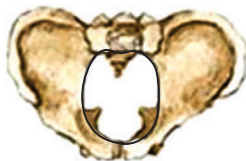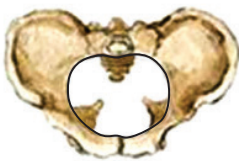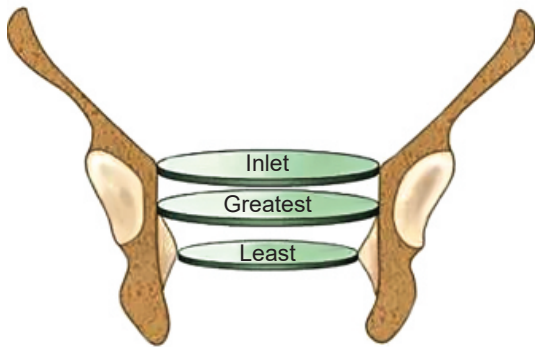
True conjugate - upper border of PS to SP

11 cm

	AP	Oblique	Transverse
Inlet	11cm	12 cm	13 cm
Cavity	12 cm	12 cm	12 cm
Outlet	13 cm	12 cm	11 cm



A. Sagittal section.



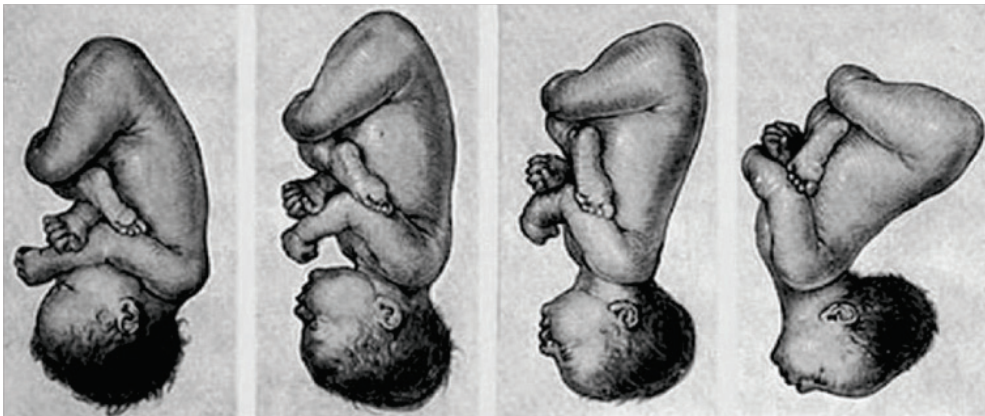
**Q.** A 34 yr old female G2P1L1, previous classical C section, is now having Breech presentation which is confirmed on USG at 34 weeks and the patient insists on normal delivery. What will you do?

- a. Wait for 36 weeks
- b. Plan cesarean section at 37 weeks
- c. Repeat USG after a week and decide
- d. Do vaginal delivery

**Cardinal Movements of Labour**

**They are as follows\*:**

- 1. Engagement\*
- 2. Descent
- 3. Flexion
- 4. Internal rotation\*
- 5. Crowning\*
- 6. Extension\*
- 7. Restitution
- 8. External rotation



A

B

C

D



**Latent phase**

	<b>Average</b>	<b>Prolonged</b>
<i>Primi</i>	10 - 12 hours	≥ 20 hours
<i>Multi</i>	6 - 8 hours	≥ 14 hours

**Active Phase**

**WHO 2018**

	<b>Rate of dilatation</b>	<b>Rate of descent</b>
<i>Primi</i>	1.2 cm/hour	1 cm/hour upto 12 hours
<i>Multi</i>	1.5 cm/hour	2 cm/hour upto 10 hours


*Prolonged Active Phase / Protracted Active Phase*

*Primi < 1.2 cm / hour*

*Multi < 1.5 cm / hour*

*Min < 1 cm / hour*

*PA contraction*



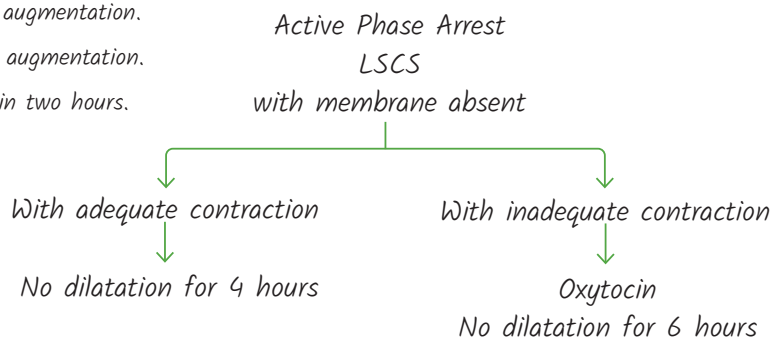
### Prolonged Active Phase

#### Active Phase Arrest

Q. A 28-year-old in her first pregnancy is induced at term plus 10 days. The CTG was normal before induction of labour; she was dilated 6 cm four hours previously and now is dilated 8 cm on vaginal examination. She has uterine contractions at a rate of two every 10 minutes. The CTG shows a baseline rate of 150 bpm, good variability and infrequent shallow variable deceleration.


What is the next most appropriate action?

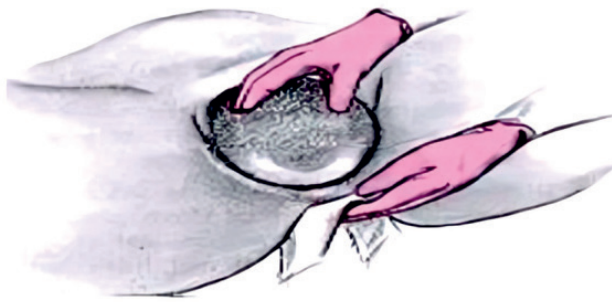- a. Assess in 30 minutes without augmentation.
- b. Assess in two hours without augmentation.
- c. Assess in four hours without augmentation.
- d. Start syntocinon and assess in two hours.



#### The Second Stage

	Average		2nd stage arrest
Primi	1 hours		≥ 3 hours
Multi	30 mins		≥ 2 hours
Ritzgens			





### Active management of third stage of labour

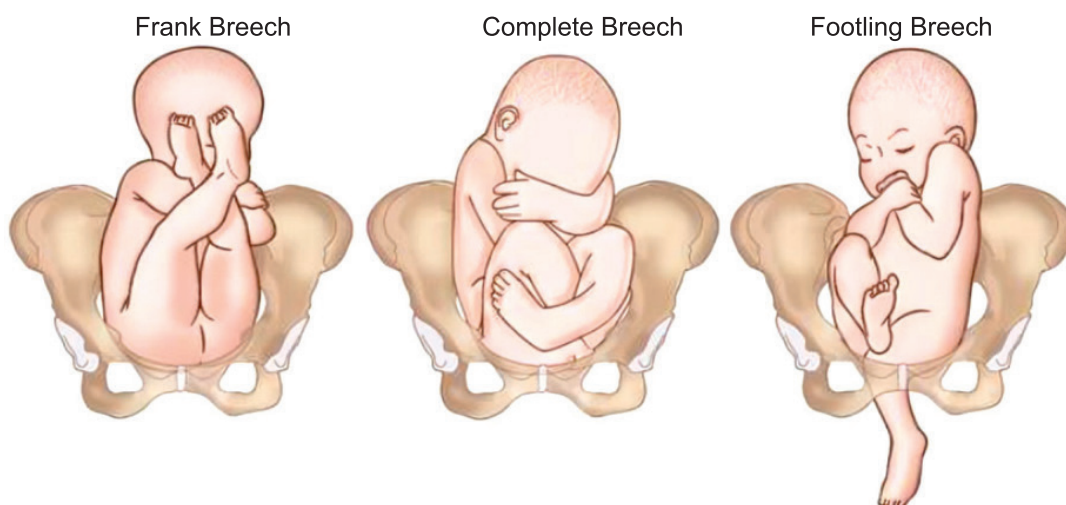
1. Injection oxytocics
  - (i) Injection oxytocin IM/IV 10 IU
  - (ii) Inj. carbetocin 100 micro gm IM
  - (iii) Tab. Misoprostol 400–600 micro gm PR/SL/oral
2. Delayed cord clamping
3. Brandt–Andrew method / Controlled cord traction
4. Intermittent uterine tone assessment

**Q.** A 34-year-old nulliparous woman in the second stage of labour has been pushing for the last two hours and is exhausted. The CTG is normal; the head is 1 cm above the ischial spines, in occipitoanterior position. Which of the following would be the most appropriate action?

- a. Emergency Caesarean section
- b. Increase syntocinon
- c. Perform fetal blood sampling
- d. Trial of forceps in theatre

**Q.** Components of Active Management of the Third Stage of Labour (AMTSL)

- a. Immediate administration of uterotonic drug
- b. Delayed cord clamping
- c. Controlled cord traction
- d. Intermittent uterine tone assessment

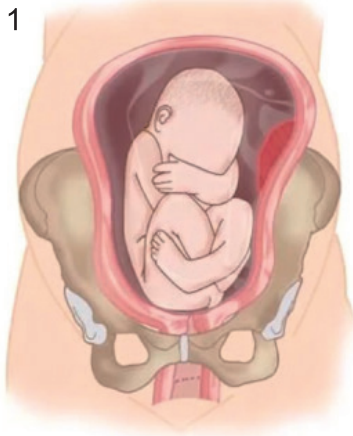

### External Cephalic Version

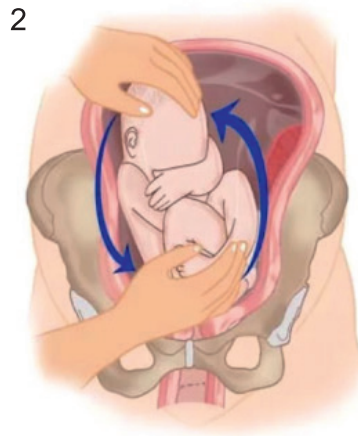
- Success rate 50%

#### Prerequisite:

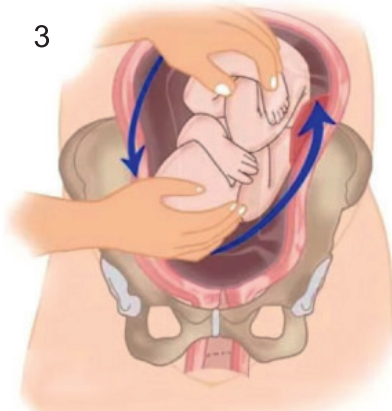
#### External Cephalic Version (ECV)



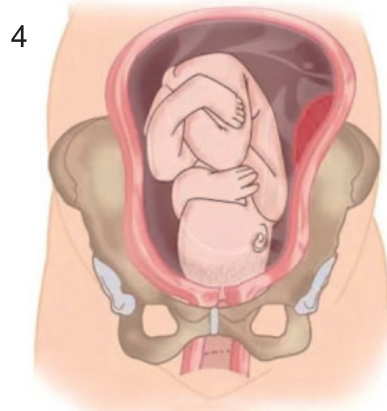
Baby in breech position



Your physician feeling the head and rump of the baby externally



Turning the baby by applying pressure externally



Baby in cephalic presentation, engaged in the pelvis, ready for vaginal delivery



### **Absolute contraindications**

- *It is contraindicated if vaginal delivery is not an option, such as with placenta previa.*
- *Multifetal gestation.*
- **Relative contraindications** are
  - *Early labor*
  - *Oligohydramnios*
  - *Rupture of membranes*
  - *Known nuchal cord*
  - *Structural uterine abnormalities*
  - *Fetal growth restriction*
  - *Prior abruption*

### **Complications of ECV**

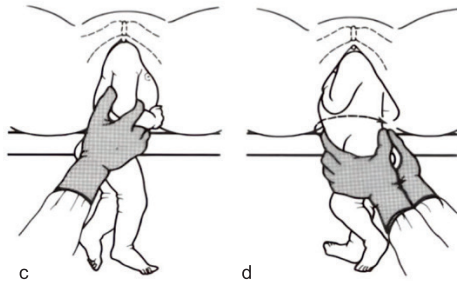
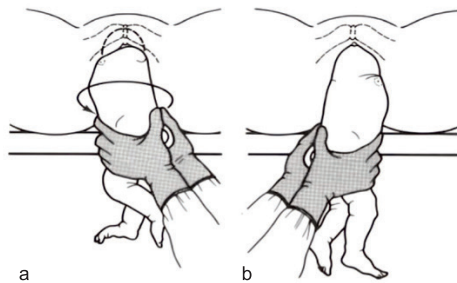
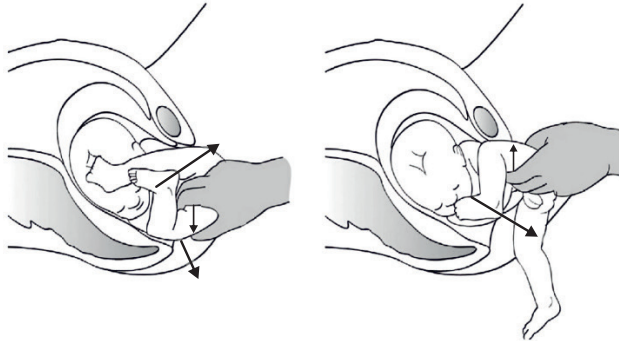
1. *Fetal distress*
2. *IUFD*
3. *Preterm labor*
4. *Abruption*
5. *Cord entanglement*
6. *Uterine rupture*

### **Indications for Cesarean Section in Breech Presentation**

- *Lack of operator experience*
- *Patient request for cesarean delivery*
- *Large fetus: > 3800 to 4000 g*
- *Apparently healthy and viable preterm fetus either with active labor or with indicated delivery*
- *Severe fetal-growth restriction*
- *Fetal anomaly incompatible with vaginal delivery*
- *Prior perinatal death or neonatal birth trauma*
- *Incomplete or footling breech presentation*
- *Hyperextended head*
- *Pelvic contraction or unfavourable pelvic shape determined clinically or with pelvimetry*
- *Prior cesarean delivery*

**Assisted Breech Delivery**

**Pinards Method - arrested lower limb**



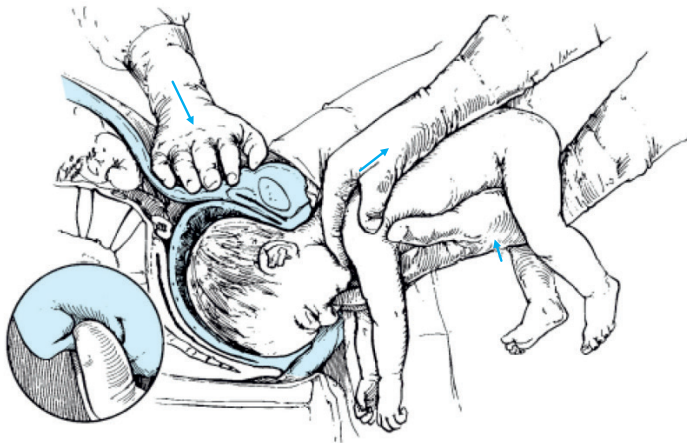
*Extended arm / Nuchal displacement*



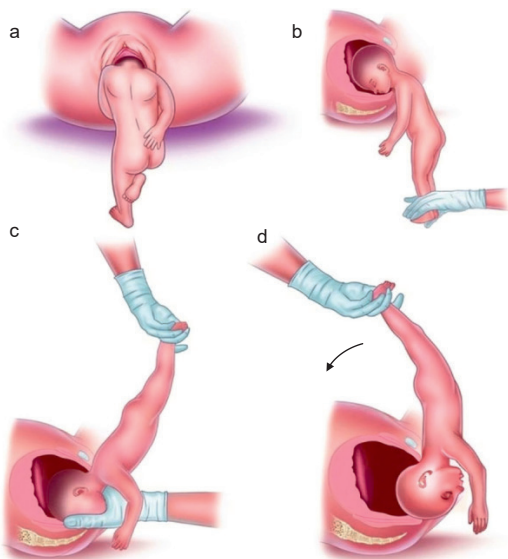
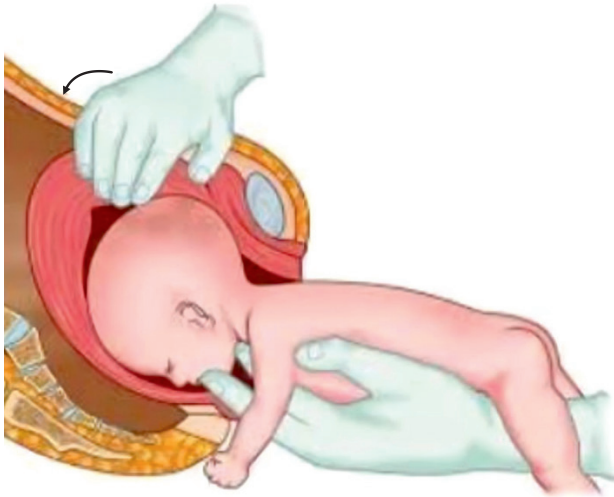
*Loveset method*



*Mauriceau-Smellie-Veit Maneuver*



*Wigard martin method*





- *Uterine and ovarian artery ligation: It is easier than internal iliac artery ligation and can be tried as the first resort (before B lynch suture became popular)*

## PPH WHO 2025

### Definition :

- ACOG definition: Bleeding which causes Hct to decrease by 10% or the need of blood transfusion after delivery.
- Post Partum Hemorrhage (PPH) objectively measured blood loss threshold of  $\geq 300$  ml with any abnormal haemodynamic sign (pulse  $>100$  bpm, shock index  $>1$ , systolic blood pressure  $<100$  mmhg or diastolic bp  $<60$  mmhg or objectively measured blood loss of  $\geq 500$  mL, whichever occurs first within 24 hours after birth, and with particular vigilance during the first 2 hours.
- PRIMARY PPH- bleeding within 24 hrs of delivery.
- Causes -4 Ts tone, trauma, tissue, thrombin.
- SECONDARY PPH- bleeding after 24 hrs upto 12 weeks cause retained placenta.

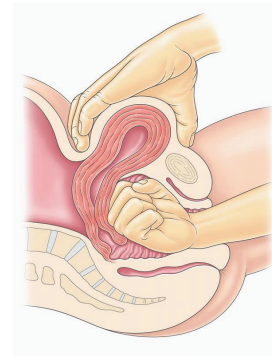

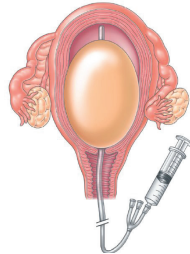
### Preliminary management :

### Medical management :

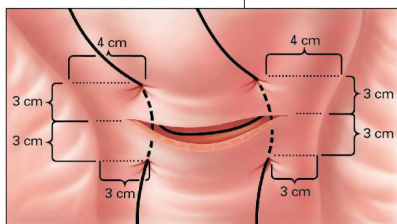
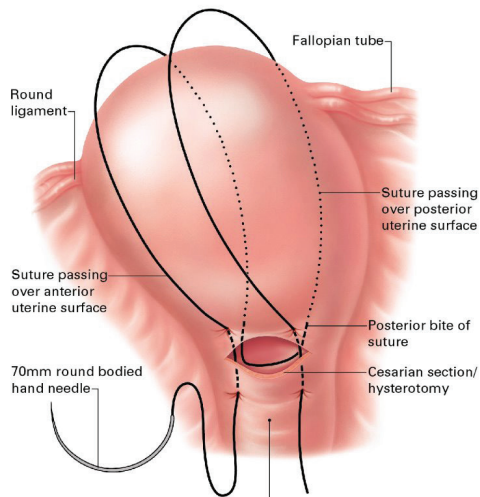
Drugs	Dose	Route	Contraindications	Side Effects
Oxytocin/ Pitocin / Syntocin	10 IU - 40 IU max.	IM / IV drip	Never give IV bolus $\rightarrow$ causes hypotension, arrhythmias.	Water retention
Methergine / Methyl ergometrine / Ergotamine (Amber colored ampoule)	<ul style="list-style-type: none"> <li>• 0.2 mg</li> <li>• Max 5 doses (1 mg)</li> </ul>	IM / IV	<ul style="list-style-type: none"> <li>• After delivery of 1<sup>st</sup> twin</li> <li>• Cardiac diseases</li> <li>• PE / Eclampsia</li> <li>• Rh negative pregnancy.</li> </ul>	<ul style="list-style-type: none"> <li>• Nausea / vomiting</li> <li>• Hypertension</li> </ul>
Carboprost (PGF2 $\alpha$ )	<ul style="list-style-type: none"> <li>• 250 <math>\mu</math>gm</li> <li>• Max. 8 doses (2 mg)</li> </ul>	IM / Intra myometrial	<ul style="list-style-type: none"> <li>• Asthmatics</li> <li>• Active cardiac, hepatic &amp; renal disease.</li> </ul>	<ul style="list-style-type: none"> <li>• Bronchoconstriction</li> <li>• Diarrhoea</li> </ul>
Misoprostol (PGE-1)	800 $\mu$ gm - 1000 $\mu$ gm	PR, buccal, SL or oral	-	<ul style="list-style-type: none"> <li>• Headache</li> <li>• Fever</li> </ul>



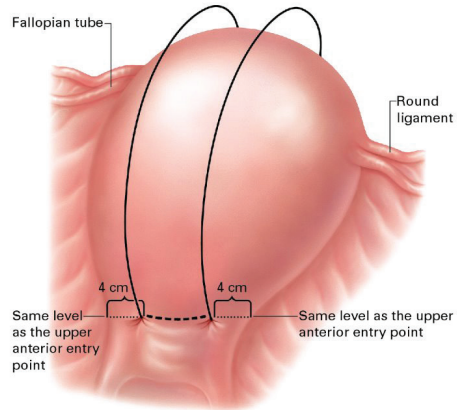
**Tamponade methods :**



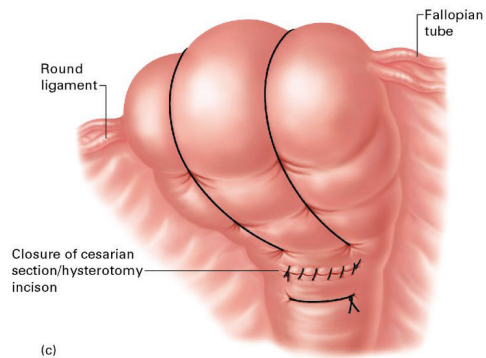
**Surgical methods :**



(a)



(b)



(c)



- Q.** *The following statements are related to PPH except*
- a. *It is always a preventable condition*
  - b. *Atonicity of the uterus is the commonest cause*
  - c. *Intravenous ergometrine with the delivery of anterior shoulder is a prophylaxis*
  - d. *Blood loss during caesarean section exceeds quantitative definition of PPH*
- Q.** *A 32-year-old woman presents with mild vaginal bleeding 10 days post normal delivery. She is well in herself with no pyrexia. She has no allergies. What is the most appropriate next step?*
- a. *Misoprostol 1000 ugm*
  - b. *Misoprostol 600 ugm*
  - c. *TVS*
  - d. *Reassure*
- Q.** *A 30-year-old woman para 6 delivers vaginally following normal labour with spontaneous delivery of an intact placenta. Excessive bleeding continues, despite manual exploration, bimanual massage, intravenous oxytocin and administration of 0.2 mg methergin IV, which one of the following would be the next step in the management of this patient:*
- a. *Packing the uterus*
  - b. *Immediate hysterectomy*
  - c. *Bilateral internal iliac ligation*
  - d. *Injection of PGF 2 $\alpha$*

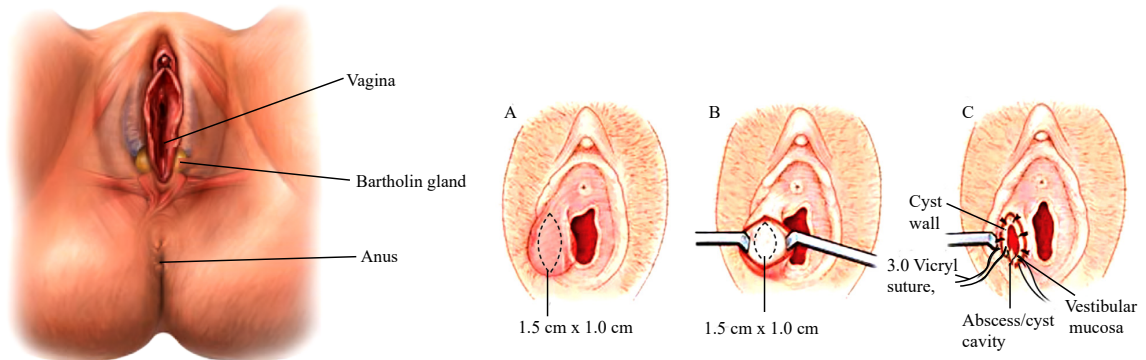


NOTES



NOTES

## GYNAECOLOGY

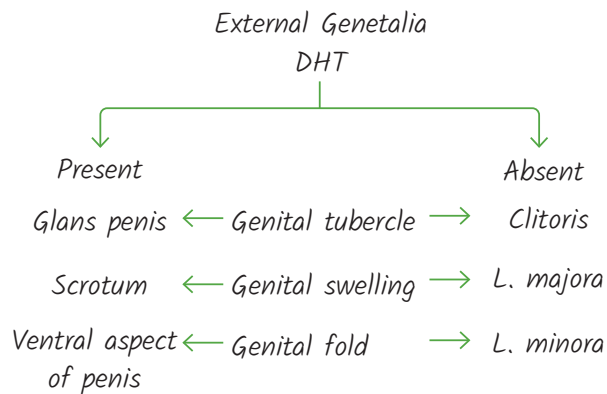
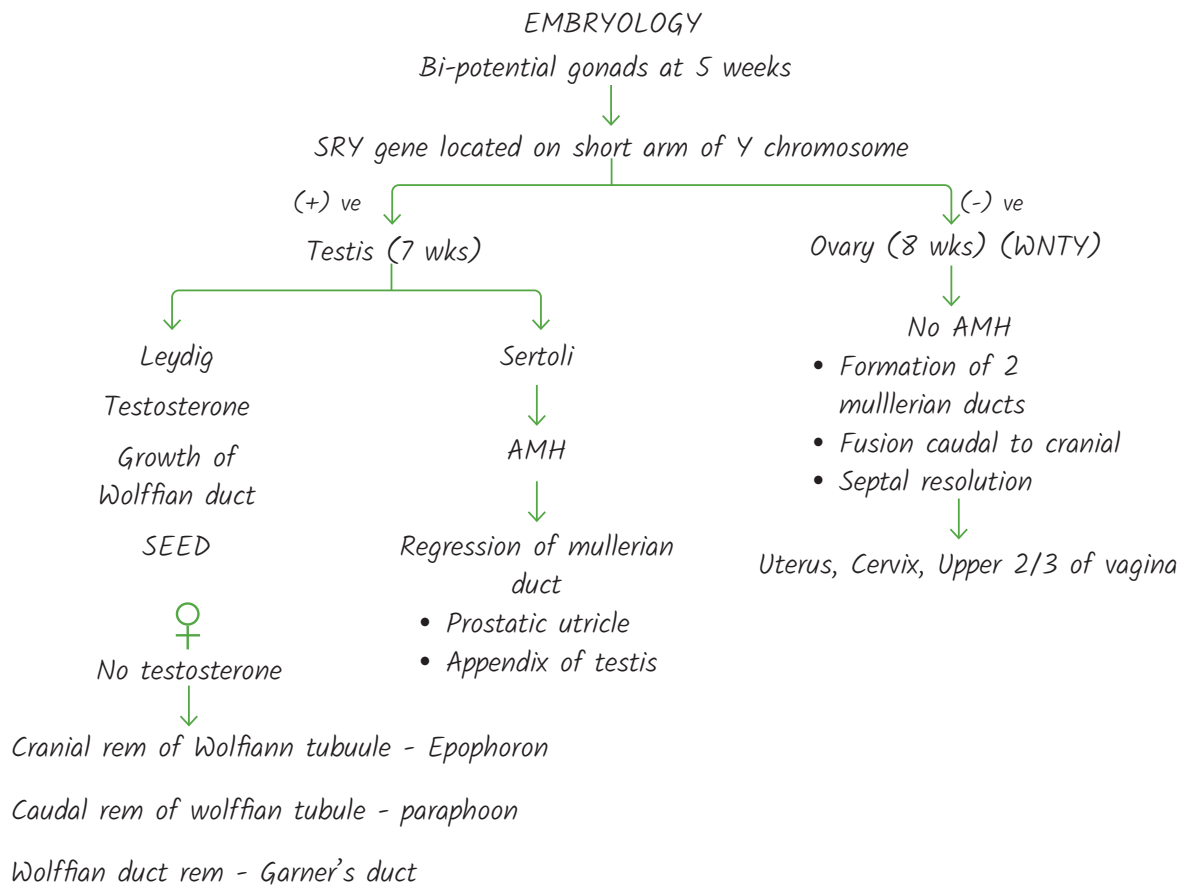


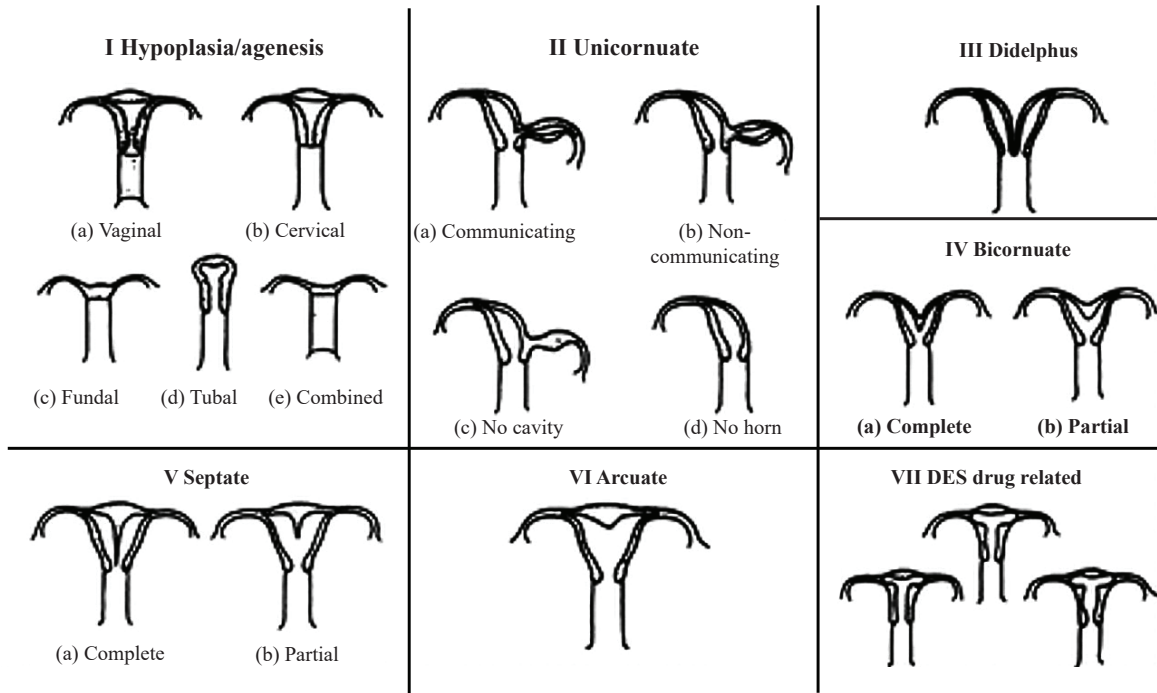
### **Bartholin gland/ Greater vestibular gland:**

- Lies in superficial perineal pouch
- Bartholin ducts is 2cm, opens into a groove between L. Minora and Hymen
- Duct throughout - transitional epithelium
- At opening it is - stratified squamous epithelium

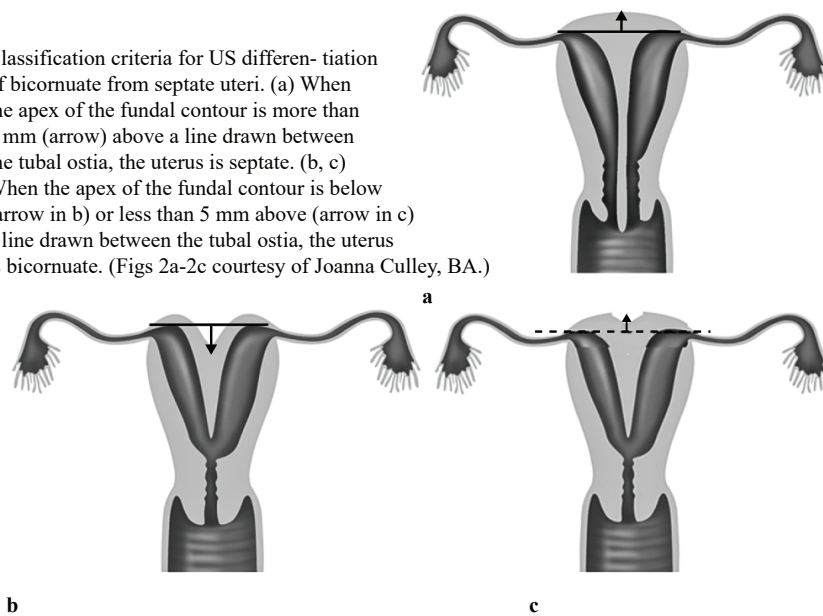
### **Bartholin cyst:**

- Fluctuant, non-tender, mobile
- Recurrent - marsupialization
- Bartholin's Abscess:
- Tender  
m/c → E. Coli > Gonococci
- I and D, words catheter



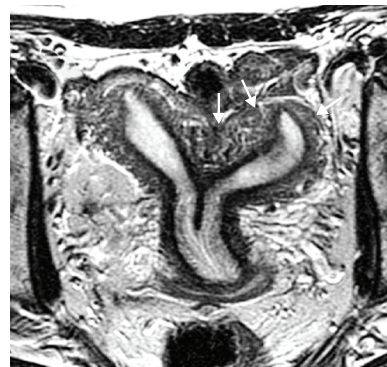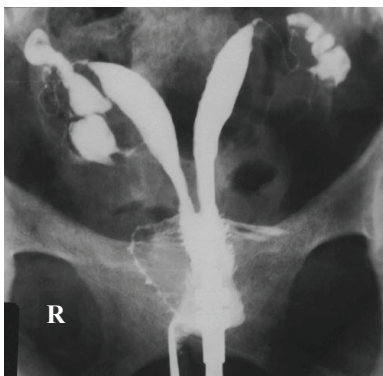
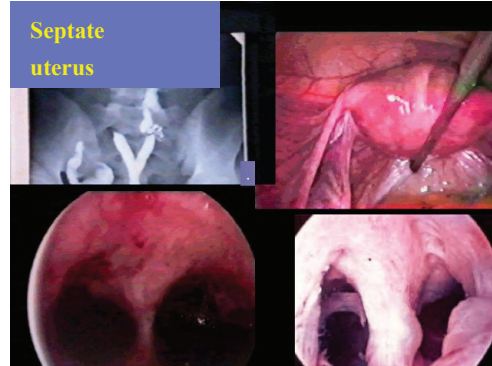
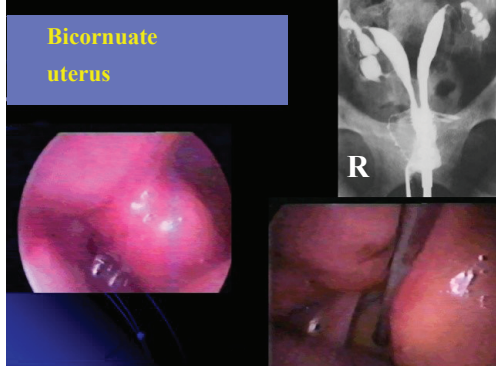
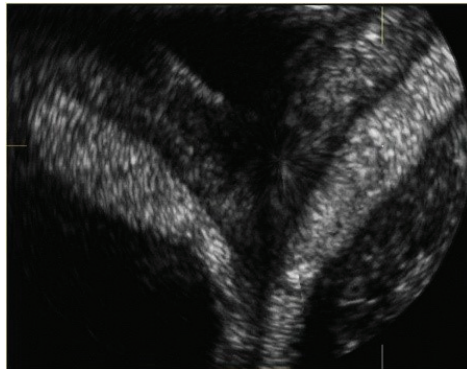
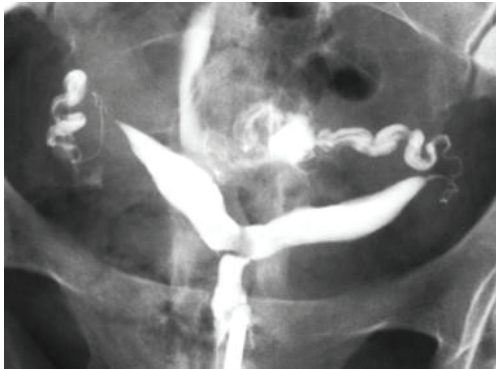


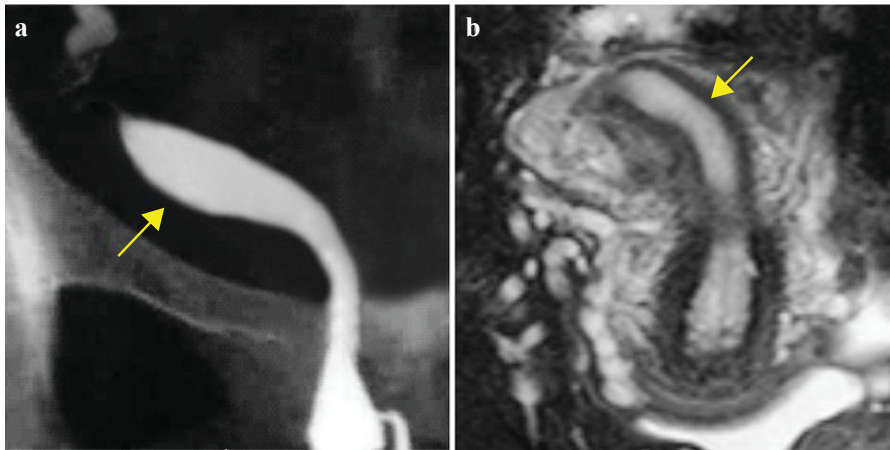
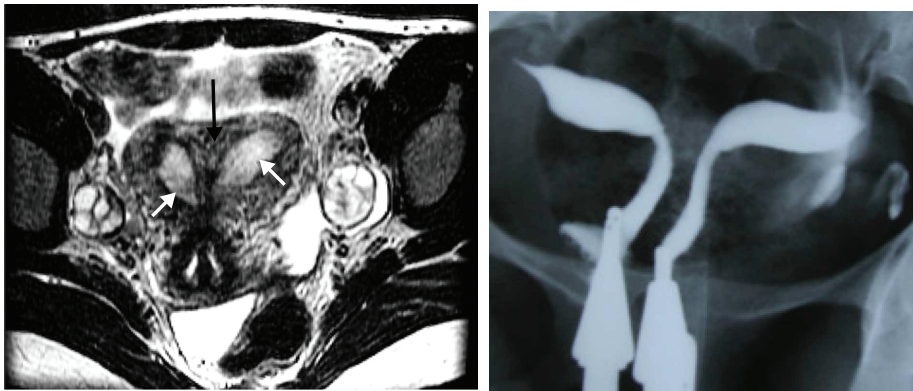
Classification criteria for US differentiation of bicornuate from septate uteri. (a) When the apex of the fundal contour is more than 5 mm (arrow) above a line drawn between the tubal ostia, the uterus is septate. (b, c) When the apex of the fundal contour is below (arrow in b) or less than 5 mm above (arrow in c) a line drawn between the tubal ostia, the uterus is bicornuate. (Figs 2a-2c courtesy of Joanna Culley, BA.)





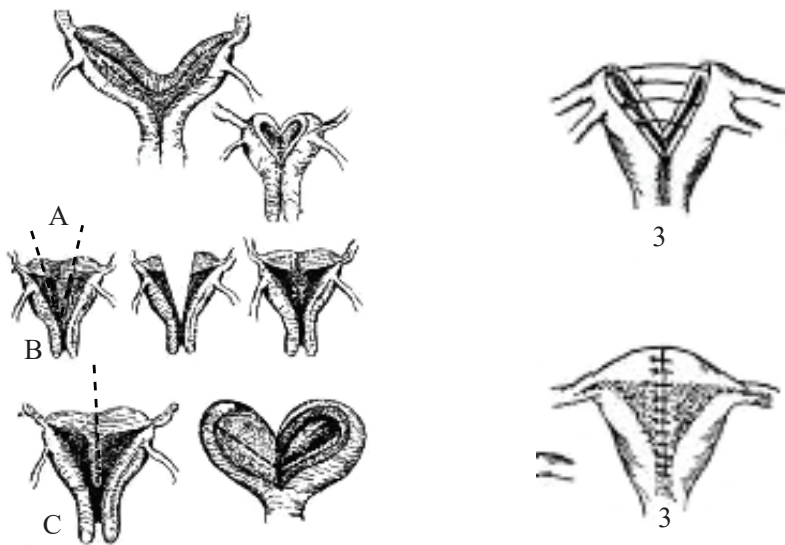
*Investigations*

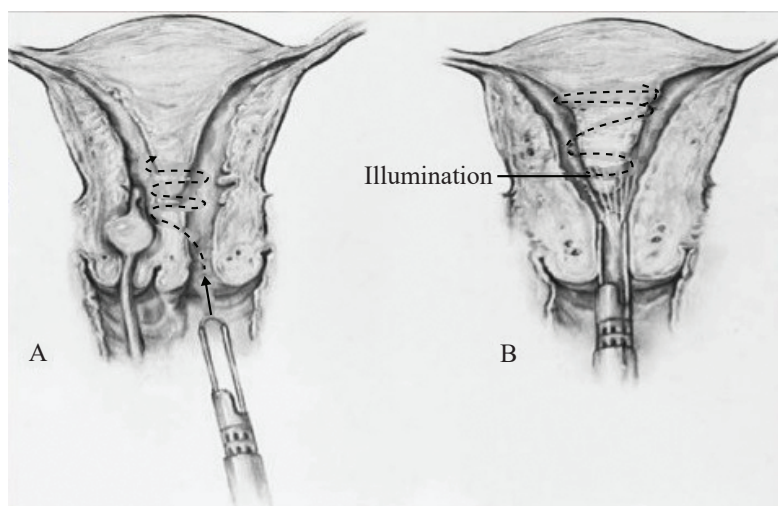




**Treatment**

*Abdominal metroplasty*





**Q. Bicornuate uterus is due to:**

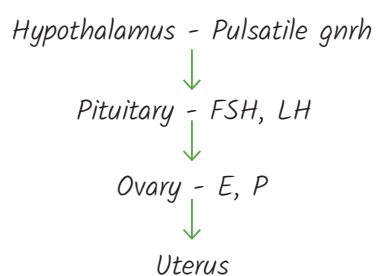
- Incomplete fusion of uterine cavity
- Incomplete fusion of paramesonephric duct
- Incomplete fusion of mesonephric duct
- Incomplete formation of vagina

**Q. The most important indication for surgical repair of a bicornuate uterus is:**

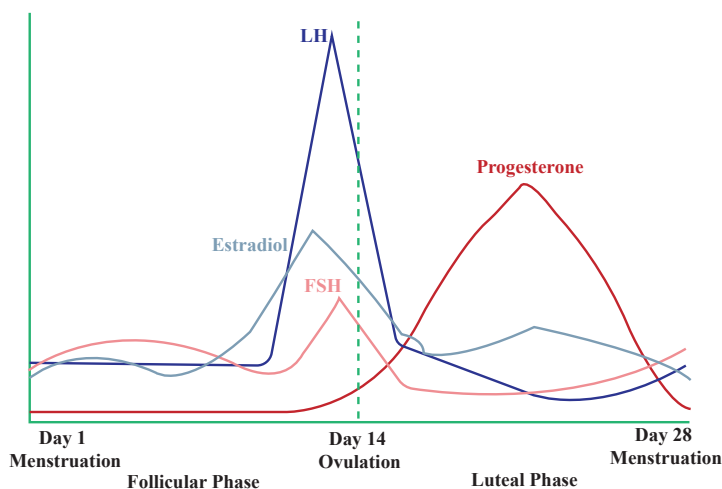
- Infertility
- Dysmenorrhea
- Menorrhagia
- Habitual abortion

## Reproductive Physiology

Endocrine cycle







Q. A 25 year old female has perfectly normal cycles since her puberty . Which of the following pattern of hormones is expected in the proliferative phase, around the time of ovulation and in luteal phase respectively ?

- increased fsh , lh surge , low estradiol
- increasing estradiol , high fsh , high inhibin A
- HIGH PROGESTERONE , HIGH FSH , HIGH ESTRADIOL
- INCREASING ESTRADIOL , high fsh, low inhibin a

Q. Ovulation is characteristically associated with:

- Decreased FSH , LH SURGE
- Decreased LH , FSH SURGE
- LH surge , FSH surge
- Prolactin surge

Q. A 25 year old woman on a routine usg done on day 24 of her cycle , shows a incidental finding of a small thick walled right ovarian cyst with peripheral vascularity. A follow up scan done days post menstrually shows no such cyst . The most probable mechanism involved in resolution of this cystic structure is ?

- increased levels of progesterone
- increased levels of estrogen
- decreased levels of lh
- decreadsed levels of fsh

Q. ABNORMAL UTERINE BLEEDING

Bleeding from uterine corpus that is abnormal in

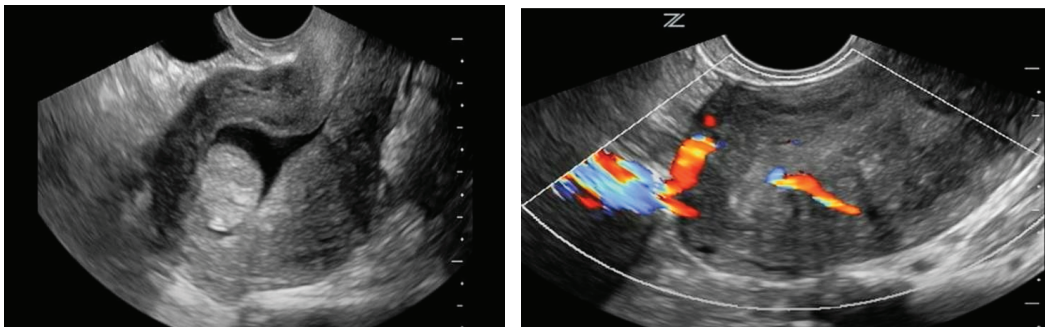
- Regularity,
- Volume,
- Frequency, or

- d. Duration and
- e. Occurs in the absence of pregnancy

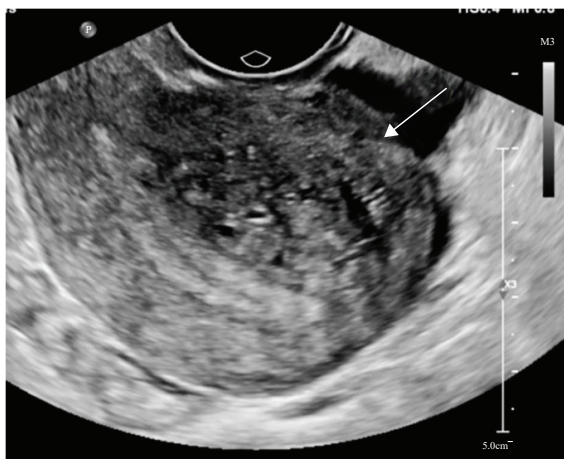**FIGO System of Nomenclature for the etiologies of AUB**

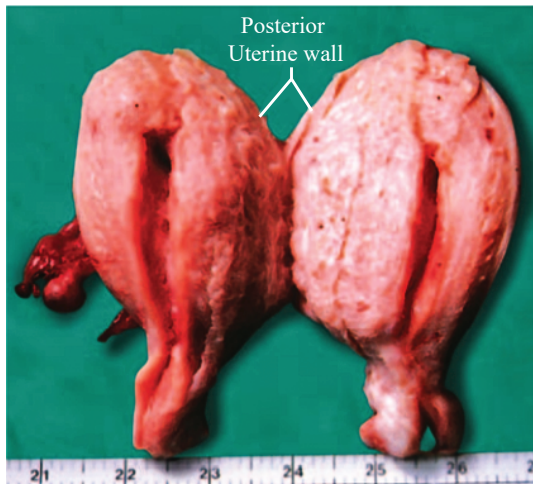- Polyps (P)
- Adenomyosis (A)
- Leiomyoma (L)
- Malignancy & Hyperplasia (M)
- Coagulopathy (C)
- Ovulatory dysfunction (O)
- Endometrial (E)
- Iatrogenic (I)
- Not defined (N)

**Polyp**

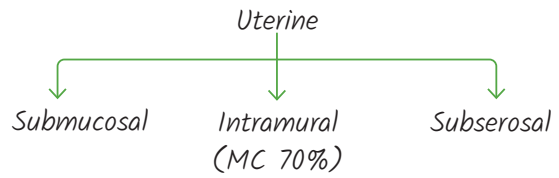


**Adenomyoma**





*Fibroid Nulliparous  
35 - 45 yrs*



*Submucosal - HMB, Infertility, abortion*

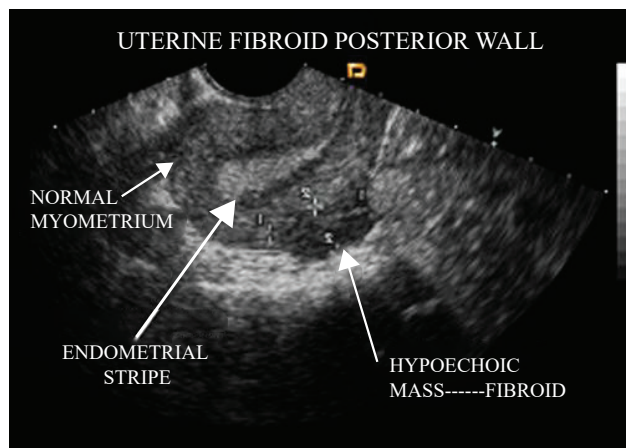
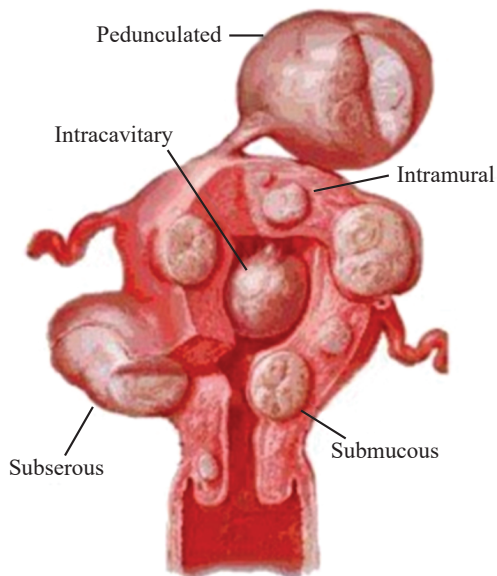
*Intramural - congestive dysmenorrhea*

*Subserosal - pressure symptoms*

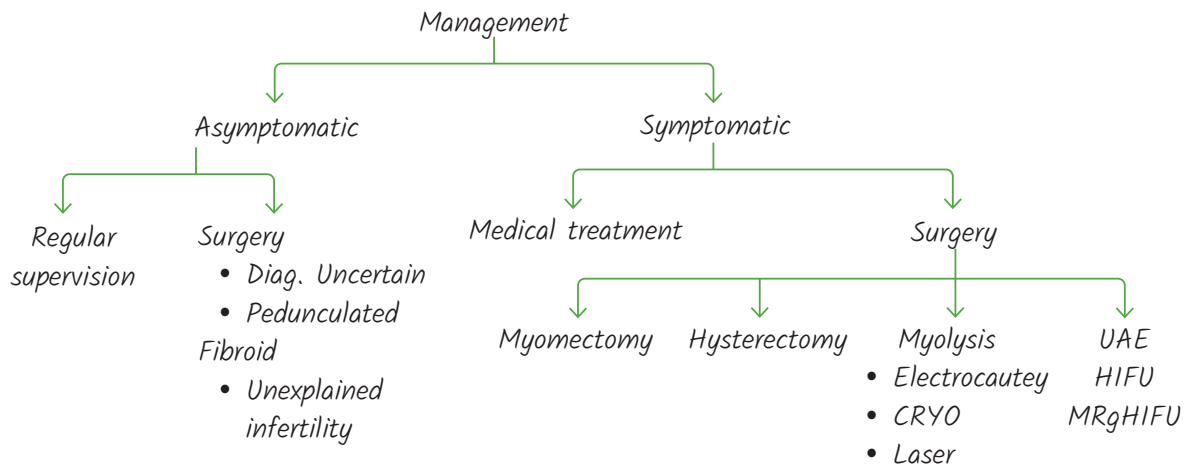
*Anterior cervical fibroid - increased frequency of micturition*

*Central/Posterior cervical fibroid - acute retention of urine*

**Leiomyoma**



- *Most common degeneration - Hyaline degeneration*
- *Least common degeneration - Sarcomatous*
- *Most common degeneration in pregnancy - Red degeneration*



**Q.** A 45-year-old nulliparous woman is being evaluated for inflammatory bowel disease as an inpatient. Ultrasound showed a 5 cm fundal fibroid and a 3 cm anterior wall fibroid. Her periods are regular; 4–5 days in 30 days. She denies any intermenstrual bleeding. She is up to date with smears, with normal results.

- Myomectomy
- GnRH analogues
- Hysterectomy
- Wait and watch

**Q.** A 36-year-old nulliparous woman is being evaluated for secondary subfertility. She has regular heavy periods lasting for 7 days every month. Ultrasound shows a 4 cm-sized pedunculated fibroid impinging into the uterine cavity.

- laparoscopic Myomectomy
- GnRH analogues
- Hystroscopic myomectomy
- Wait and watch

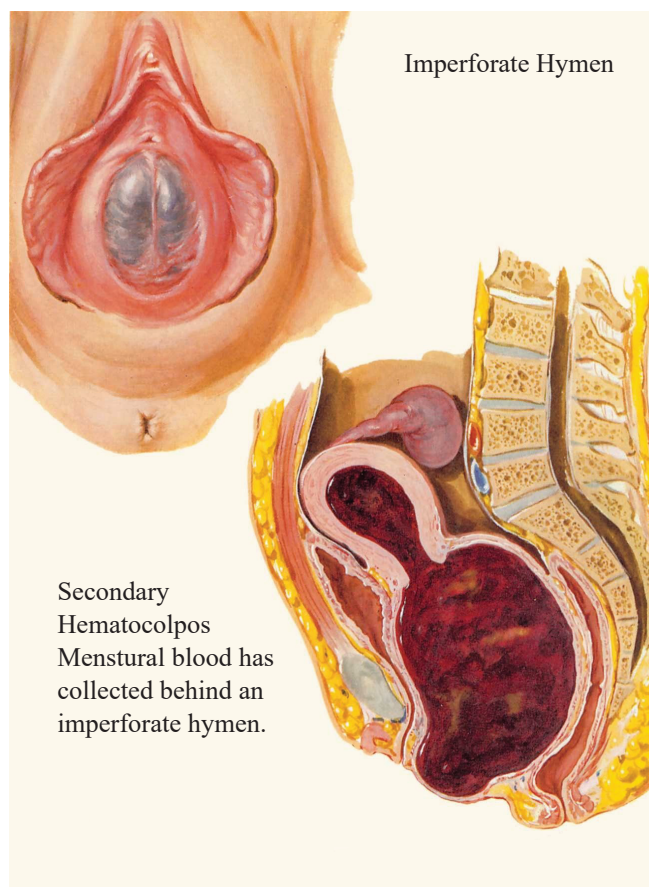
## Amenorrhoea

### Primary Amenorrhoea

- In absence of secondary sexual characters, no menses till the age of 13 years.
- In presence of secondary sexual characters, no menses till the age of 15 years.
- NO menstruation after 3 years of attaining secondary sexual characters .



### False Primary Amenorrhea / Cryptomenorrhea



### Turner's MC

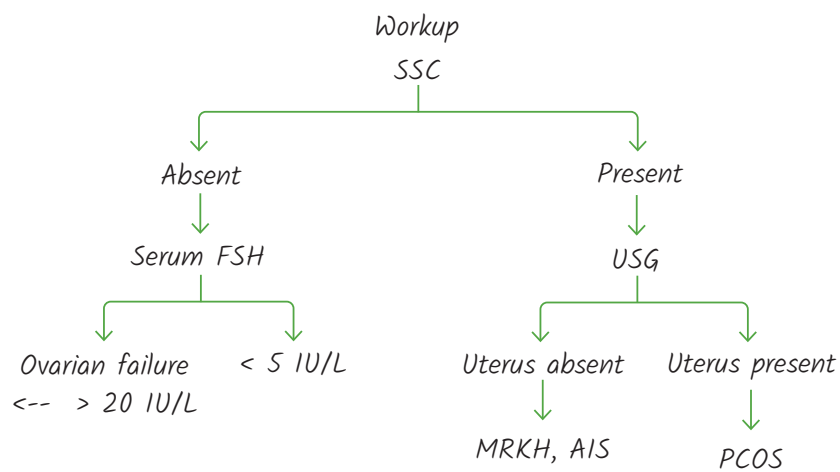
45 XO

Turner Mosaic - 46 XX/45 XO - sec amenorrhea

- Short stature
- Webbed neck
- Flat chest with widely spaced nipples
- COA with bicuspid valve
- SNHL
- Thyroiditis
- Cubitus Valgus, short 4th metacarpal
- Horseshoe kidney
- Infantile uterus, streak ovary
- DM

**True Primary Amenorrhhea**

	<b>Karyotype</b>	<b>Gonad</b>	<b>SSC</b>	<b>Uterus</b>	<b>External Genitalia</b>	<b>Rx</b>
Turner's	45X0	Streak ovary	Absent	Present	♀	HRT with E+P
MRKH	46XX	Ovary	Present	Absent	♀	Vaginoplasty Surrogacy
AIS	46XY	Testis	Breast Absent	Absent	♀	Gonadectomy Vagino- plasty HRT with E
Sweyers	46XY	Streak ovary	Absent	Present	♀	Gonadectomy HRT E+P
Kallman's	46XX	Ovary	Absent	Present	♀	Pulsatile GnRH Inj HCG
5 $\alpha$ reductase deficiency	46XY	Testis	Virilization	Absent	♀	External genitalia reconstruction



	<b>5<math>\alpha</math>-reductase</b>	<b>Complete</b>	<b>Incomplete</b>	<b>Reifenstein</b>
<b>Inheritance</b>	Autosomal recessive	X-linked recessive	X-linked recessive	X-linked recessive
<b>Spermatogenesis</b>	Decreased	Absent	Absent	Absent
<b>Mullerian</b>	Absent	Absent	Absent	Absent
<b>Wolffian</b>	Male	Absent	Underdevp	Male
<b>External</b>	Female	Female	Female clitoromegaly	Male hypospadias
<b>Breasts</b>	Male	Female	Female	Gynecomastia
<b>Axillary and Public Hair</b>	+++	Absent	Scanty	Present

**Q.** A 19-year old patient complains of primary amenorrhea. She had well developed breast and pubic hair but on examination there was absence of uterus and vagina. Likely diagnosis is:

- XYY
- Mullerian agenesis
- Gonadal dysgenesis
- Klinefelter syndrome

**Q.** A 16 year old girl with blind vagina and absent uterus presents to you. The investigation you will like to do first is:

- Intravenous pyelography
- FSH
- Karyotyping
- CT scan of pelvis

### Secondary Amenorrhea

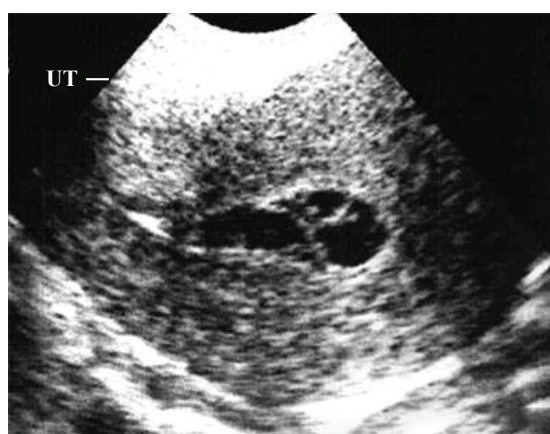
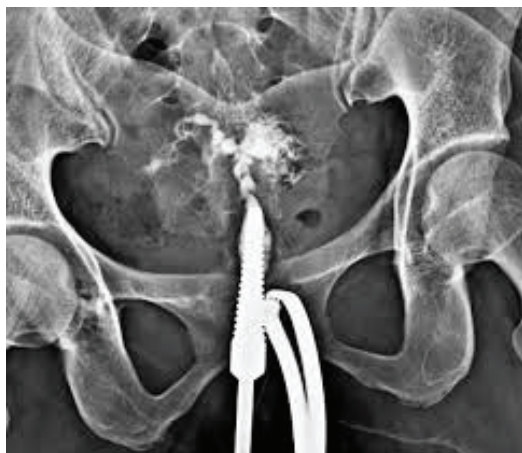Secondary amenorrhea is defined as absence of menses for 6 consecutive months (or length of time equivalent to total of three previous regular cycles) in a female who had previously regular menses.

Pregnancy is the MC cause of secondary amenorrhea.

### Causes

#### Asherman syndrome :

- Uterine synachie
- Postpartum curettage highrisk of Ashesman
- IOC gold - Hysteroscopy
- Rx - Hysteroscopic adhesiolysis



### Hypothalamus

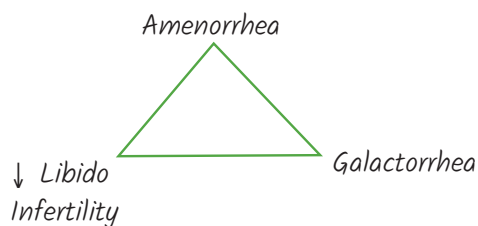
- Stress
- TB/Sarcoidosis
- Trauma
- Tumour
- Excessive exercise
- Eating disorder

### Pituitary

#### Sheehan's

- Postpartum pituitary necrosis
- All ant pituitary lost
- 1st to lose - GH
- M/C - Lactation failure
- Rx - E+P, Thyroxine, Cortisol supplementation

### PROLACTINOMA



Sr PRL > 30 ng/ml

Sr. TSH

Sr PRL > 150 MRI

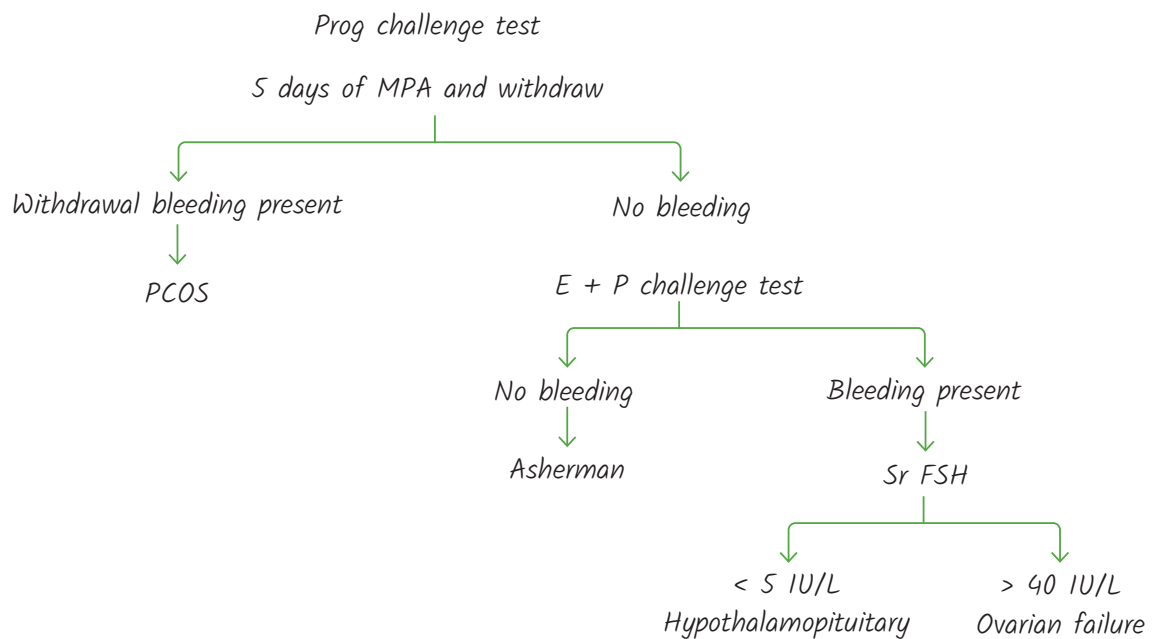
POC - Cabergoline

### Ovarian

POF. Savage Syndrome

PCOS

### Work up





### Work up for Secondary Amenorrhea

#### Steps to be followed in evaluation of secondary amenorrhea:

- Rule out pregnancy (urine pregnancy test/Sr.  $\beta$ -hCG)
- TSH and Prolactin estimation (easily correctable hormonal conditions causing amenorrhea)
- Progesterone challenge test (PCT) PCT

**Q.** A 23-year-old female came with complaints of 4 months amenorrhea. The FSH and LH were elevated above the normal value, thyroid function test were normal. Which is the next step in management?

- a. Give progesterone and stop after 10 days for withdrawal bleeding
- b. Check USG for polycystic ovaries
- c. Estimate serum estradiol values
- d. Do a urine pregnancy test

**Q.** Child with primary amenorrhea with negative progesterone challenge test but positive combined progesterone and estrogen test. Diagnosis may be:

- a. Mullerian agenesis
- b. PCOD
- c. Asherman syndrome
- d. Prolactinoma

**Q.** An 18-year-old national gymnastic champion is referred to you. She experiences long periods of secondary amenorrhea and she only has two to three periods each year. She is training for the coming Olympics but her general practitioner advised her to visit you because she is worried about her. She suffers from backache. Her BMI is 16.

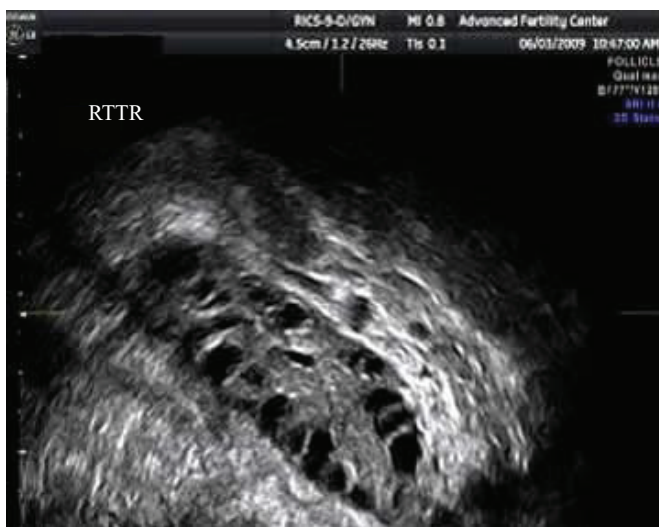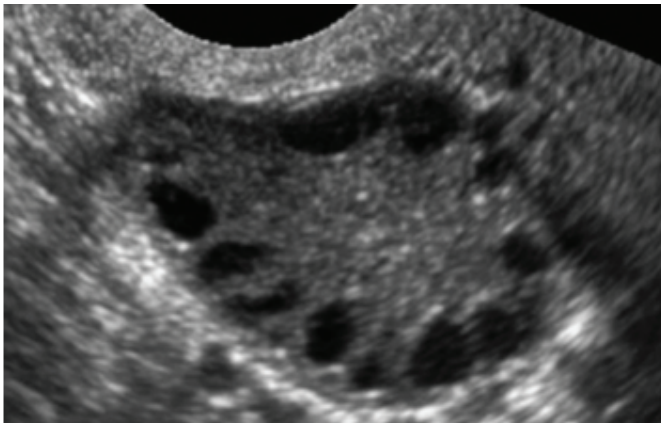
What will you offer her?

- a. Cyclic COCP.
- b. Cyclic progesterone for withdrawal bleeding.
- c. Depomedroxy progesterone acetate.
- d. GnRH analogue

### *pcos*

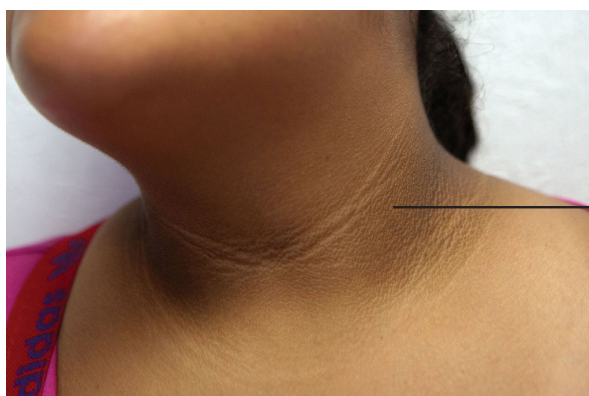- *PCOD / PCOS is the most common endocrine disorder among the reproductive age group people ( mainly 15 – 25 years)*
- *It is the commonest cause of anovular infertility*
- *It is a treatable cause of infertility*

### *Pathophysiology*



### *Complications*

- *Infertility*
- *DM*
- *Metabolic syndrome*
- *Endometrial hyperplasia*
- *Endometrial Ca*
- *Breast Ca*
- *Depression*
- *Sleep apnea syndrome*
- *Non alcoholic fatty liver*



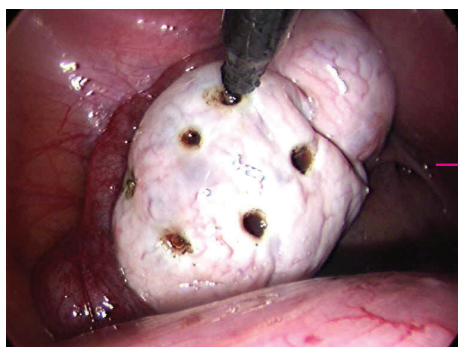
→ Acanthosis Nigricans

### Diagnosis

- 2023 international criteria - at least two out of three should be present:
  1. Oligo/anovulation
  2. Hyperandrogenism: biochemical or clinical
  3. 20 or > 20 follicles 2–9 mm in size present within one or both ovaries on USG and/or ovarian volume > 10 mL > 10 follicles per section  
or  
AMH

### iii. Adhesion formation post-surgery

Main Complaint	Management of Choice
Irregular cycles with oligomenorrhea and secondary amenorrhea	OCP pills with 3 <sup>rd</sup> or 4 <sup>th</sup> generation progestin
Obesity	Metformin + OCP
Insulin resistance	Metformin
Hirsutism	OCP with cyproterone acetate
Infertility	Letrozole 1 <sup>st</sup> Line Clomiphene citrate (2 <sup>nd</sup> Line)



→ Last resort:

4 holes, 40 mV, 4 mm depth

Laparoscopic ovarian drilling

**Q.** *A 28-year-old lady, Rani, is suspected to have polycystic ovarian disease. Sample for testing LH & FSH are best taken on the following days of menstrual cycle:*

- a. 1-4
- b. 8-10
- c. 13-15
- d. 24-26

**Q.** *A 16-year-old girl presents with rapid onset hirsutism. Best investigation is:*

- a. Testosterone estimation
- b. Dihydroepiandrosterone
- c. Adrenocorticoids
- d. LH and FSH estimation



## Infertility

- Infertility is defined as an inability to conceive in spite of 1 year of regular unprotected intercourse age 35yrs - 6 months

## Female Infertility

### WHO Category for Anovulation

- I: Hypothalamic pituitary failure
- II: Hypothalamic pituitary disturbance/PCOS
- III: Ovarian failure
- IV: Hyperprolactinemia

### Ovarian Indicators

- Regular
- Mittelschmerz
- Primary spasmodic dysmenorrhea
- Rise in BB + by 0.5 °C
- Cervial mucous changes

Estrogen	Progesterone
Thin, copious	Scanty, thick
Spinbarkiet	Tack
Ferning present	Absent

- PMS
- Day 25 Sr Prog
- Day 14 urinary LH surgery
- Maturation index  
P/S/I  
0/40/60
- USG  
Trilaminar  
Endometrium
- EB on day 22

## Management

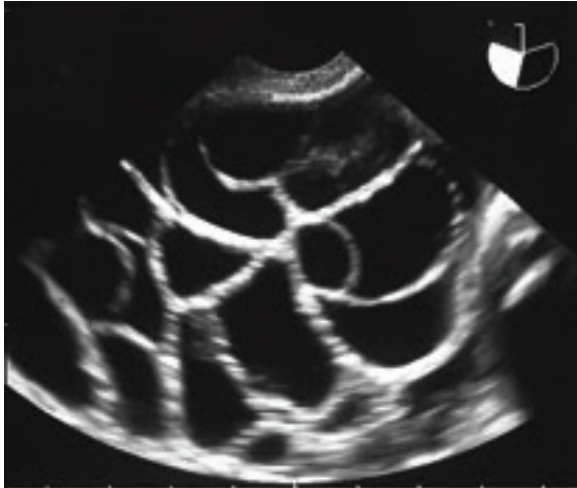
### Ovulation Induction Agents

1. Clomiphene citrate (CC)
2. Letrozole, Anastrozole, Tamoxifen
3. Gonadotrophins

	Clomiphene citrate	Letrozole	Gonadotrophins
	SERM	Aromatase inhibitor	Inj HMG Rec FSH, LH
MOA	Block E2 receptors on pituitary	test * estro	
Dose	50 mg/day Max 150 mg/day	2.5 - 5 mg/day	150 - 400 IU/day
SE	Hot flashes Pain abd Blurring of vision	Congenital malformations	

Q. A patient treated for infertility with clomiphene citrate presents with sudden onset of abdominal pain and distension with ascites, the probable cause is:

- a. Uterine rupture
- b. Ectopic pregnancy rupture
- c. Multifetal pregnancy
- d. Hyperstimulation syndrome



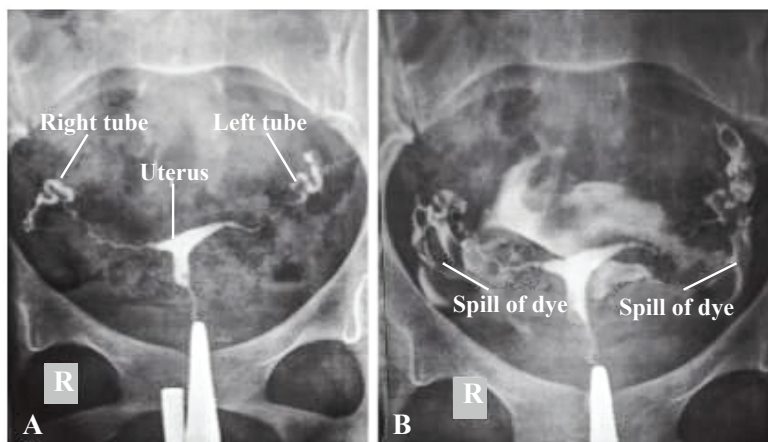
### Markers of Ovarian Reserve

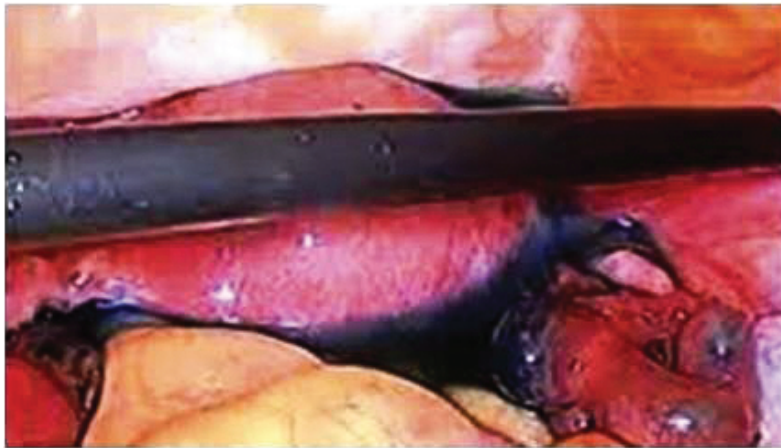
- Best AMH
- D2 AFC
- D2 Sr FSH
- D2 Sr Estradiol/ Inhibin
- CCC Test

### Tubal Investigation

1st line HSG

Disadvantage - B/L Cornual block - due to cornual spasm → Gold standard Laproscopic chromopertubation





**Q.** *Lady with infertility with bilateral tubal block at cornua; best method of management is:*

- a. *Laparoscopy and hysteroscopy*
- b. *Hydrotubation*
- c. *IVF*
- d. *Tuboplasty*

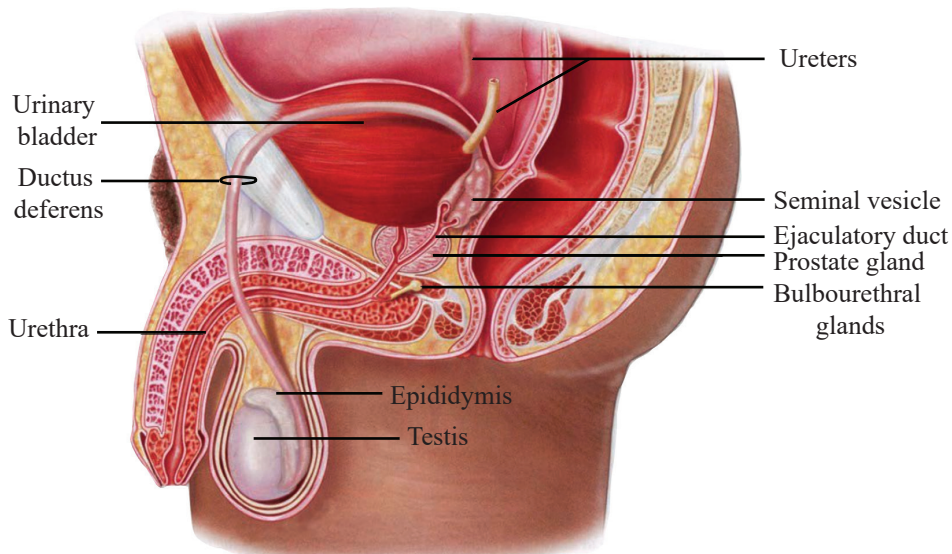
**Q.** *Management of tubal factors:*

- 1. *Cornual block: cornual catheterization or cannulation (operative hysteroscopy) to remove the blocks*
- 2. *Midsegmental tubal blocks: tuboplasty*
- 3. *Sistal tubal block:*
- 4. *Mild-fimbrioplasty severe -IVF*

**Q.** *An infertile women has bilateral tubal block at cornua diagnosed on hysterosalpingography. Next step in treatment is:*

- a. *IVF*
- b. *Laparoscopy and hysteroscopy*
- c. *Tuboplasty*
- d. *Hydrotubation*

## Male Infertility



## Human Semen Analysis

- *New Semen Analysis Criteria as per 'WHO Manual for Semen Analysis 2020*
- *Semen volume: 1.4 mL or more*
- *pH: 7.2 or more*
- *Count: 16 million/mL or more*
- *Motility (within 1 hour of collection) total motility (progressive + non progressive): 42 % or more*
- *Progressive motility: 30% or more*
- *Vitality (live spermatozoa): 54 % or more*
- *Sperm morphology (normal forms): 4 % or more*
- *Leucocytes less than 1 million /ml*
- *Round cells less than 5 million/ml*
- *Agglutination less than 10 %*
- *Aspermia: absence of semen*
- *Azoospermia: zero sperm count*
- *Asthenospermia: less than 40% motile spermatozoa*
- *Oligozoospermia: count less than 16 million/mL*
- *Teratospermia: less than 4% normal f*

*< 5 million ICSI  
5-10 million IVF  
10 - 16 million IUI*



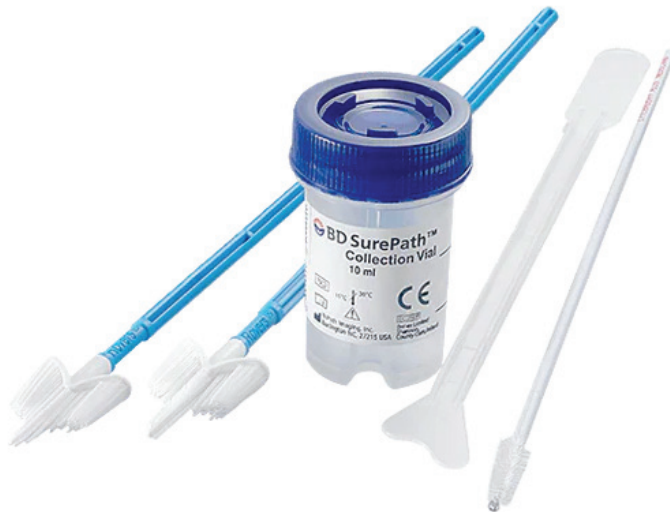## QUESTIONS

- Q.** *A 36-year-old Asian woman attends the infertility clinic with her husband. She has been trying to conceive for the last 2 years. She is overweight and gives a history of irregular periods over the last 2 years. Her history and investigations are suggestive of polycystic ovary syndrome (PCOS). She has been using clomiphene citrate for the last 6 months with day 21 progesterone of 10 ng/L. Her husband's semen analysis is normal. What is management ?*
- Perform laparoscopy and dye test*
  - Arrange in vitro fertilisation (IVF)*
  - Bilateral ovarian drilling*
  - Counsel and offer support*
- Q.** *A 36-year-old Caucasian woman attends the infertility clinic with her husband. She has been trying to conceive for the last 2 years. She is overweight and gives a history of irregular cycles for the last 2 years. Her history and investigations are suggestive of PCOS. She has been using clomiphene citrate for the last 8 months. Hysterosalpingogram reveals patent fallopian tubes. Her husband's semen analysis is normal.*
- Perform laparoscopy and dye test*
  - Arrange in vitro fertilisation (IVF)*
  - Bilateral ovarian drilling*
  - Counsel and offer support*
- Q.** *Ms XY (30 years) and her male partner (26 years) have been trying to conceive naturally for the last 3 years. They have had infertility investigations over the last year. These include a normal semen analysis, normal USS pelvis, normal HSG, normal TSH, prolactin, D3 FSH, LH and normal AMH. Her day 21 progesterone suggest ovulation. Ms XY is rubella immune and has negative swabs for an STI. Her recent cervical smear is normal. Which of the following treatment options are best suited to her?*
- Clomiphene citrate*
  - IUI*
  - IVF-ICSI*
  - IVF*
  - Letrozole*

## CIN

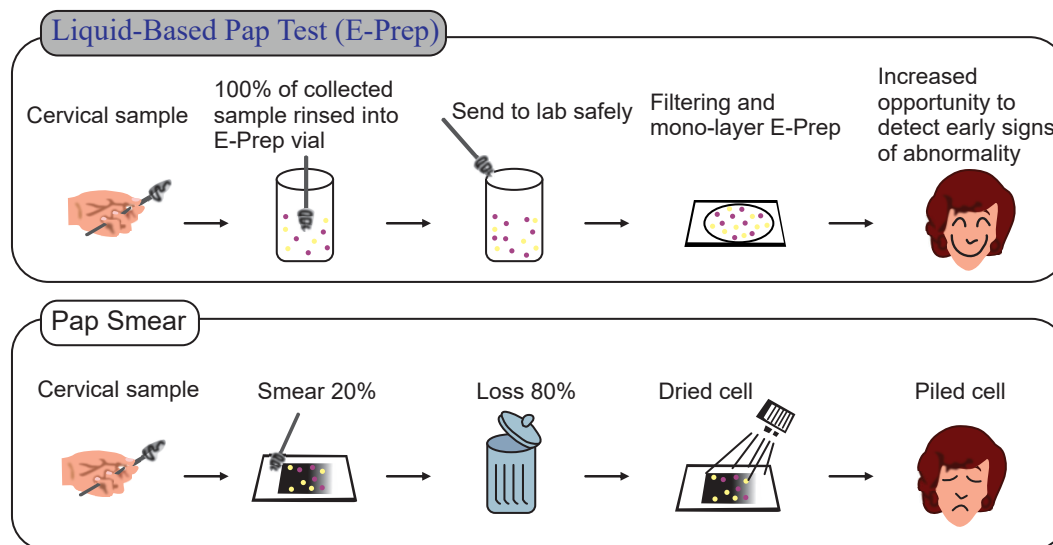
### Screening

- PAPANICOLAOU SMEAR
- LIQUID-BASED COLLECTOR
- HPV DNA TESTING
- VIA
- VILI





## Liquid Based Cytology Processor



## Screening Guideline

### ACOG

Start screening at age 21 - 29 yrs

Pap smear/ LBC every 3 yrs

30 - 65 yrs - pap smear/LBC every 3 yrs

or

Papsmear + HPV co-testing every 5 yrs

or

HPV co-testing every 5 yrs

Stop screening after 65 if previous 3 screens are negative

### WHO

Start age 30

HPV DNA testing every 5-10 yrs

Upto 50 yrs

HIV +VE 25 yrs

HPV DNA testing every 3 yrs

**Q.** Rekha a 45-years-old woman has negative pap smear with positive endocervical curettage. Next step in management will be:

- Colposcopy
- Vaginal hysterectomy
- Conisation
- Wertheim's hysterectomy

## Indication OF CONE BIOPSY/CONIZATION

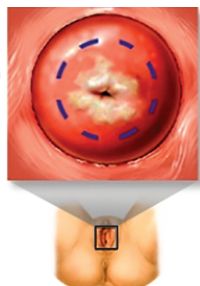### Diagnostic

- Limits of the lesion can not be visualised with colposcopy
- The squamocolumnar junction / TZ is not seen at colposcopy
- In endocervical curettage, histological findings are positive for CIN - II or CIN - III or Cancer in situ
- Microinvasive carcinoma or adenocarcinoma in situ is suspected based on pap, biopsy or colposcopy
- Lack of correlation between cytology, biopsy and colposcopy results.

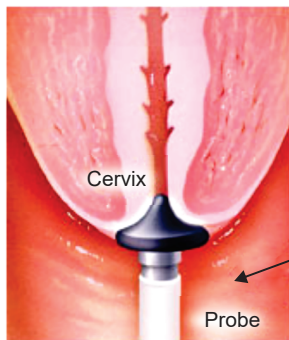
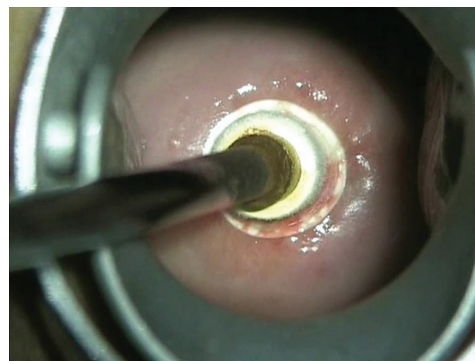
### CIN TREATMENT

- CIN I
  - Do HPV - DNA and Pap smear every 6 months
  - If HPV DNA is positive or repeated Pap smear show ASCUS or higher then do colposcopy.
  - Abnormalities persists for 2 years - Ablative procedure / LEEP.
- CIN II - ablative procedure or LEEP
- CIN III - LEEP (any age group)
- Recurrent CIN III - Hysterectomy
- CIN extending to vaginal fornices - Laser ablation/Hysterectomy.

Compressed nitrogen gas flows through a cryo probe making the metal cold enough to freeze and destroy the abnormal cervical tissue



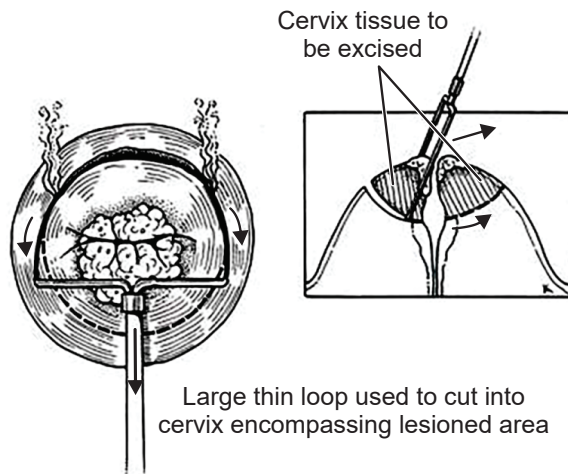
Cervix as viewed through speculum with patient in lithotomy position



The Cryotherapy probe is extremely cold. when it comes into direct contact with the cancerous cells on the cervix, it freezes them and they die.



### Large Loop Excision of the Transformation Zone



<b>Cryotherapy</b>	<b>Laser ablation</b>	<b>Loop electro excision procedure</b>
Liquid CO <sub>2</sub> / N <sub>2</sub> O	CO <sub>2</sub>	2 cm electric loop
At - 100 °C	At 100 °C	10 mm
5 mm	7 mm	

**Q.** A 40 year old woman presents with abnormal cervical cytology on PAP smear suggestive of CIN (III). The next best step in management is:

- Hysterectomy
- Colposcopy and LEEP
- Colposcopy and cryotherapy
- Conization

**Q.** A 28-year-old nulliparous woman is referred to the colposcopy clinic by her general practitioner. She is up to date with smears and never had any previous abnormal smears other than the current cervical smear showing mild dyskaryosis. Colposcopy reveals a mild acetowhite area at the 11 o'clock position and is reported as satisfactory with no abnormal vessels.?

- Knife cone biopsy
- Large loop excision of transformation zone (LLETZ)
- Needs discussion in the multidisciplinary team (MDT) meeting
- Punch biopsy of the cervical lesion

## Ca Cervix

HPV 16, 18 - Ca Cervix

HPV 31, 33 - CIN

### 4 Cardinal symptoms

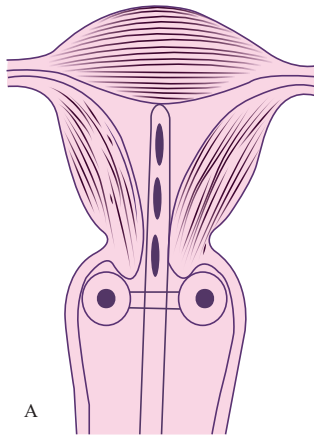
- Irregular vaginal bleeding
- Pelvic pain
- Post coital bleeding
- Foul smelling discharge

### 4 Cardinal signs

- Cauliflower like growth
- Hard indurated
- Fixed
- Friable
- Bleeds on touch

## Ca Cervix Management

- STAGE I A1 WITHOUT LVSI : TYPE 1 HYSTERECTOMY
- STAGE I A1 WITH LVSI AND STAGE I A2: TYPE 2 HYSTERECTOMY + PELVIC LYMPHADENECTOMY
- STAGE I B1, I B2, I I A1: TYPE 3 HYSTERECTOMY + PELVIC LYMPHADENCTOMY
- STAGE I B3, I I A2- IV: CCRT



Stage I : Confined to cervix

Ia<sub>1</sub> - < 3 mm in depth

Ia<sub>2</sub> - 5 mm in depth

Ib<sub>1</sub> <math>\left. \begin{array}{l} < 5 \text{ mm.} < 2 \text{ cm} \\ < 2-4 \text{ cm} \\ < 4 \text{ cm} \end{array} \right\}</math>

Ib<sub>2</sub> <math>\left. \begin{array}{l} < 5 \text{ mm.} < 2 \text{ cm} \\ < 2-4 \text{ cm} \\ < 4 \text{ cm} \end{array} \right\}</math>

Ib<sub>3</sub> <math>\left. \begin{array}{l} < 5 \text{ mm.} < 2 \text{ cm} \\ < 2-4 \text{ cm} \\ < 4 \text{ cm} \end{array} \right\}</math>

Stage II - upper 2/3rd of vagina

IIa - without PM inv

IIa1 < 4cm

IIa2 > 4 cm

IIb - with PM inv

Stage III - lower 1/3rd of vagina

IIIa - without LP inv

IIIb - with LP invo

Hydronephritis, hydroureter

IIIc<sub>1</sub> - Pelvic LN

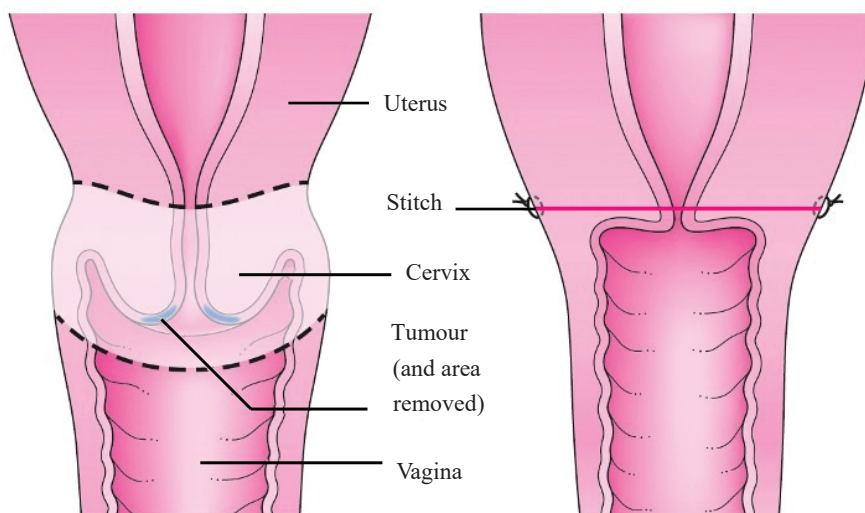
IIIc<sub>2</sub> - Paraaortic LN

IVa - Bowel and bladder

IVb - Distant metastasis

### Conservative Surgery

- Conisation : STAGE I A1
  - It refers to the excision of the whole of endocervix and the whole of TZ in the form of a cone
- RADICAL Trachelectomy : IA2, IB1,
  - It refers to the removal or amputation of cervix
  - Radical trachelectomy refers to removal of cervix, parametrial tissues (Mackenrodt's ligaments) and vaginal cuff along with pelvic lymphadenectomy



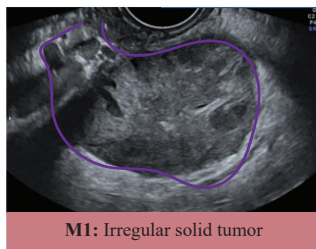
### Vaccine:

Gardasil	Gardasil 19	Cervarix
HPV 6, 11, 16, 18	6, 11, 16, 18, 31 33, 45, 52, 58	HPV 6, 11, 16, 18
< 15 yrs 2 doses 0, 6 months > 15 yrs 3 doses 0, 2, 6 months		

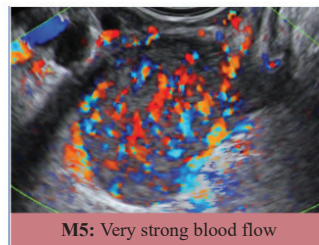
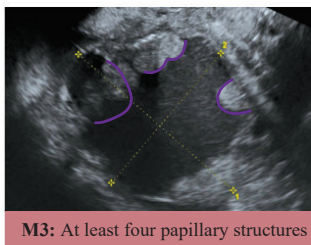
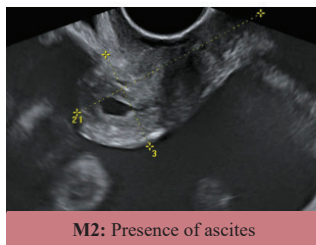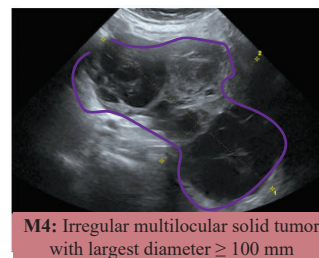
### Ovarian Cancer

Ovarian cancer	histogenesis	Frequency	Types	Age Group
Epithelial	Coelomic epithelium	85-90%	Serous, mucinous endometrioid, clear cell, Brenner undifferentiated	Peri/ postmenopausal (45+ years)
Sex cord stromal	Gonada Arrhenoblastoma	5-7%	Granulosa cell tumour Sertoli-leydig cell tumour	Reproductive (20-40 years)
Germ cell tumors	Primitive germ cells	6-7%	Dysgerminoma, endodermal sinus tumor, embryonal, teratoma, chorio CA	Prepubertal- pubertal (15-20 years)

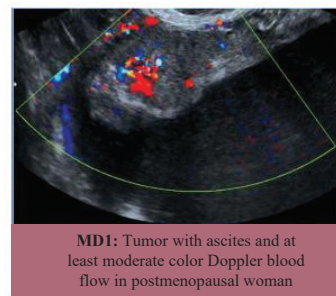
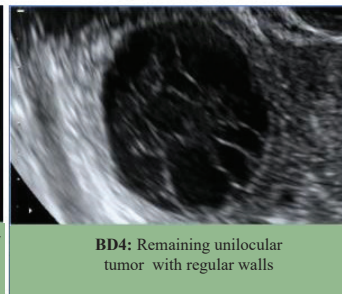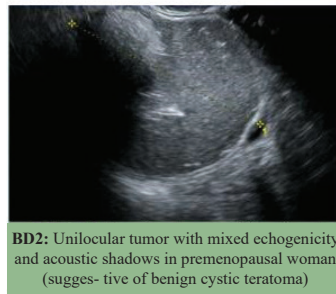
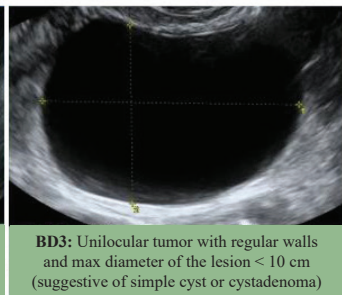
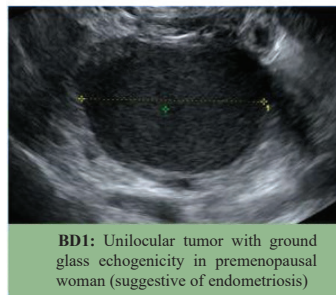
Others	metastatic		krukenberg	



A mass is classified as malignant if at least one M-feature is present and no B-features are present



*Simple Descriptors of An Ovarian Mass Used To Make A Diagnosis*





### Tumor Markers in Ovarian Cancer

Ovarian Tumor	Tumor marker
Endodermal sinus tumor/yolk sac tumor	AFP
Epithelial ovarian tumors (Especially serous cell, Leydig cell, Hilus cell tumors, Sertoli cell)	CA-125 Testosterone
Dysgerminoma	LDH, alkaline phosphatase
Choriocarcinoma	hCG
Mucinous tumors	CEA
Granulosa cell tumor	Inhibin
Embryonal Ca	AFP, HCG

- The endodermal sinus tumor is unilateral in 100% of cases Granulosa cell tumors are unilateral in 98% of cases

#### Management :

Epithelial ovarian tumour

Stage IA, IB - Cytoreductive surgery

IC - IVB - Cytoreductive



6 cycles cisplatin/carboplatin + Paclitaxel

Germ cell / sex cord stroma

staging laparotomy



USO



4 - 6 cycles Bleomycin, Etoposide, Cisplatin

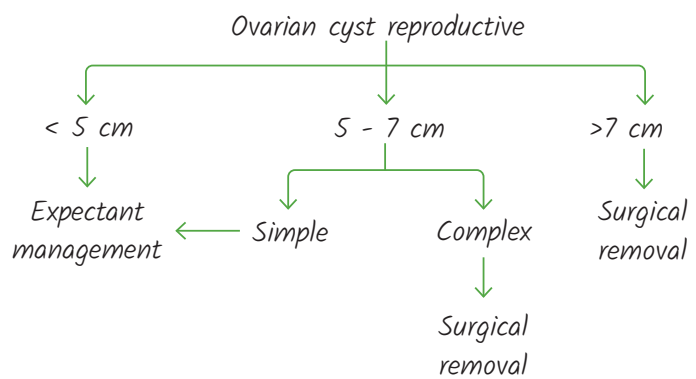
**Histologic Hallmarks of Ovarian Tumors**

Ovarian Tumor Characteristic	Histologic
Serous Epithelial tumors	Psammoma bodies
Clear cell tumors	Hobnail cells
Brenner tumors	Walthard cell rests
Dysgerminoma	Large polygonal cells
lymphocytic infiltration, and fibrous septa	
hair, cartilage, neural tissue, and thyroid	Skin, teeth, bones - Dermoid
Endodermal sinus tumor	Schiller-Duval bodies
Embryonal carcinoma	Embryoid bodies
Granulosa cell tumors	Call-Exner bodies
Leydig (hilus) cell tumors	Reinke's crystals
Krukenberg tumor	Signet ring cells

**Meigs' Syndrome**

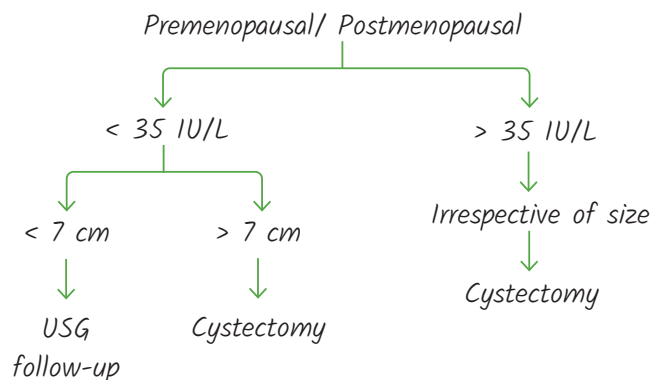
- Ascites
- +
- right side hydrothorax
- +
- fibroma,.

Ascites & hydrothorax when present in any other conditions is called Pseudo Meigs' syndrome.



**Q. A 22-year-old female with mobile 4 cm size ovarian cyst treatment is:**

- Laparotomy
- HRT
- Debulking
- Expectant management





### Endometrial Hyperplasia

Feature	Explanation	Progression To Cancer
SIMPLE WITHOUT ATYPIA	SIMPLE HYPERPLASIA NO DYSPLASIA A.K.A 'CYSTIC GLANDULAR HYPERTROPHY'	1% ( least )
COMPLEX WITHOUT ATYPIA	COMPLEX HYPERPLASIA NO DYSPLASIA	3%
SIMPLE WITH ATYPIA	SIMPLE HYPERPLASIA DYPLASTIC CELLS	8%
COMPLEX WITH ATYPIA	COMPLEX HYPERPLASIA DYSPLASTIC CELLS	29% (Maximum)

*Note: Brackets in the original image group 'SIMPLE WITHOUT ATYPIA' and 'COMPLEX WITHOUT ATYPIA' as 'Engined', and 'SIMPLE WITH ATYPIA' and 'COMPLEX WITH ATYPIA' as 'Hyst'.*

### Endometrial cancer

#### Young girls - megestrol acetate

#### Risk factors

- Early menarche
- Late menopause/
- PCOS
- Nulliparity
- Obesity
- Granulosa cell tumour

Tamoxifen  
Unopposed E2 in HRT  
DM + HTN + Endometrial Ca

Corpus cancer  
Syn

#### Protective factors

#### Family history

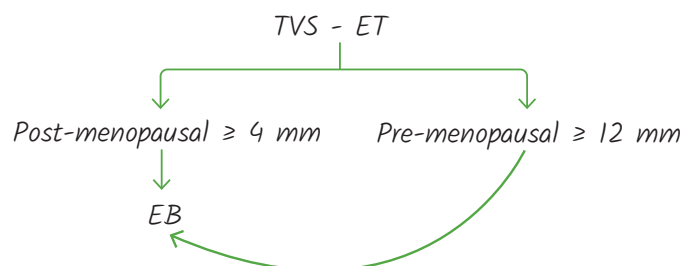
- Lynch
- Cowden

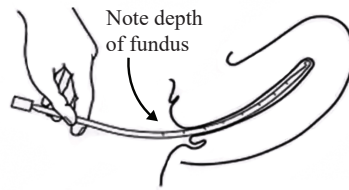
#### Protective :

- COCP
- Artificial menopause
- Multiparity
- Exercise
- Smoking

#### Types


#### Pipelle & Vabra





Withdraw plunger until 'stopped' to create vacuum. See text

We thank Genesis Medical Ltd for permission to reproduce the diagram

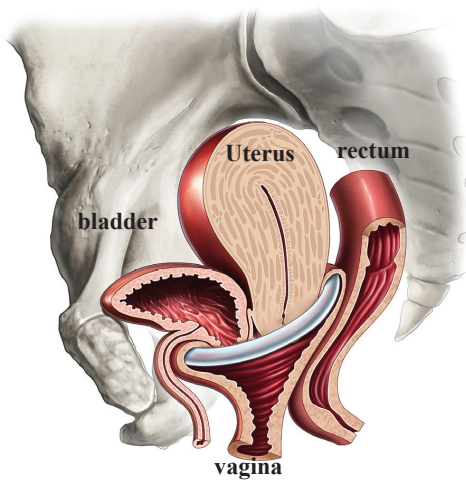


IOC offile  
Pipelle biopsy

Gold stand  
Hysteroscopic D and C

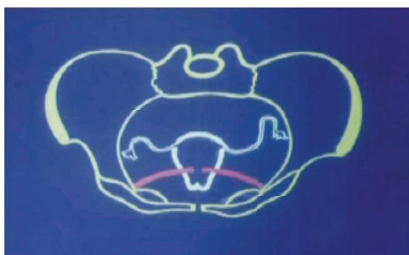
### Prolapse

- Prolapse is defined as the displacement of an organ from its normal anatomical position

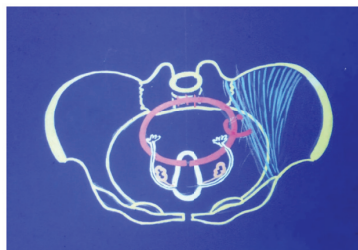




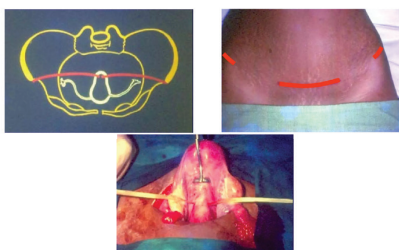
PURANDARE'S CERVIPEXY (1965)



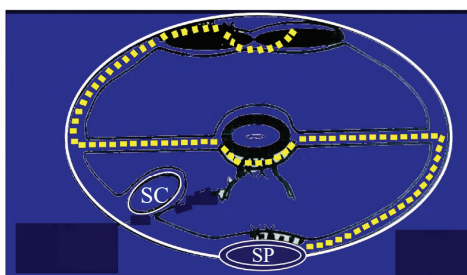
SHIRODKAR'S SLING OPERATION (1960)



Khanna's Posterior Sling Operation (1972)



Vir kud's Sling 1999



### Radical Surgery

- For old patients, family complete, postmenopausal women who are medically fit for surgery
  - Vaginal hysterectomy with or without anterior and posterior colporrhaphy is the best surgery:
  - Anterior colporrhaphy: repair of cystocele and cystourethrocele
  - Posterior colpoperineorrhaphy: repair of rectocele and lax perineum
  - Leforts surgery.
- |                                   |   |                                  |
|-----------------------------------|---|----------------------------------|
| • Young Nulliparous               | - | Sling surgeries                  |
| • Multiparous family comple       | - | Fothergills                      |
| Reproductive                      |   |                                  |
| 30-40Yrs                          |   |                                  |
| • Multipalous family comp Elderly | - | Vaginal hysterectomy             |
| • Elderly who is unfit for        | → | Bessaly →<br>Lefort colpocleisis |

**Q.** *In uterine prolapse, decubitus ulcer in the cervix is caused by:*

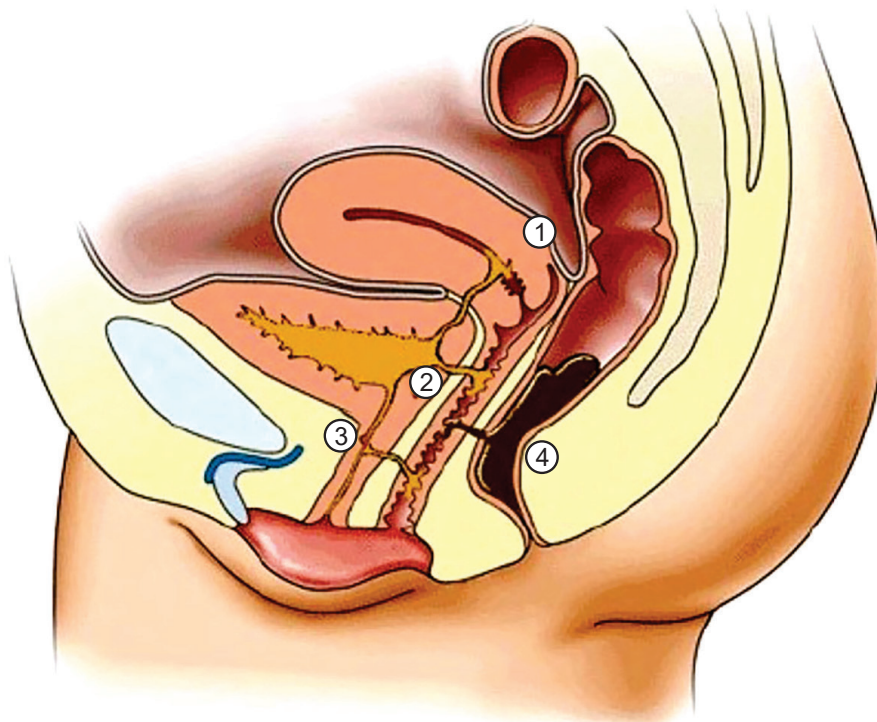
- a. Friction
- b. Malignant change
- c. Venous congestion
- d. Trophic changes

**Q.** *A young nulliparous woman had 3rd degree of uterovaginal prolapse without any cystocele or rectocele. There is no stress incontinence. The uterus is retroverted. Uterocervical length is 3 inches. All other symptoms are normal. The best treatment plan for her will be:*

- a. Observation and reassurance till child bearing is over
- b. Shirodkar's vaginal repair
- c. Shirodkar's abdominal sling
- d. Fothergill's operation

### Genital Fistula

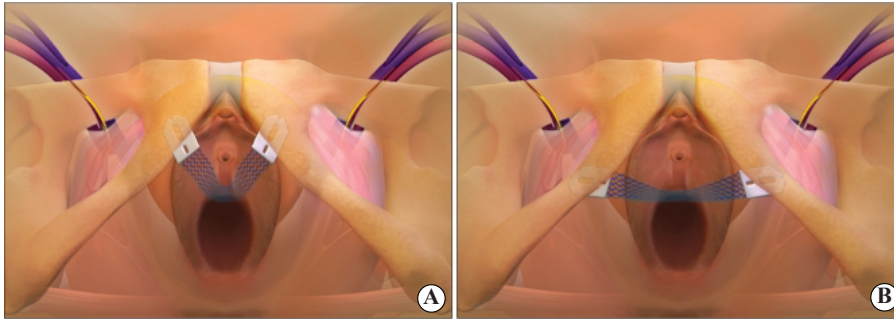
- 1. Vesicouterine fistula
- 2. Vesicovaginal fistula
- 3. Urethrovaginal fistula
- 4. Rectovaginal fistula





### **Vesicovaginal Fistula**

- *MC cause - obstructed labour*
- *C/P continuous passage of urine from vagina*  
*No voluntary micturition*  
*+*
- *IOC cystoscopy*
- *$\Delta$  sed < 24 hrs repair immediately*  
*> 24 hrs repair after 6 weeks*
- *Latz KO/ Three layer technique*
- *Post repair suprapubic catheterisation for 2 weeks*
- *Avoid coitus for 3 months*
- *Avoid preg for 1 yr*



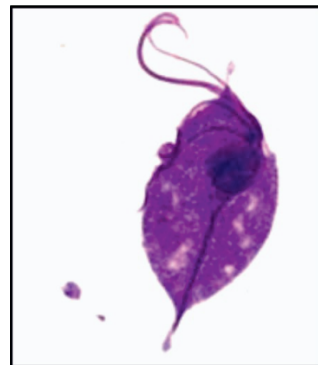
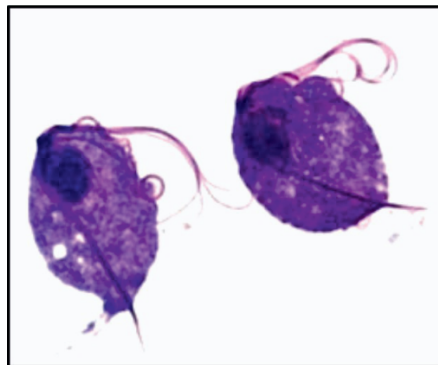
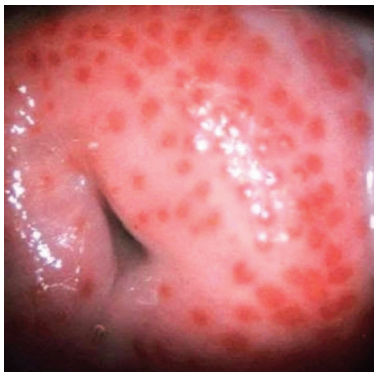
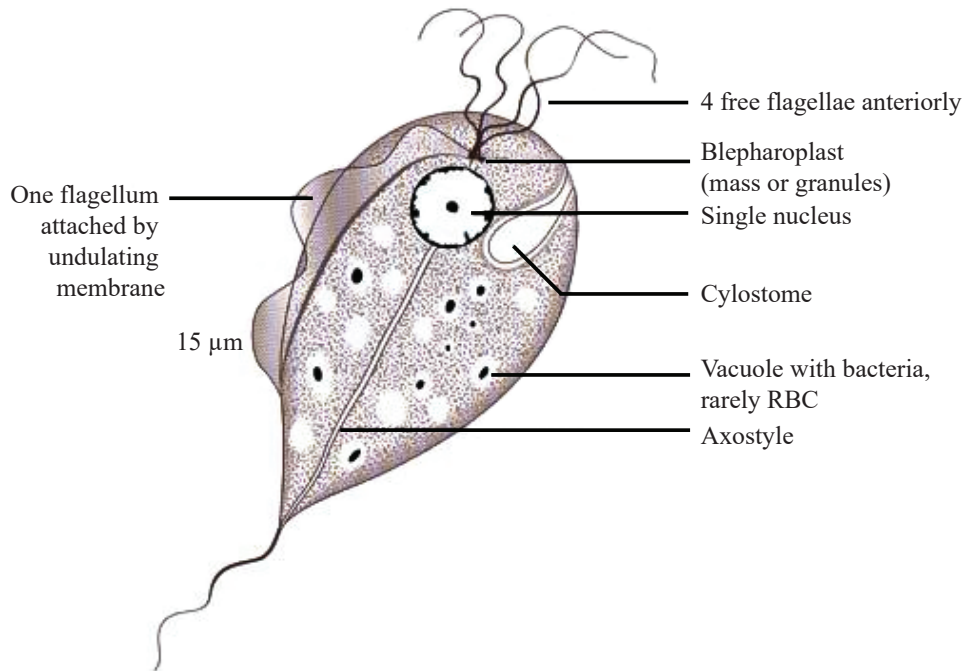
*Trans obturator tape > Transvaginal tape > Burch calposuspension*

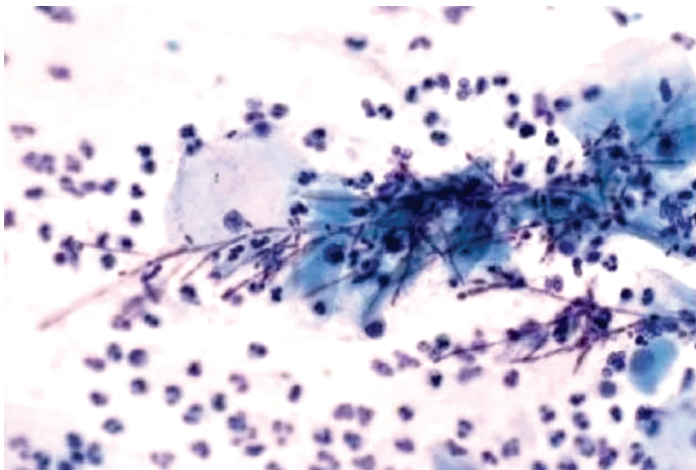
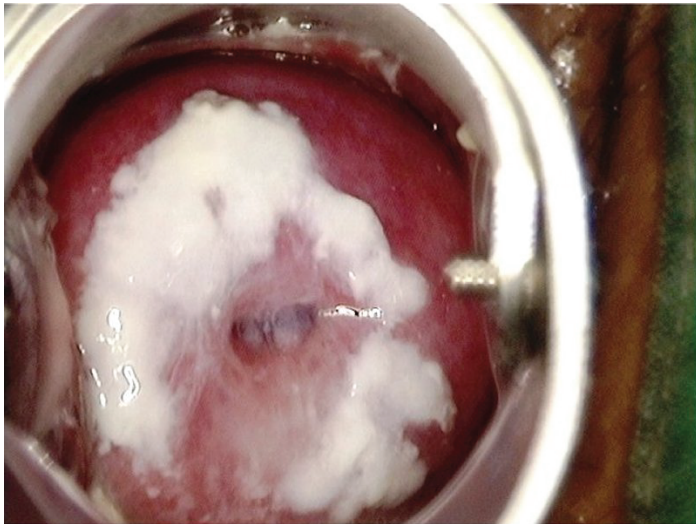
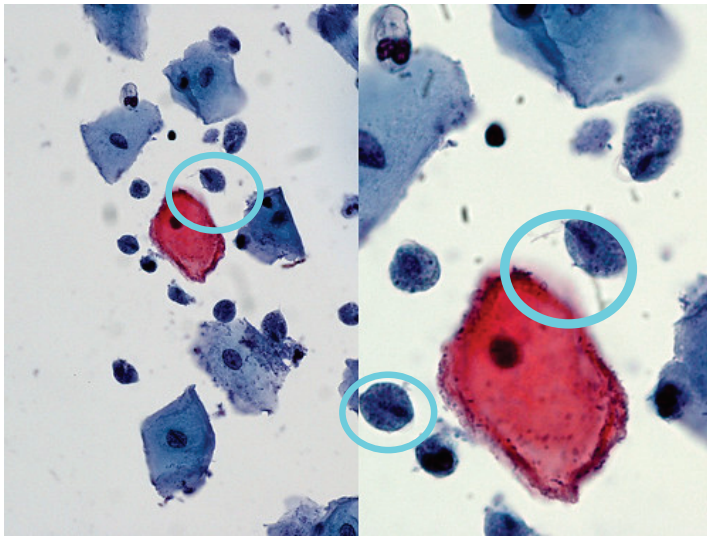
**Q.** “*Strawberry cervix*” or vagina is feature of:

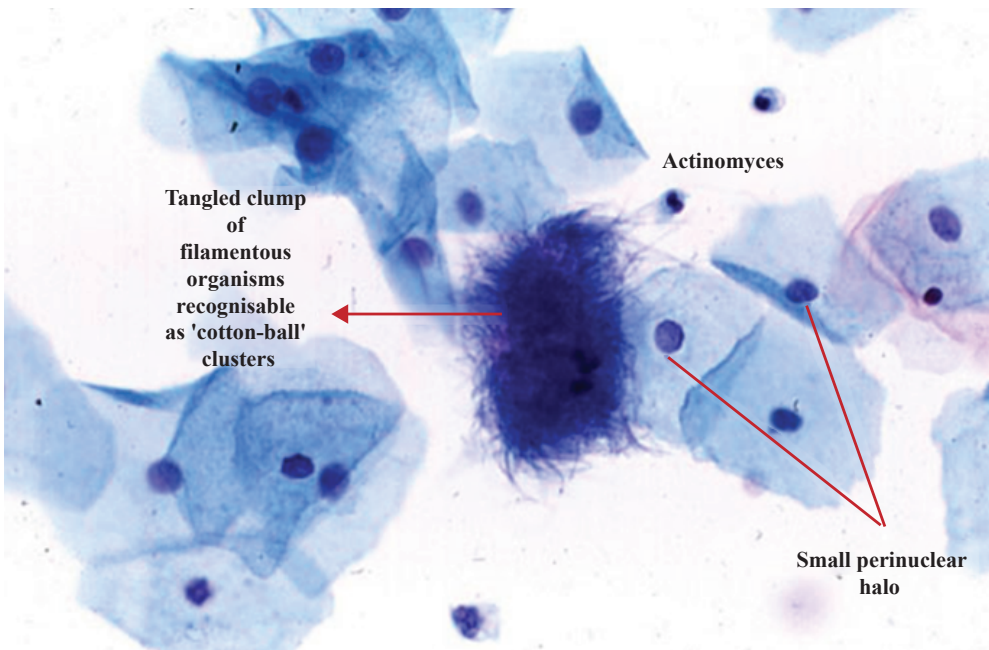
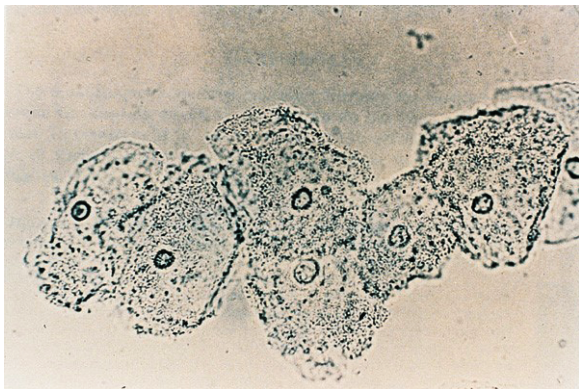
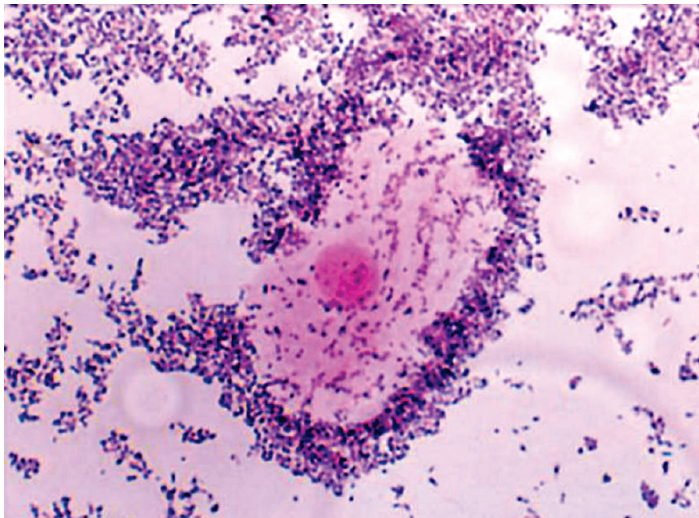
- a. *Vaginal candidiasis*
- b. *HSV infection*
- c. *Bacterial vaginosis*
- d. *Trichomonas vaginitis*



*Infections*







	<b>TRICHOMONAS</b>	<b>CANDIDIASIS</b>	<b>BACTERIAL VAGINOSIS</b>	
DISCHARGE	GREEN COLORED + PRURITIS	CURDY WHITE DISCHARGE+PRURITIS	GREY WHITEFOUL SMELLING DISCHARGE	
	STRAWBERRY CERVIX		AMSELS CRITERIA : PH>4.5 GREY WHITE DISCHARGE WHIFF TEST POSITIVE CLUE CELLS	
IOC	SALINE MICROSCOPY	SALINE MICROSCOPY		
GOLD STANDARD	DIAMONDS MEDIA	SABOURAUD AGAR	NUGENT CRITERIA	
TOC	METRONIDAZOLE	FLUCONAZOLE	METRONIDAZOLE	

<b>CHARACTERSTIC</b>	<b>SYPHILIS</b>	<b>LYMPHO GRANULOMA VENERAM</b>	<b>GRANULOMA INGUINAL</b>	<b>HERPES</b>	<b>CHANCROID</b>
C.ORG	T.PALLIDUM	C.TRACHOMATIS LIL2L3	K.DONOVANI	HSV TYPE 1/2	H.DUCREYI
NO PAIN	SINGLE PAINLESS	SINGLE PAINLESS	VARIABLE PAINLESS	MULTIPLE PRESENT	MULTIPLE PRESENT
EDGES	ELEVATED SHARP	ELEVATED ROUND TO OVAL	ELEVATED IRREGULAR	ERYTHEMATOUS	UNDERMINED RAGGED
BASE	SMOOTH NONPURULENT	VARIABLE	RED VELVETY BLEEDS ON TOUCH	ERYTHEMATOUS	PURULENT
DEPTH	SUPERFICIAL OR DEEP	SUPERFICIAL OR DEEP	ELEVATED	SUPERFICIAL	EXCAVATED
LYMPH NODES	B/L NON TENDER	UNILATERAL TENDER	NONE PSEUDO BUBO SEEN	B/L TENDER	U/L TENDER



## NOTES



NOTES