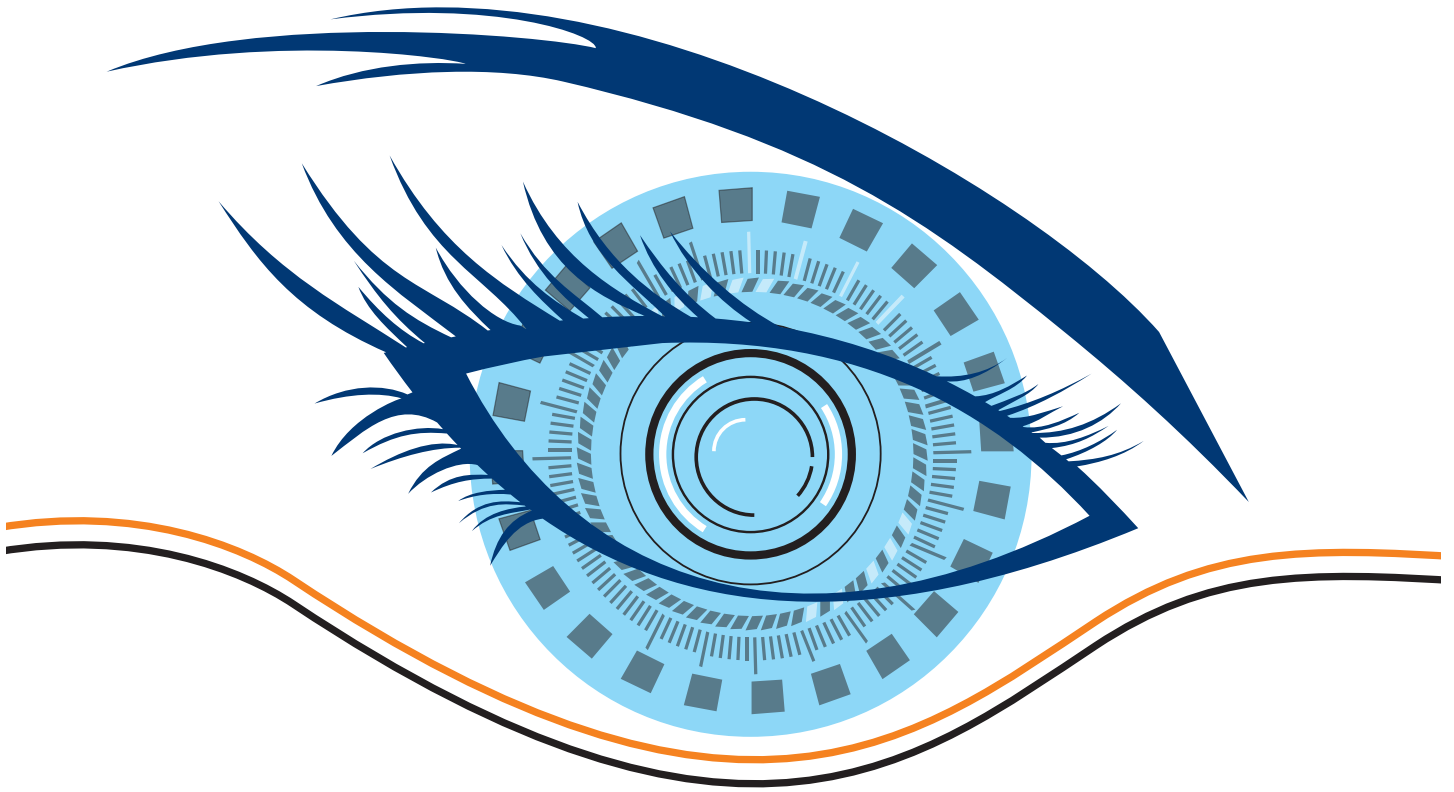




OneShot 4.0
Ophthalmology



OPHTHALMOLOGY

<i>Sl. No.</i>	<i>CHAPTER</i>	<i>Page No.</i>
1.	<i>Anatomy and Development</i>	389
2.	<i>Lens</i>	391
3.	<i>Glaucoma</i>	401
4.	<i>Uveitis</i>	407
5.	<i>Retina</i>	409
6.	<i>Neuro Ophthalmology</i>	431
7.	<i>Squint</i>	437
8.	<i>Conjunctiva</i>	445
9.	<i>Cornea</i>	457
10.	<i>Sclera</i>	467
11.	<i>Trauma</i>	473
12.	<i>Eyelids</i>	485
13.	<i>Orbit</i>	493

“

Shoot
for the moon.
Even if you miss,
you'll land
among the
stars.

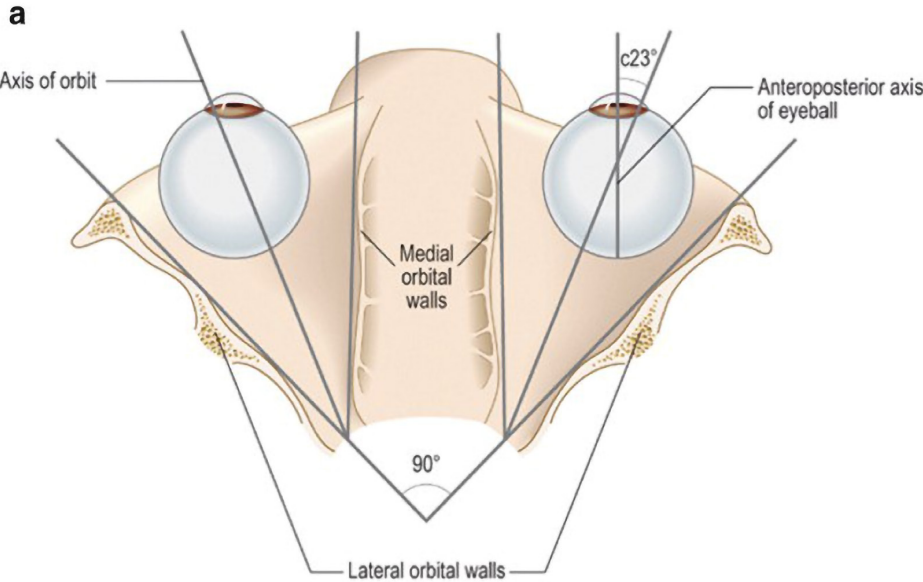
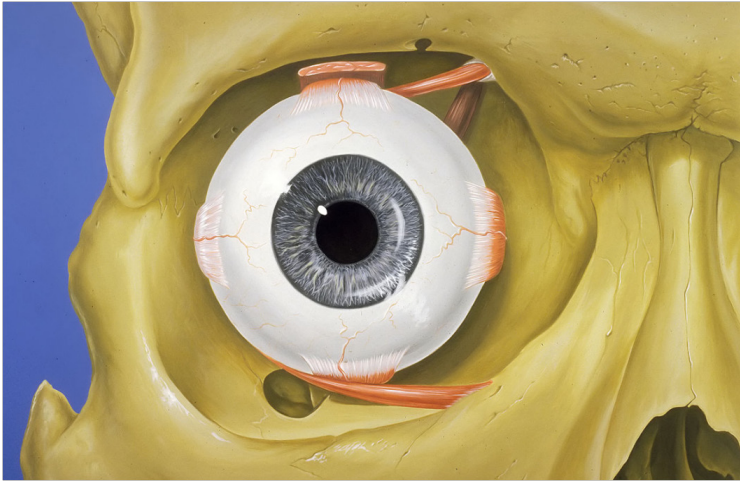
- Dr. Niha Aggarwal

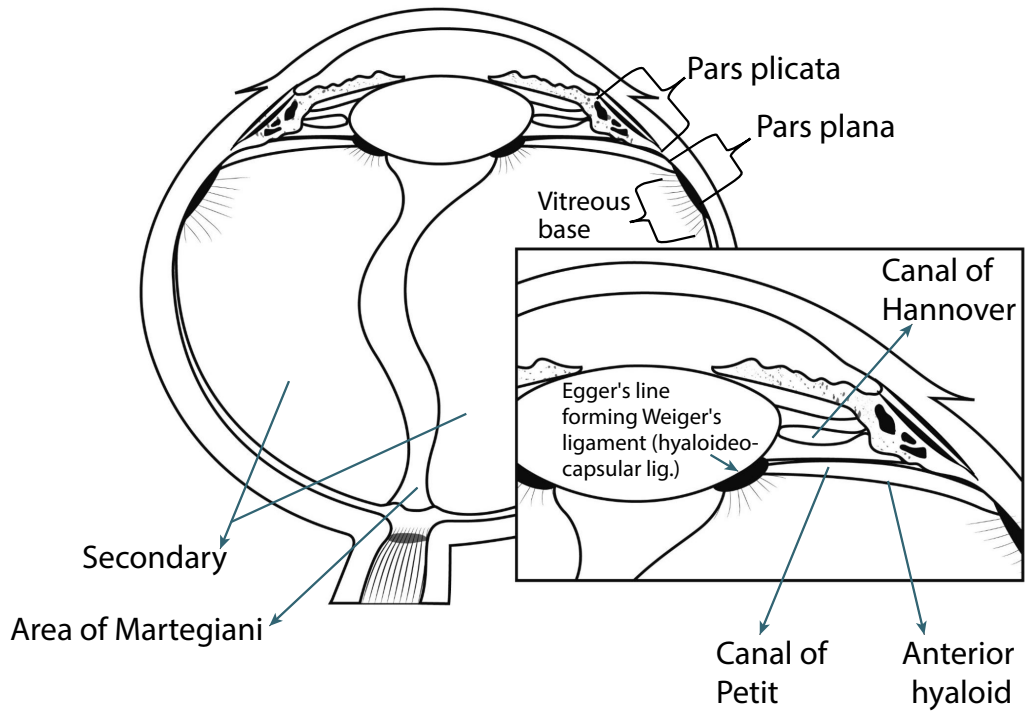
”





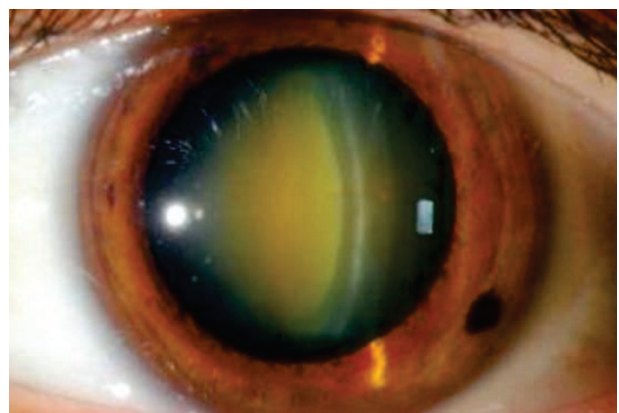
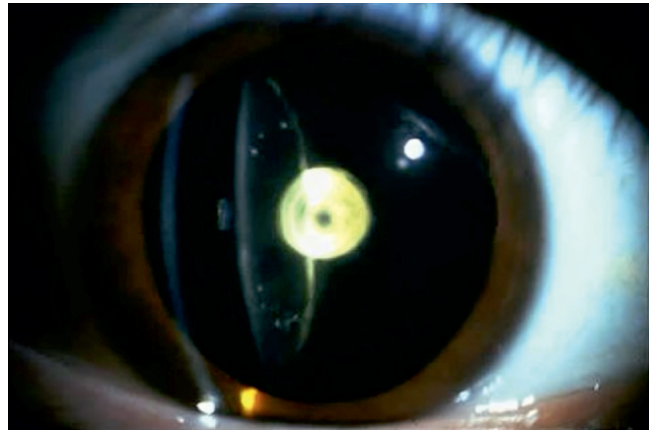
ANATOMY AND DEVELOPMENT

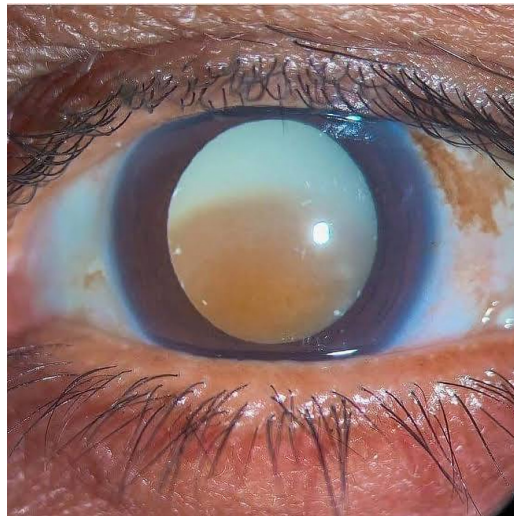
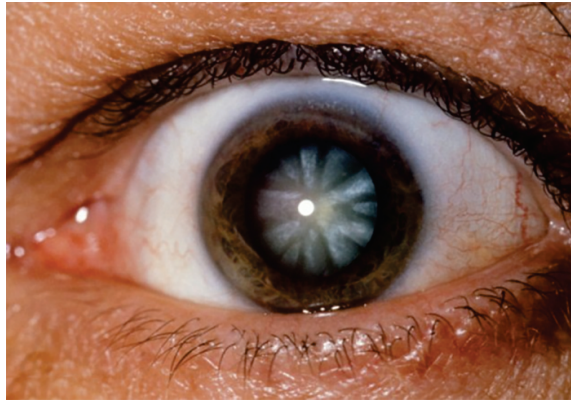

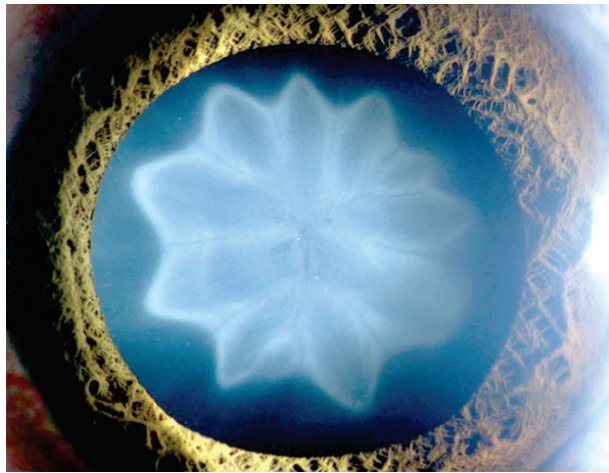
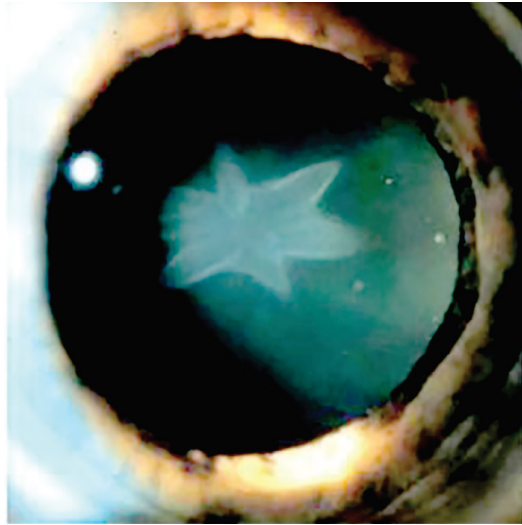


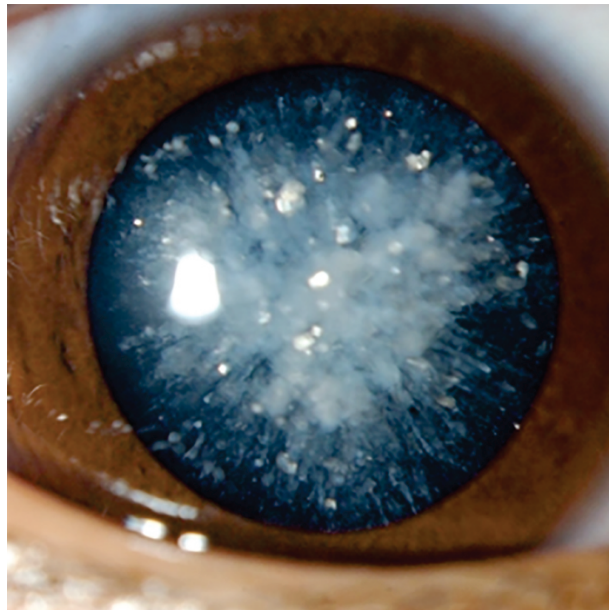
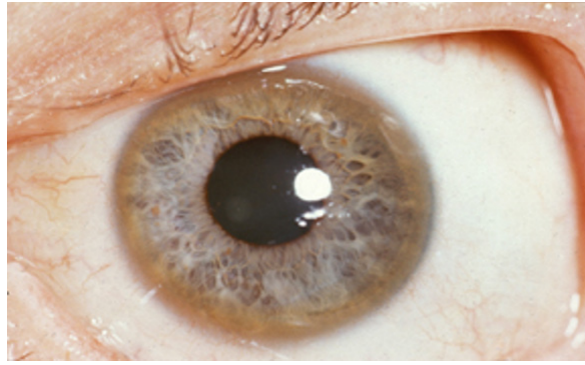



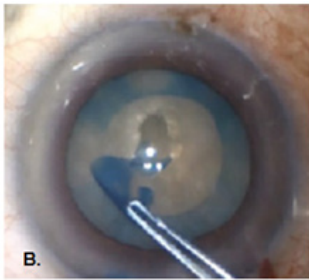
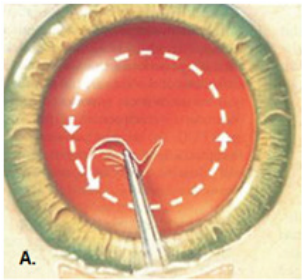
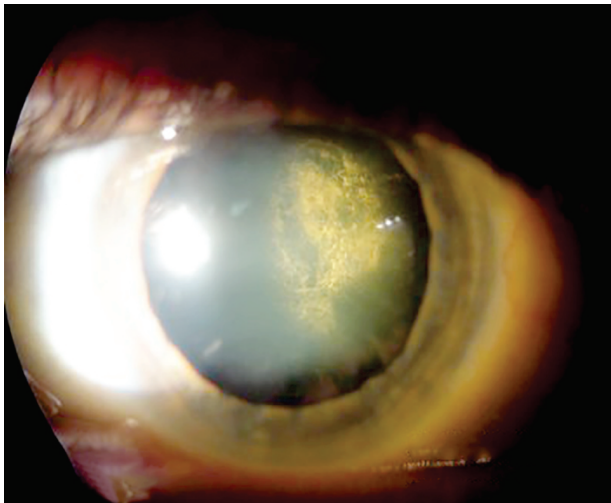LENS

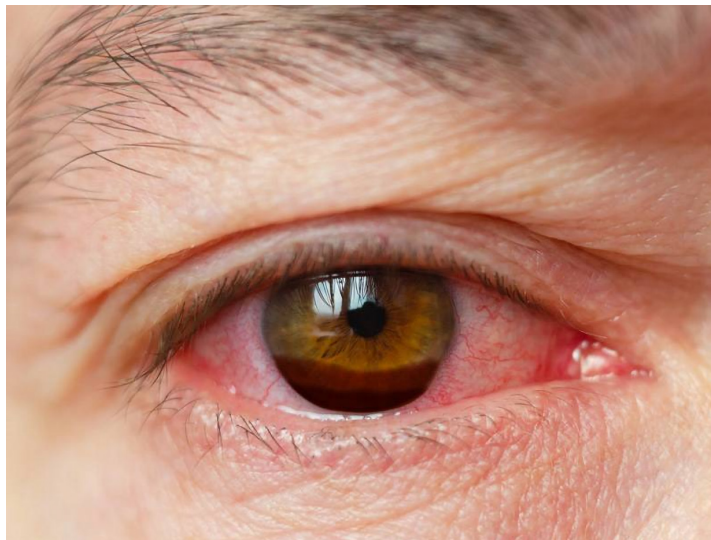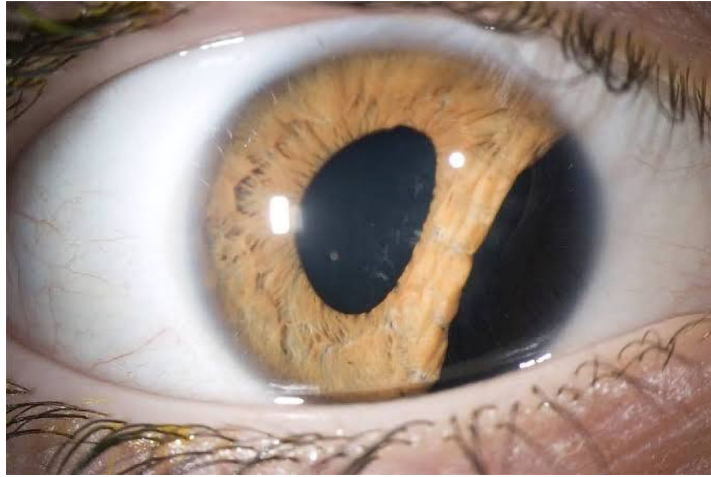


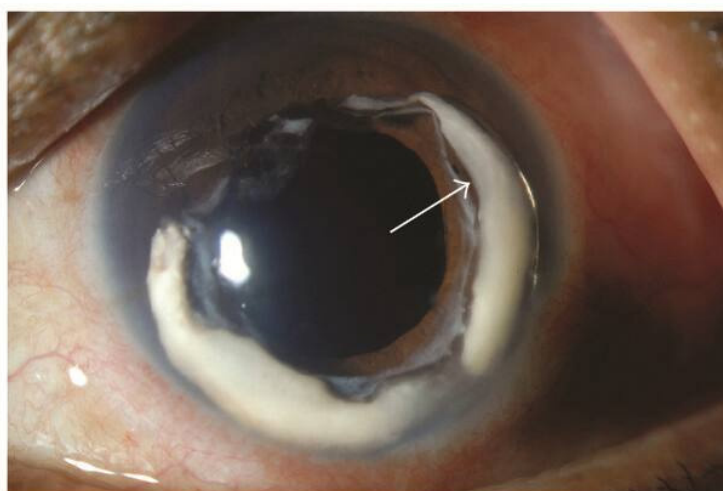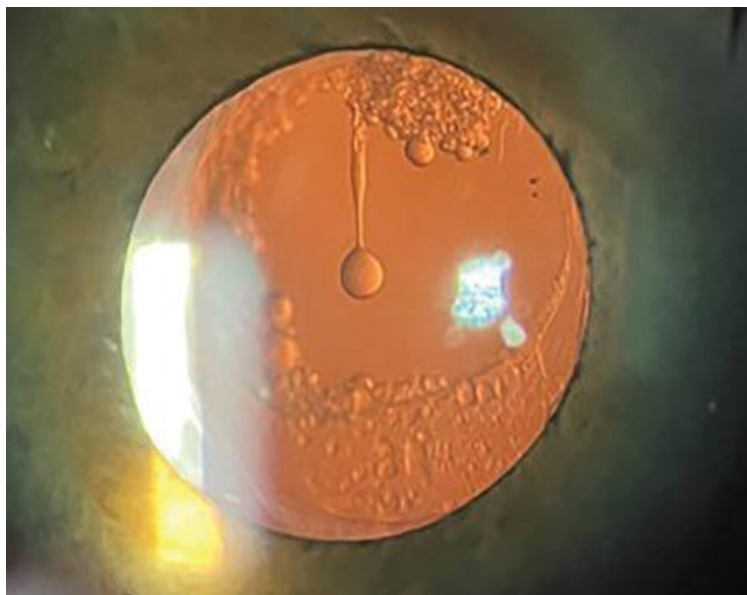


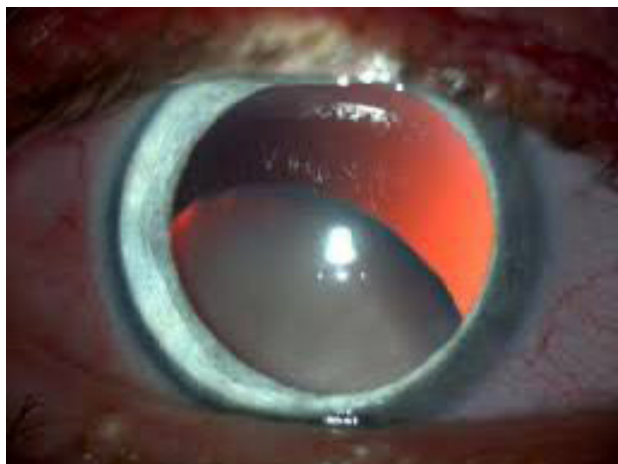


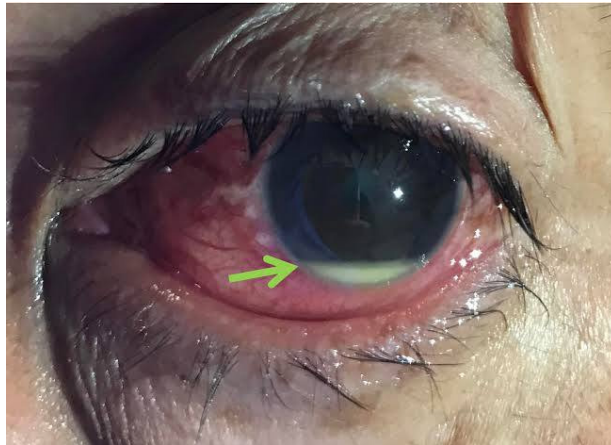
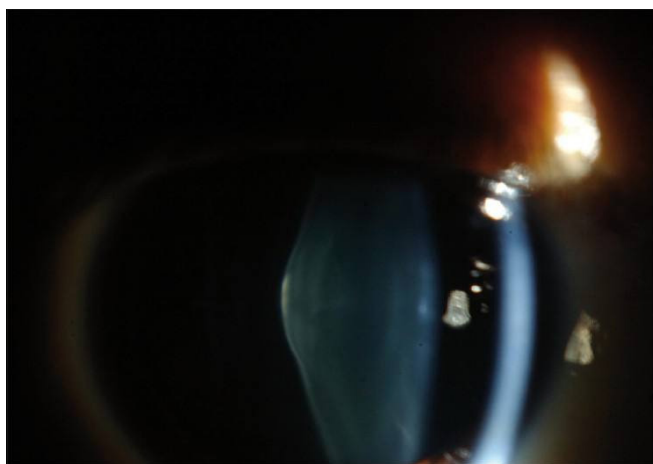


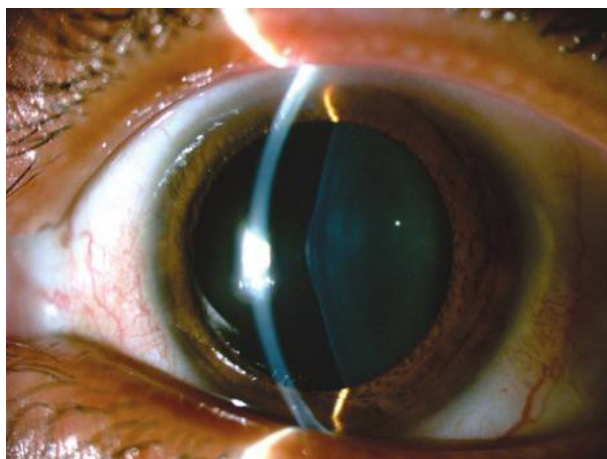










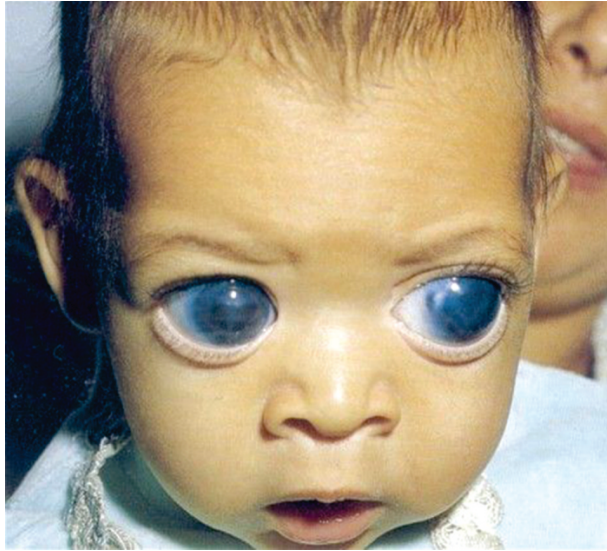
NOTES

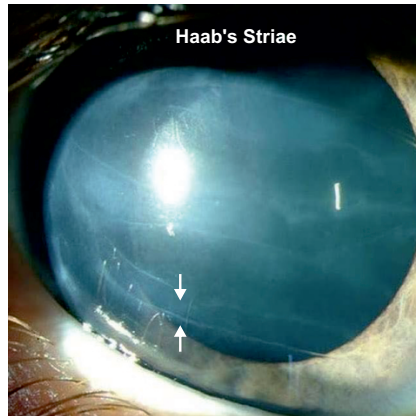
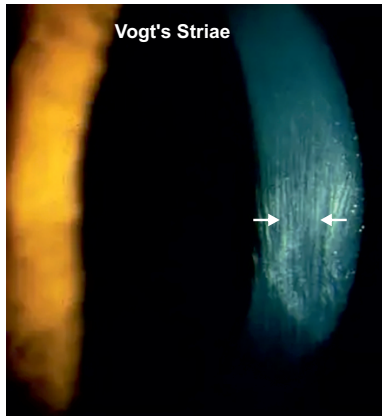


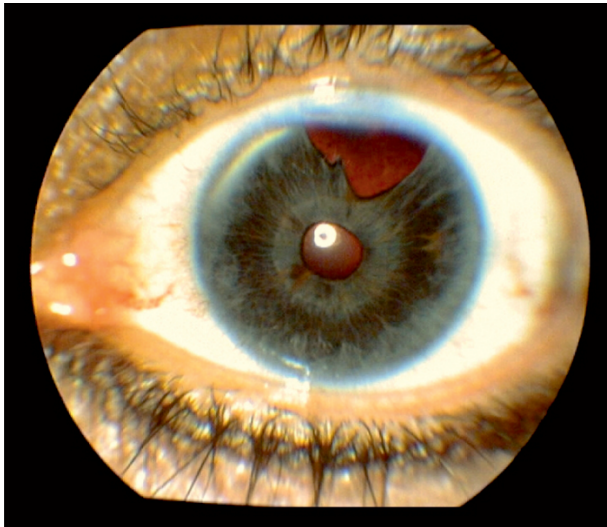
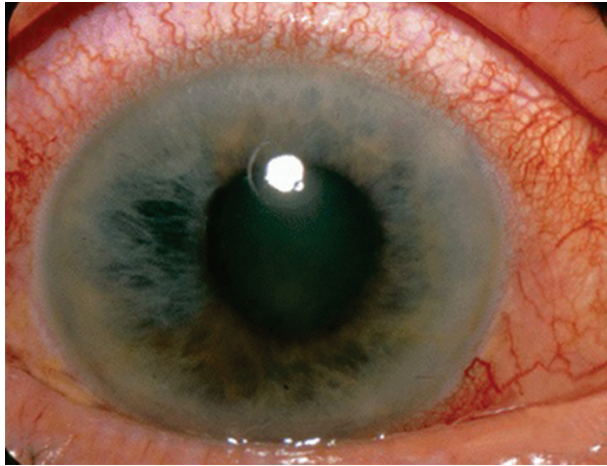
GLAUCOMA

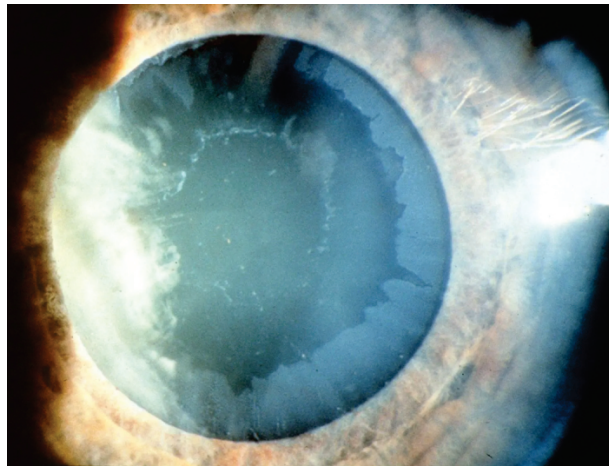
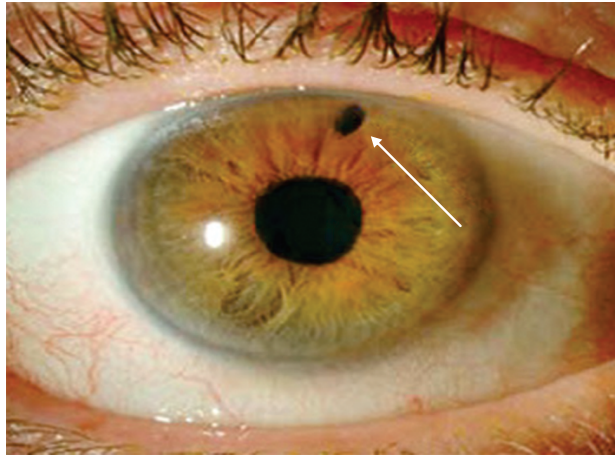


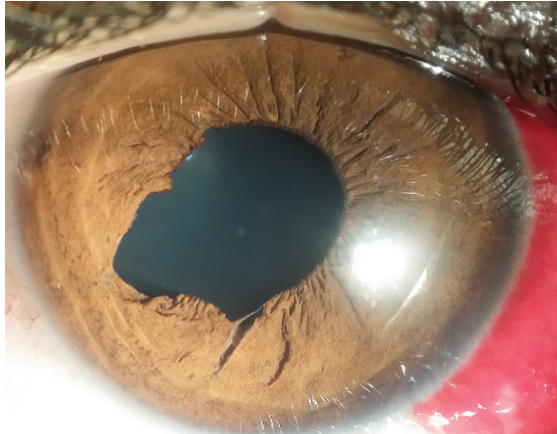
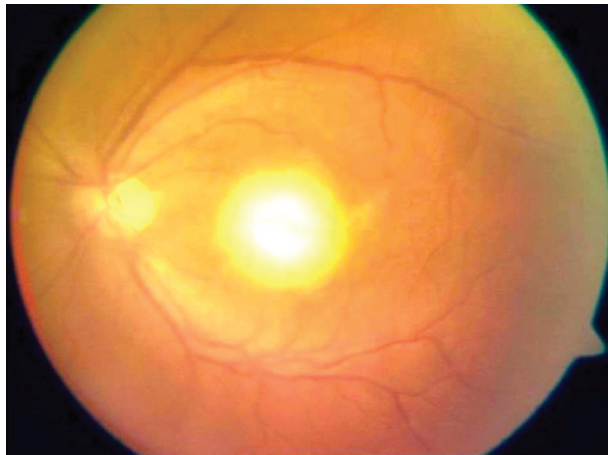


Vogt's Striae & Haab's Striae







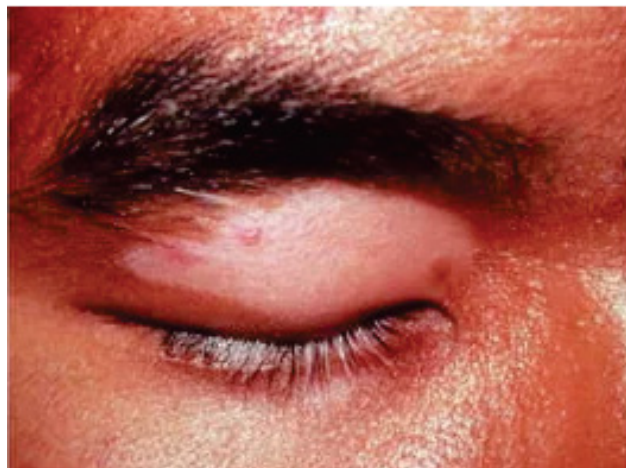
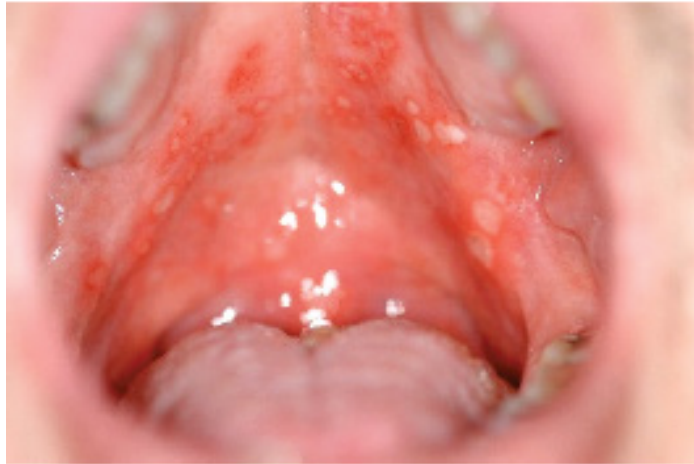


NOTES



UVEITIS

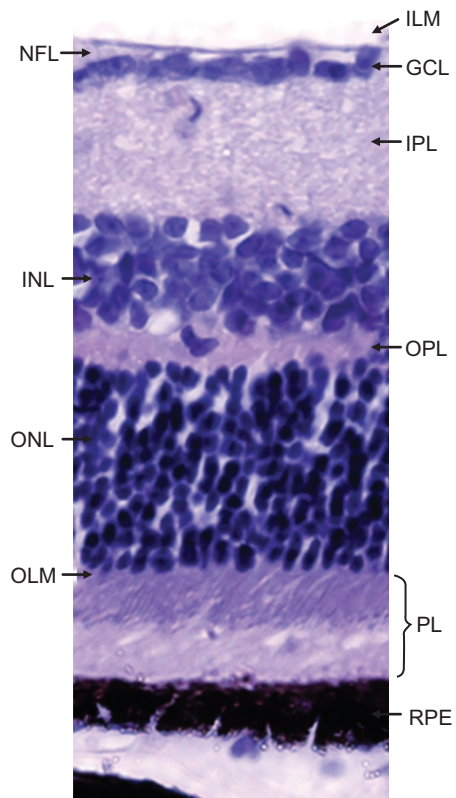
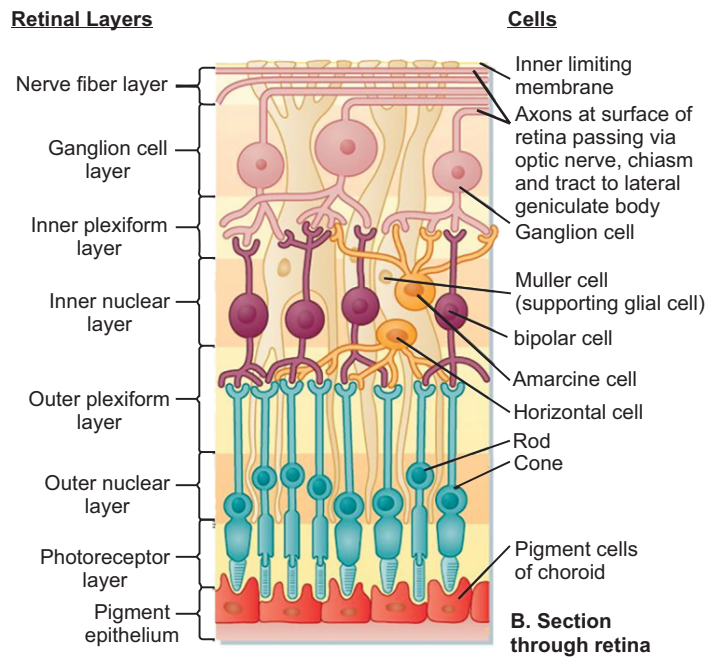


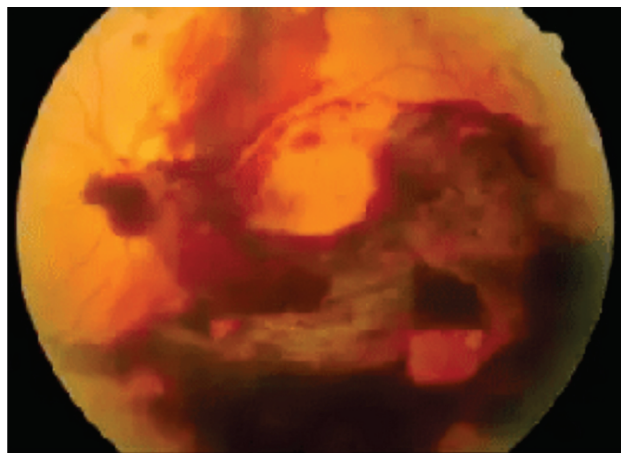
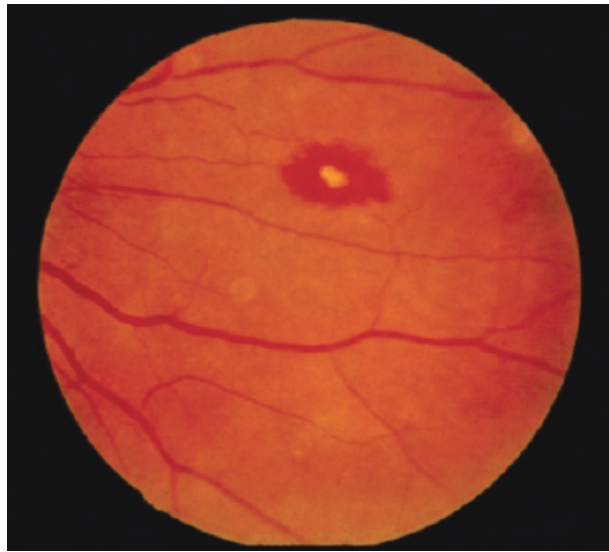


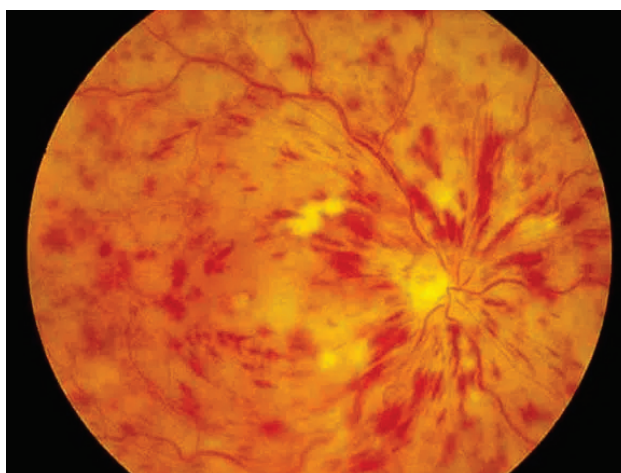
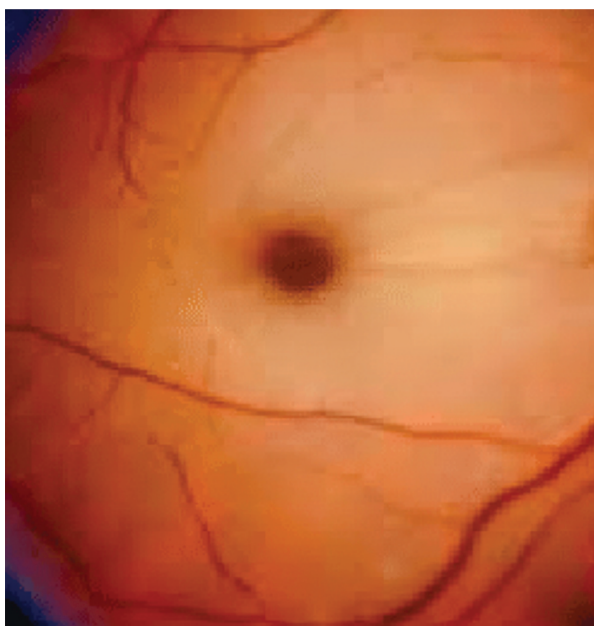
NOTES

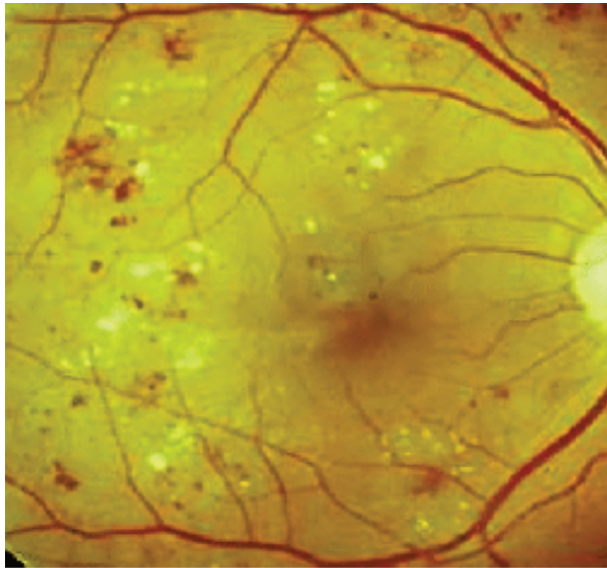
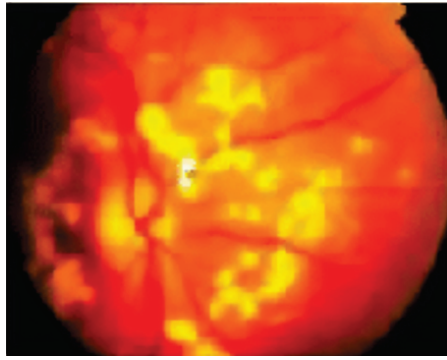
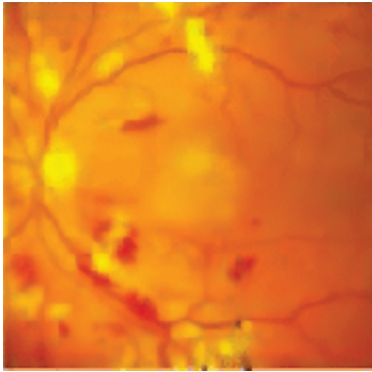


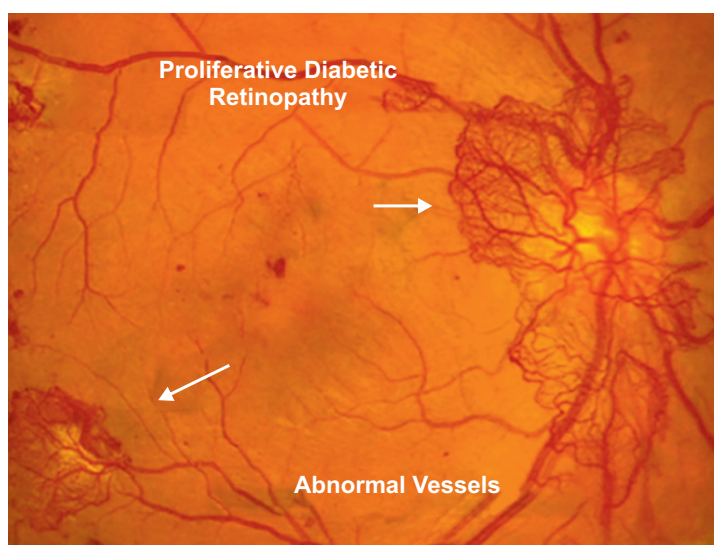
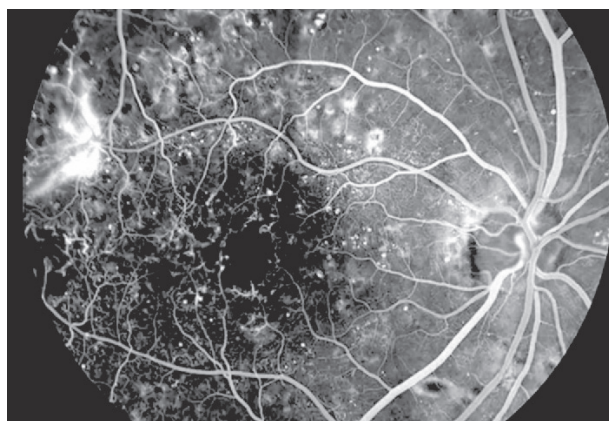
RETINA

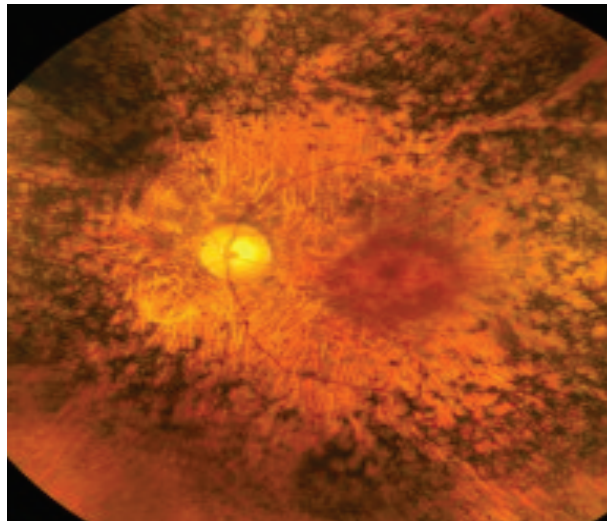
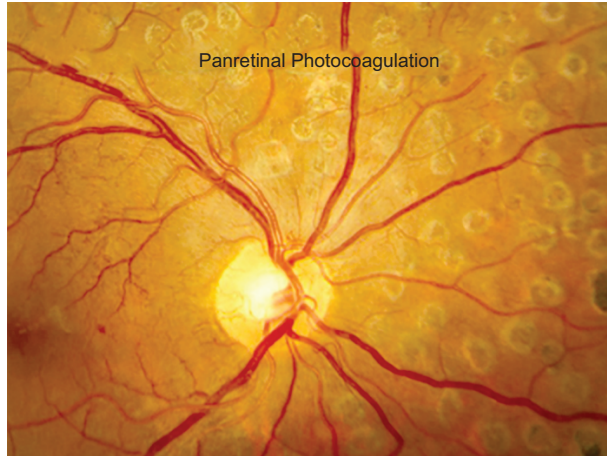


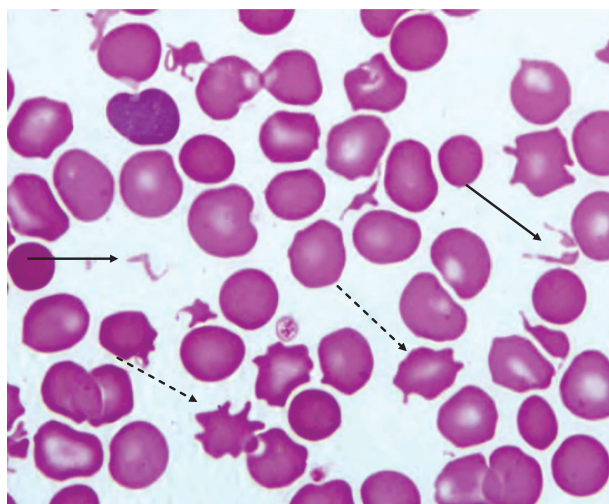
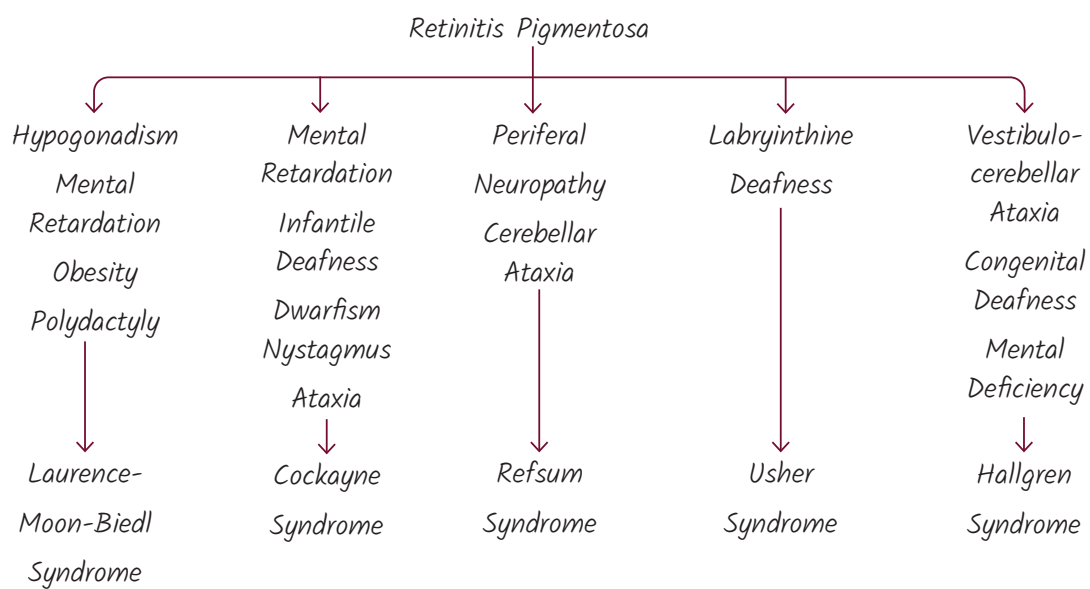


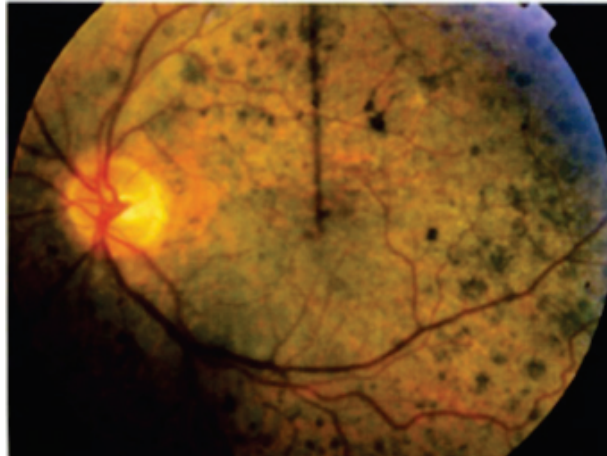






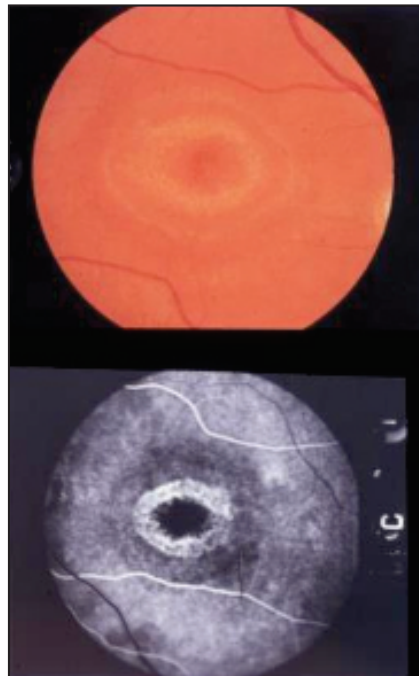


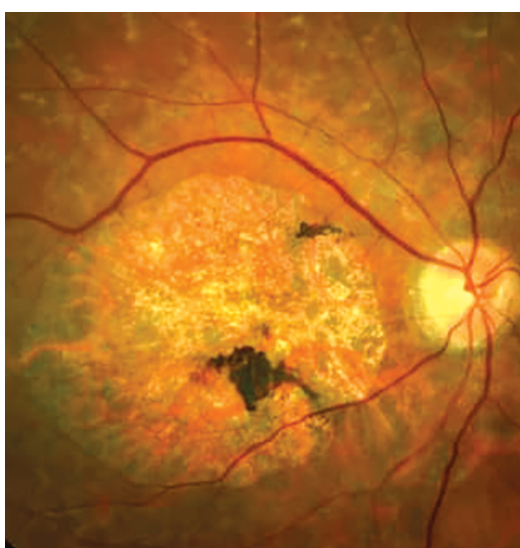
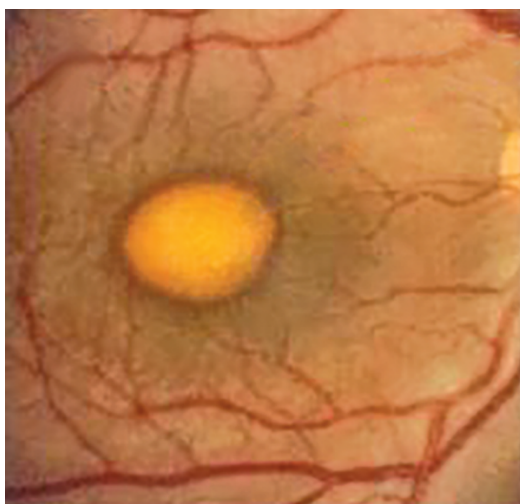


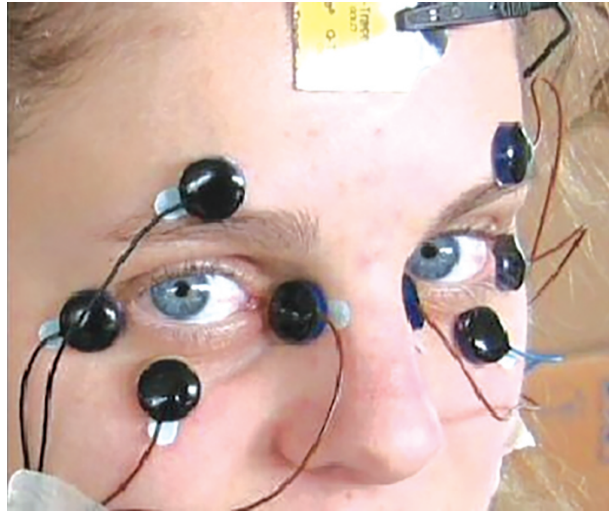


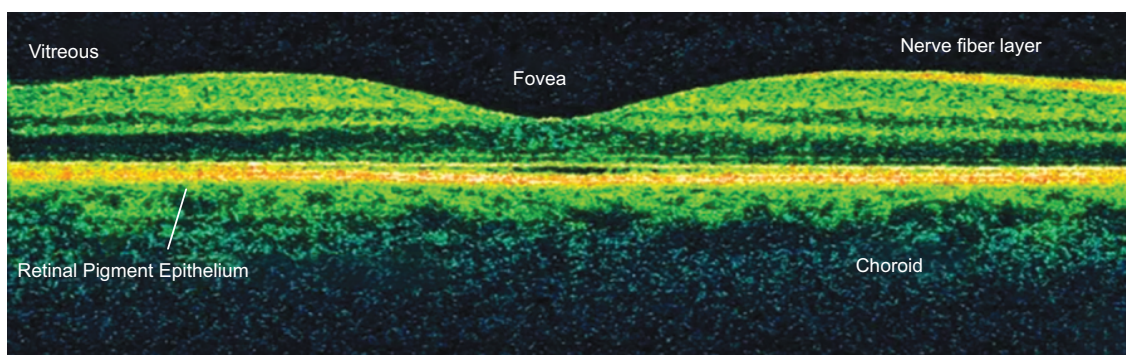
"Bull's Eye" Maculopathy

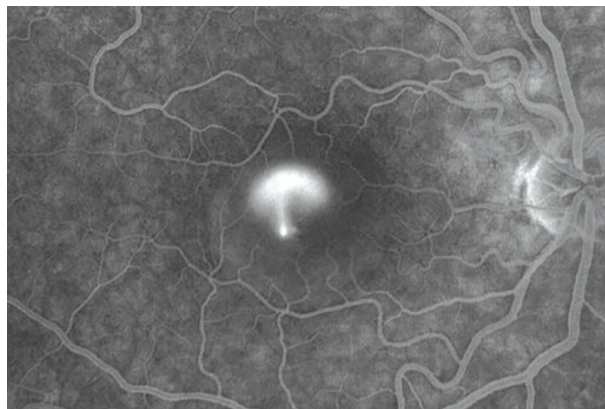
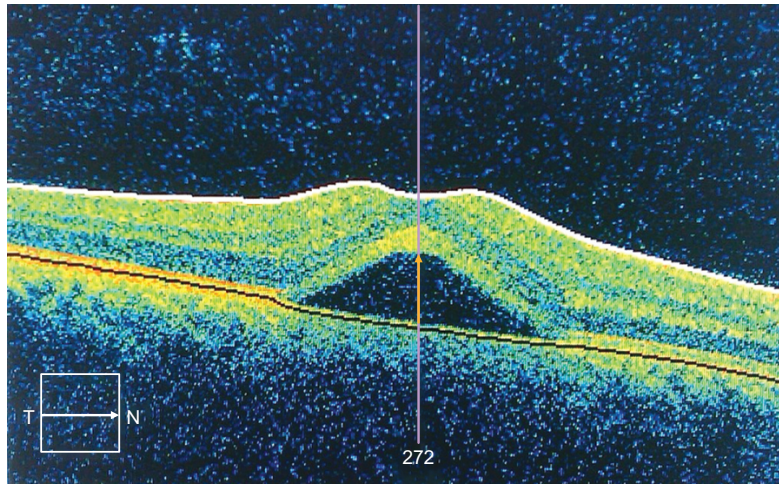
- Patient presents with fundus & FA findings.
- Patient taking 500mg/day hydroxychloroquine
- What is the diagnosis/ prognosis for this patient?

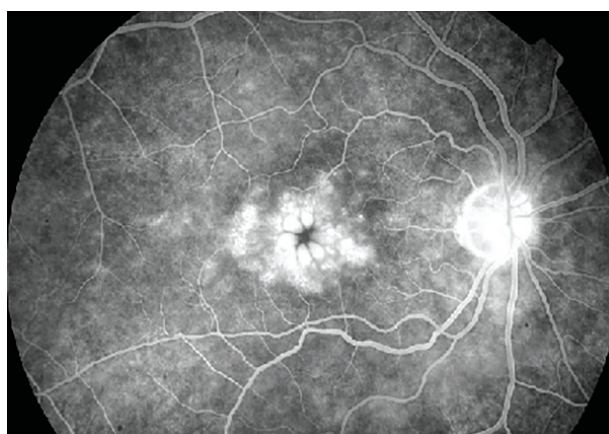
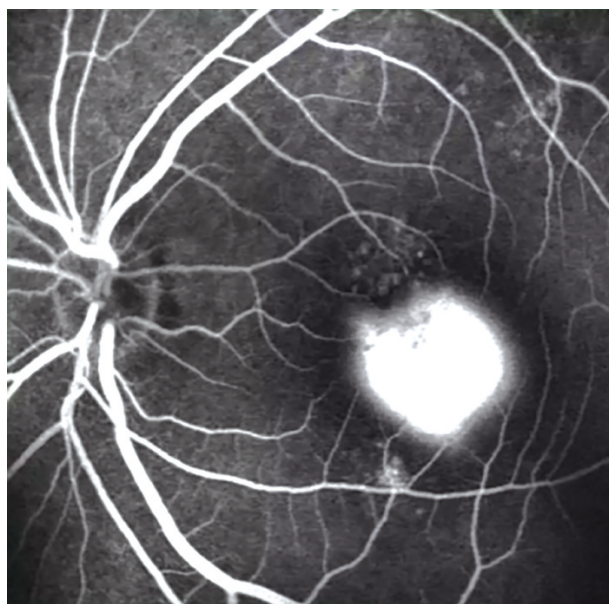
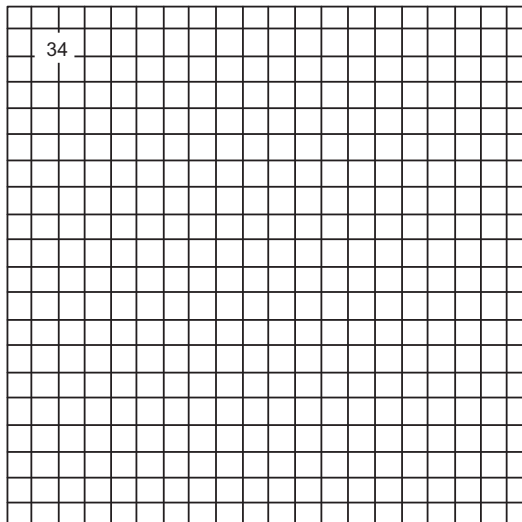
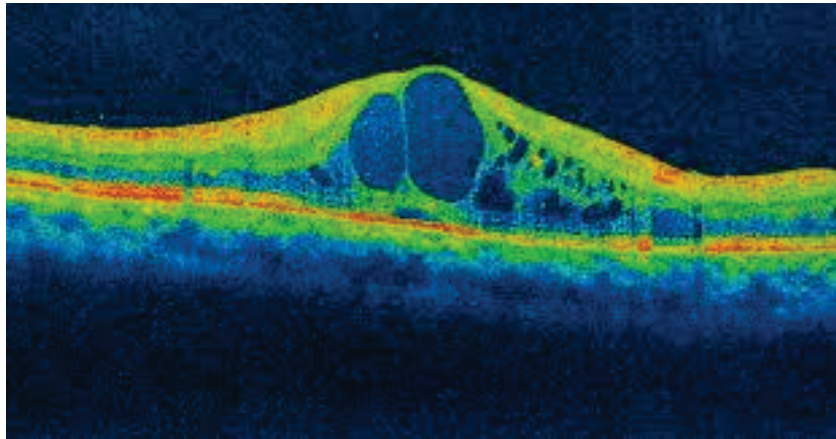


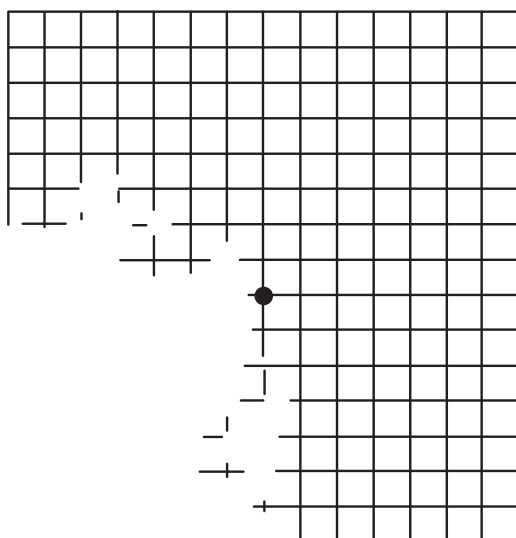
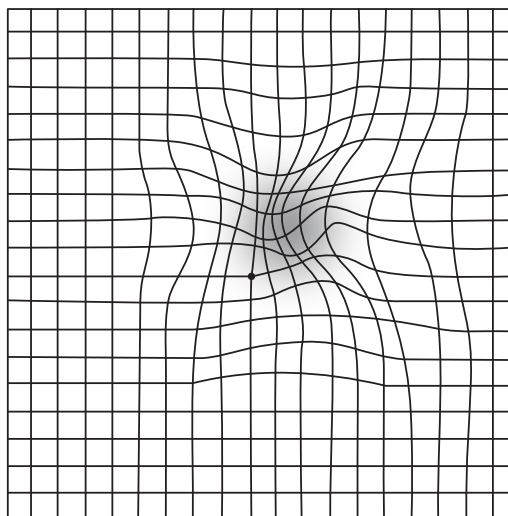


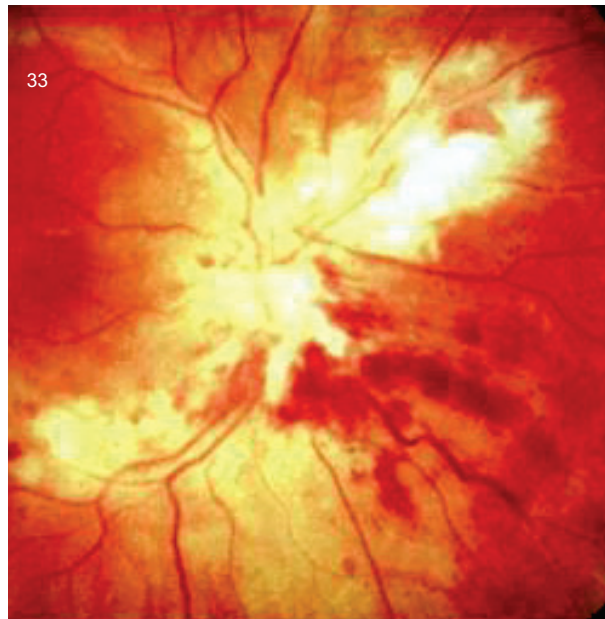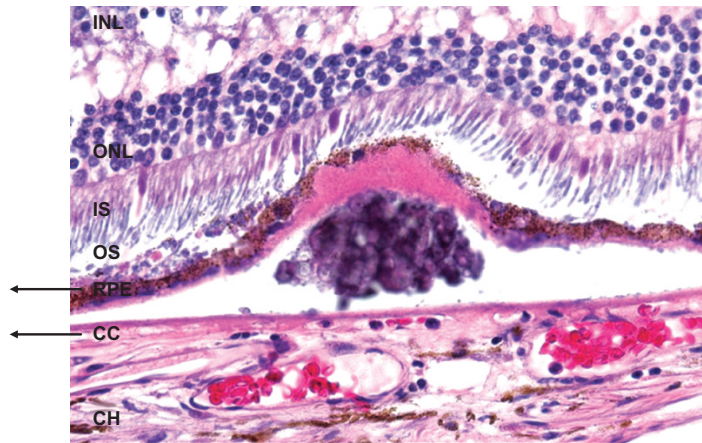


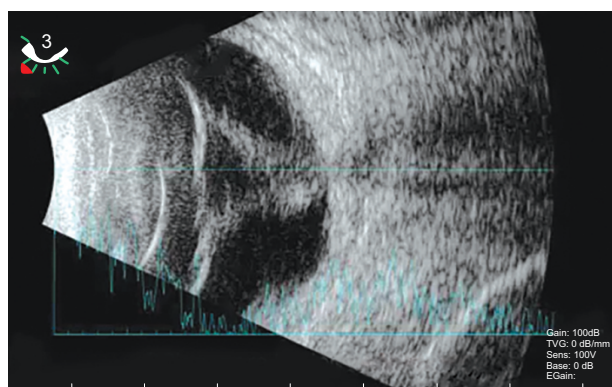


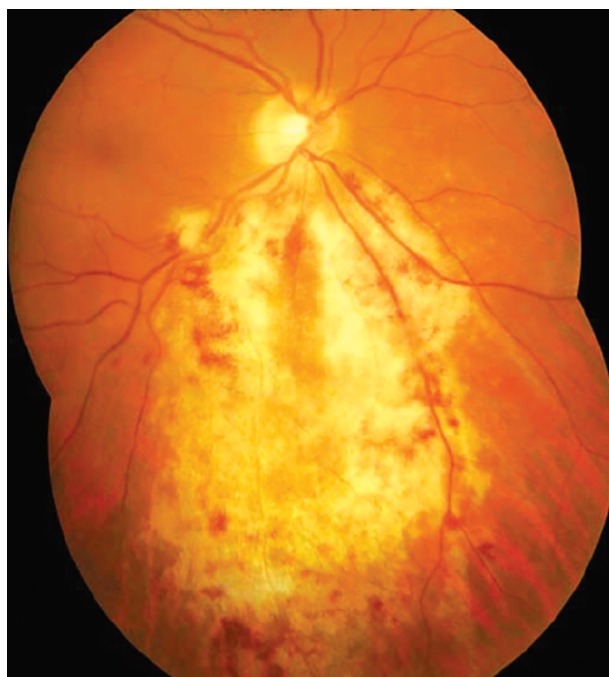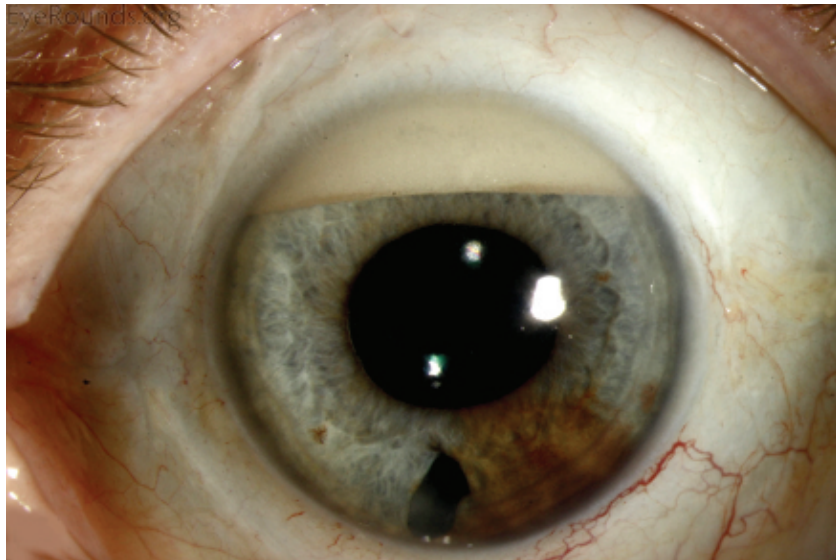




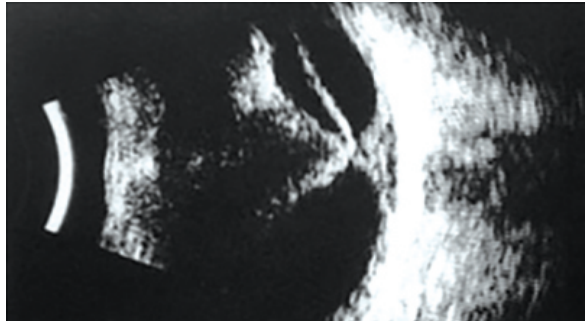


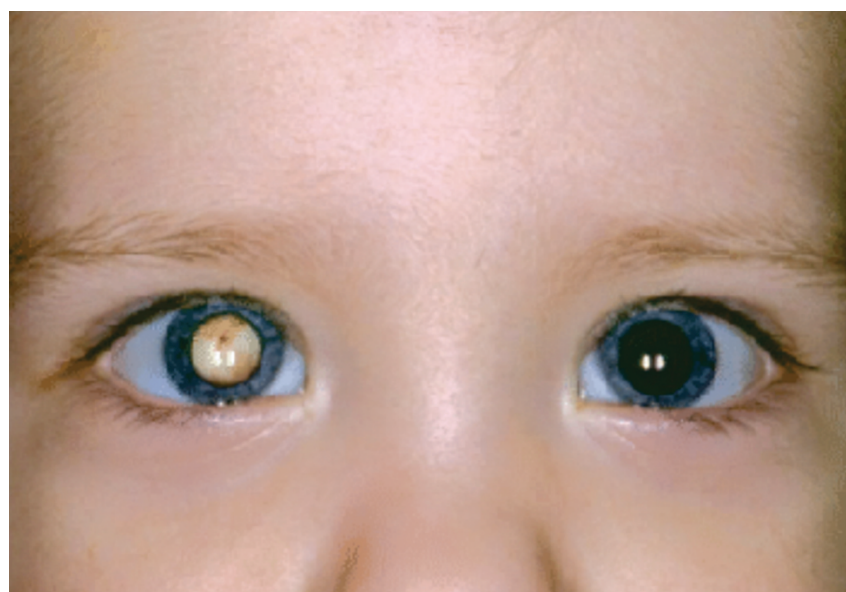
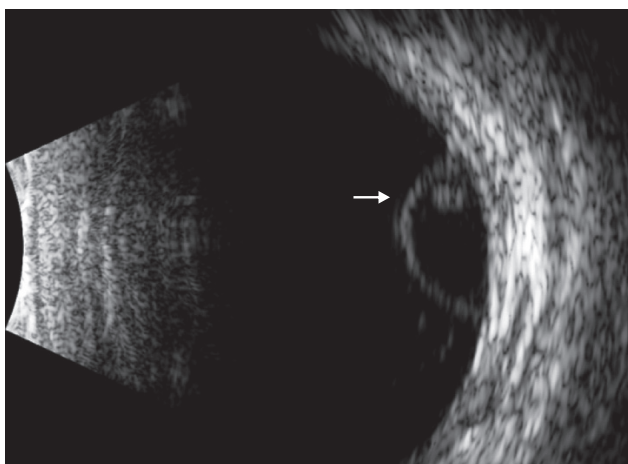


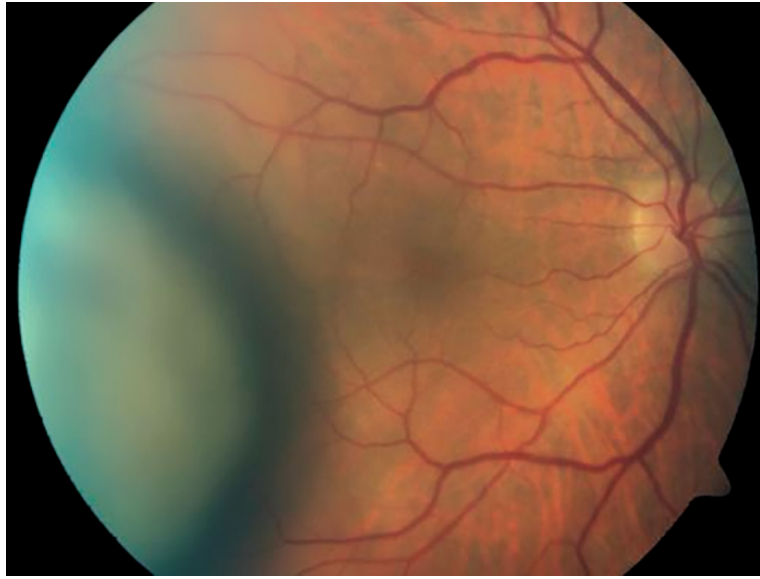




Tent-like TRD









NOTES

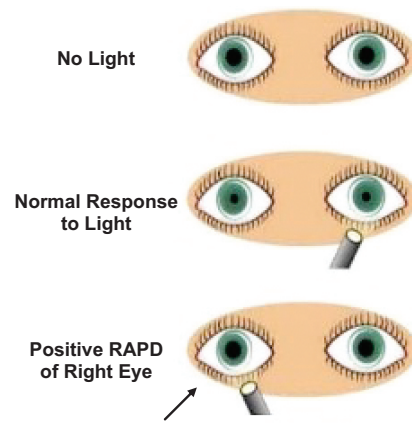


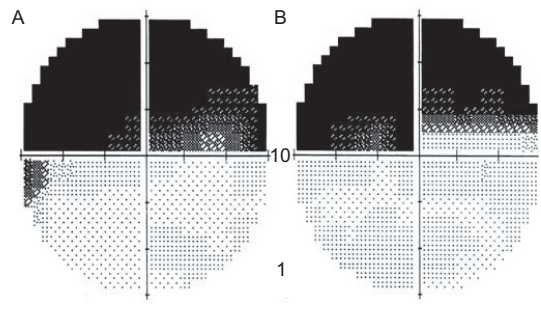
NOTES



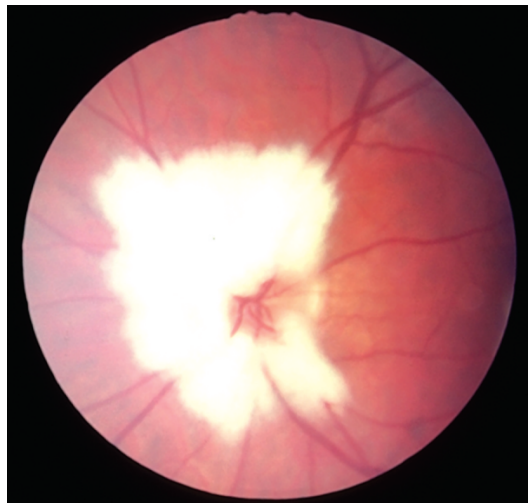
NEURO OPHTHALMOLOGY

VISUAL PATHWAY DEFECT

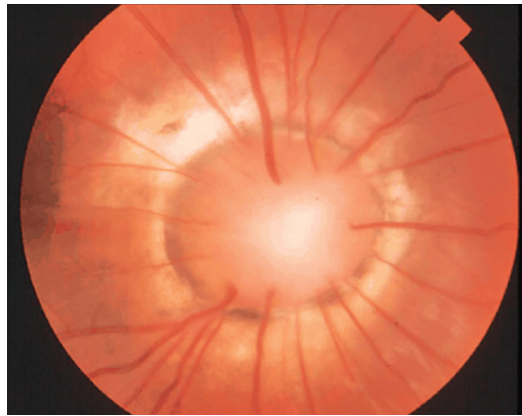





Altitudinal Hemianopia



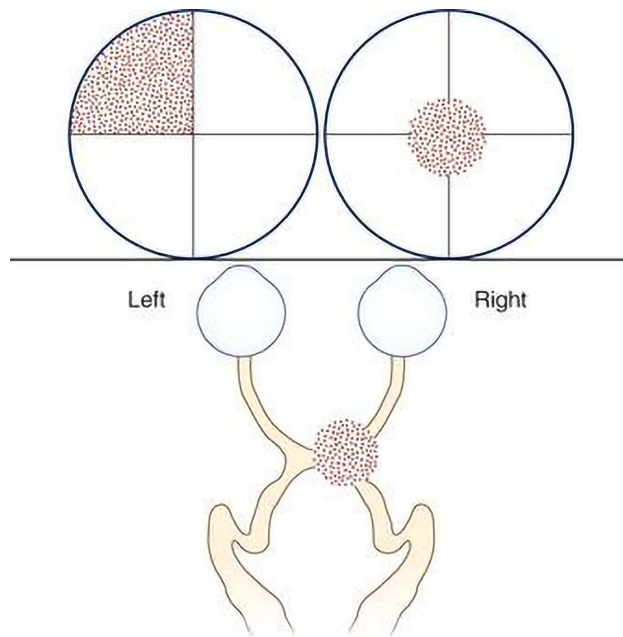
Myelinated Optic Nerve Fibers



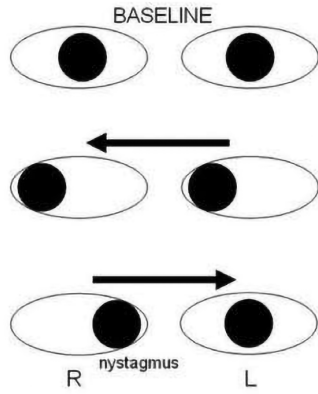
Morning Glory Syndrome



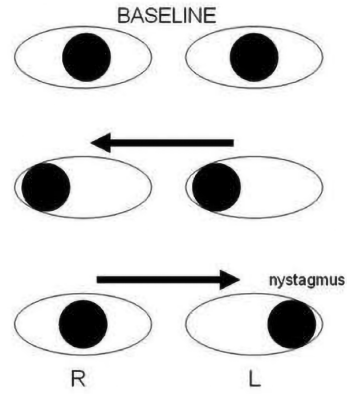
Ishihara's color plates



A. Reverse INO



B. Typical INO

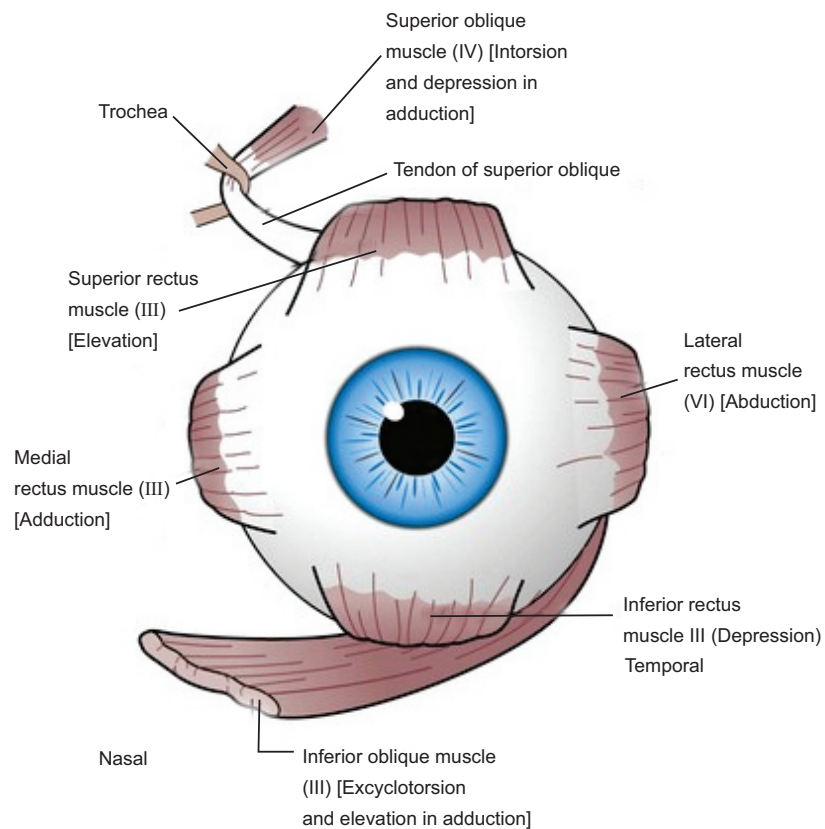




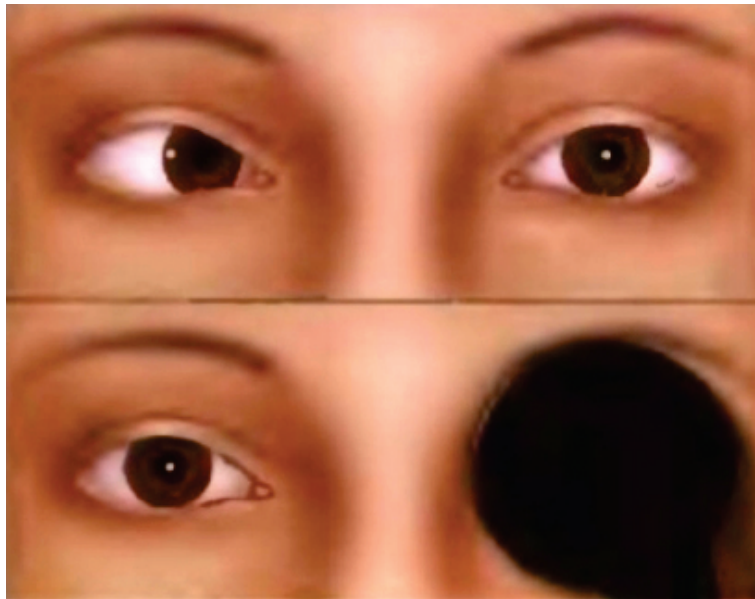
NOTES

SQUINT

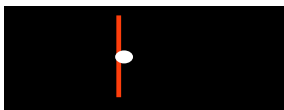
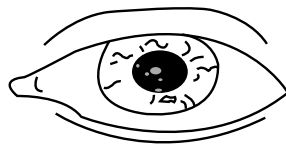
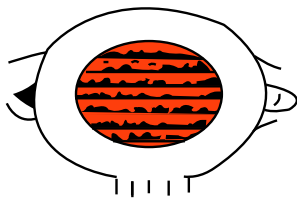
ACTIONS OF EOM			
Action	Primary	Secondary	Tertiary
MR	Adduction	-	-
LR	Abduction	-	-
SR	Elevation	Intorsion	Adduction
IR	Depression	Extorsion	Adduction
SO	Intorsion	Depression	Abduction
IO	Extorsion	Elevation	Abduction



CRANIAL NERVES
 III Oculomotor nerve
 IV Trochlear nerve
 VI Abducens nerve



Maddox Double Rod Test



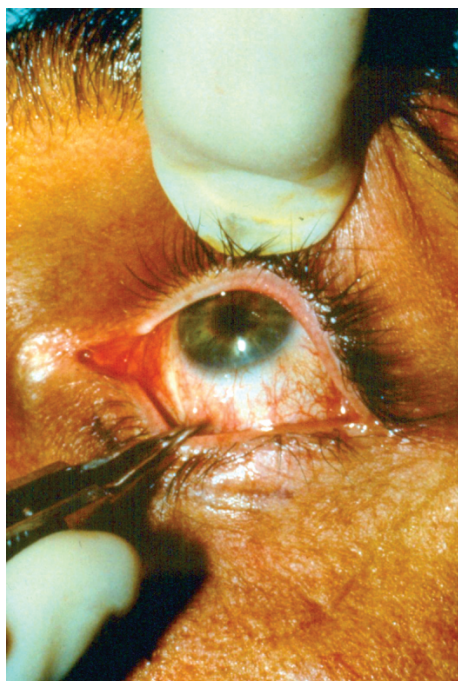
NO HORIZONTAL PHORIA



**EXOPHORIA
(CORRECT WITH BASE IN PRISM)**

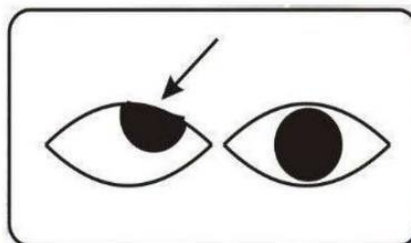


**ESOPHORIA
(CORRECT WITH BASEOUT PRISM)**

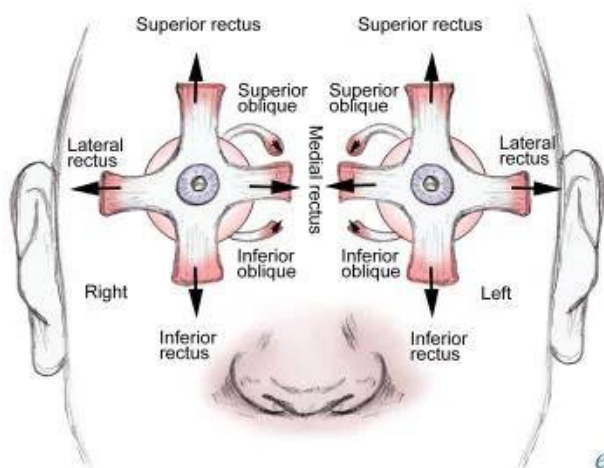










The movement is lost in:

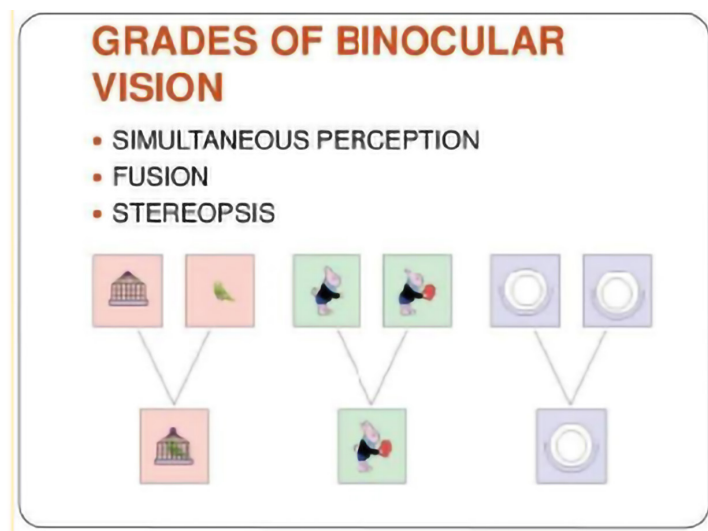


- a. Third nerve palsy
- b. Trochlear palsy
- c. Sixth nerve palsy
- d. Facial palsy





Muscle tested		Movement
SR		Looks medially and upward
IR		Looks medially and downward
LR		Looks laterally
MR		Looks medially
IO		Looks laterally and upward
SO		Looks laterally and downward





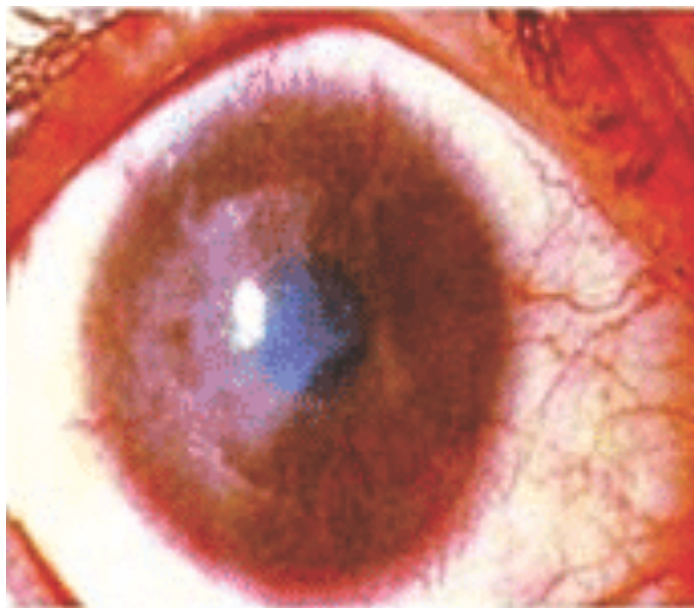
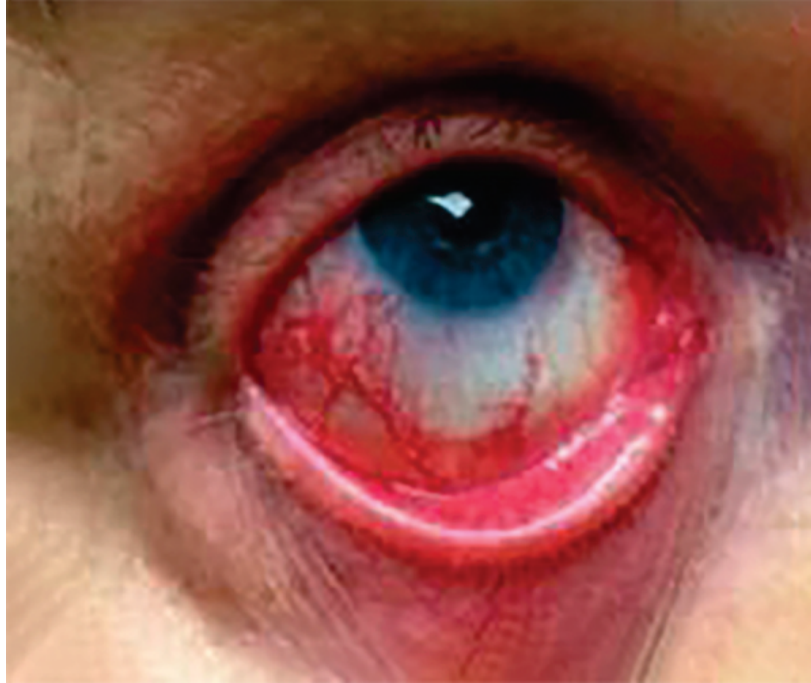
NOTES



NOTES

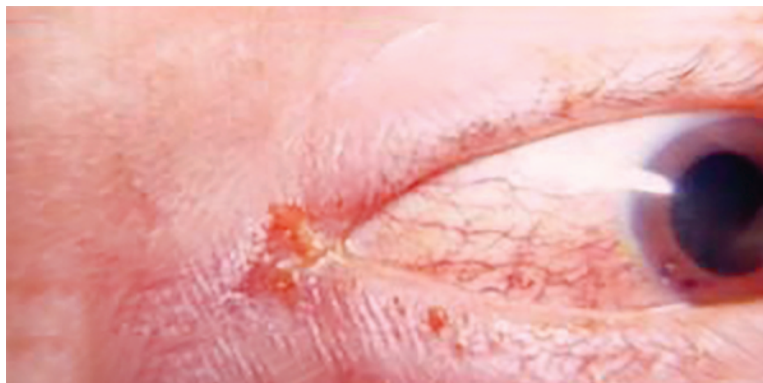
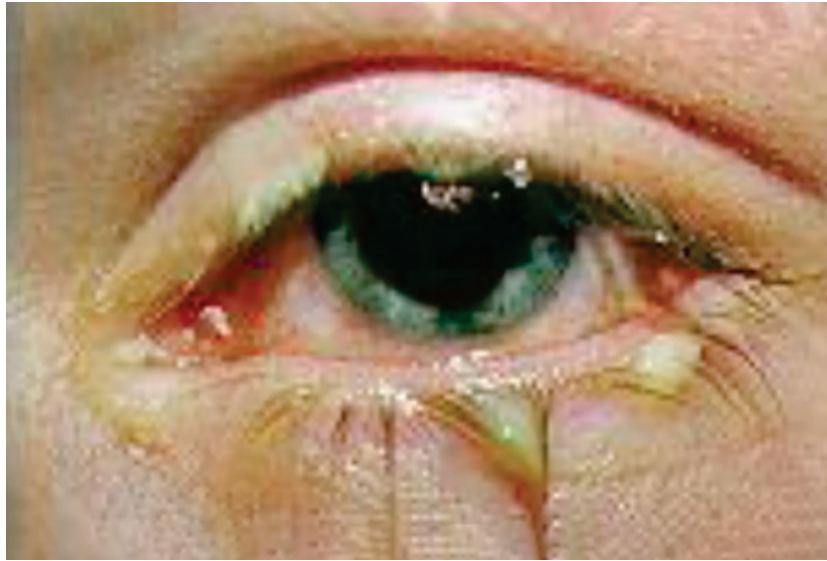


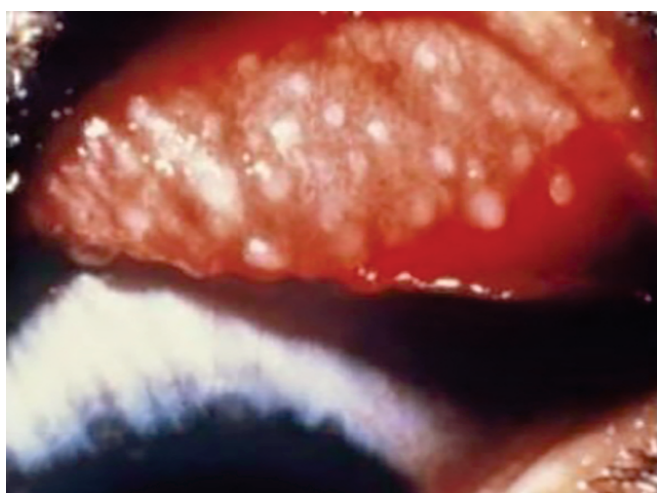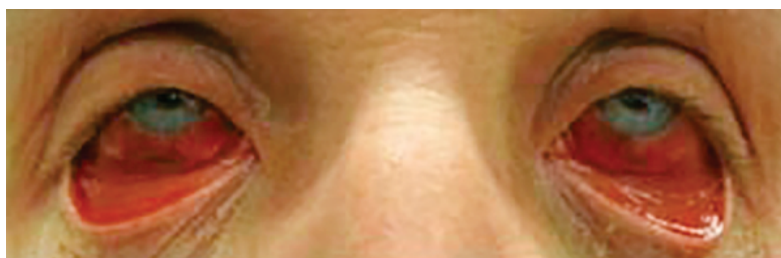CONJUNCTIVA



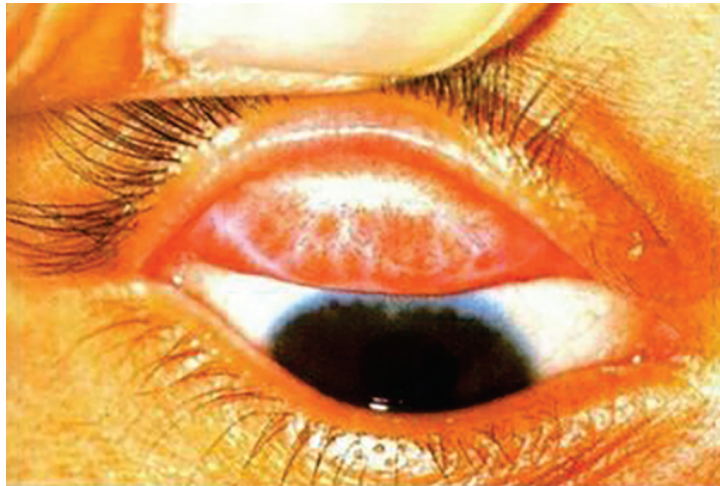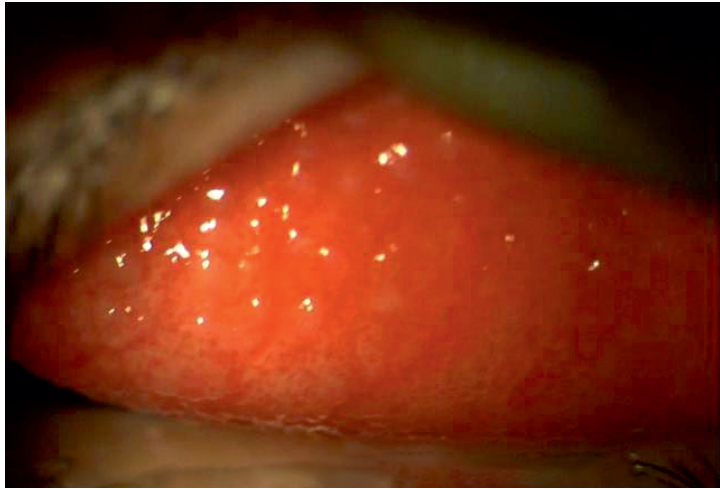


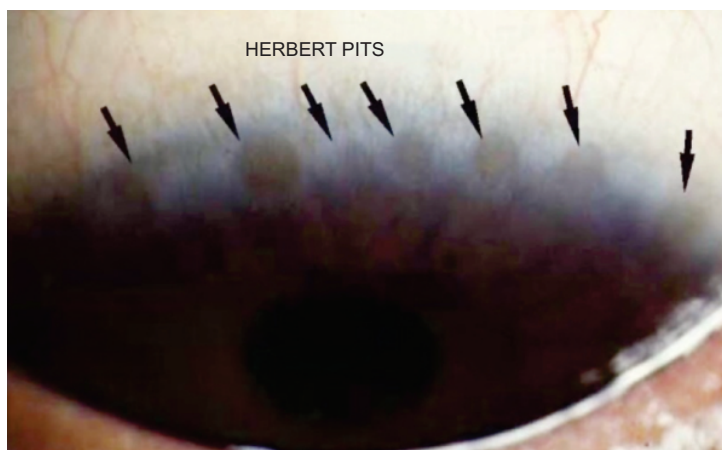
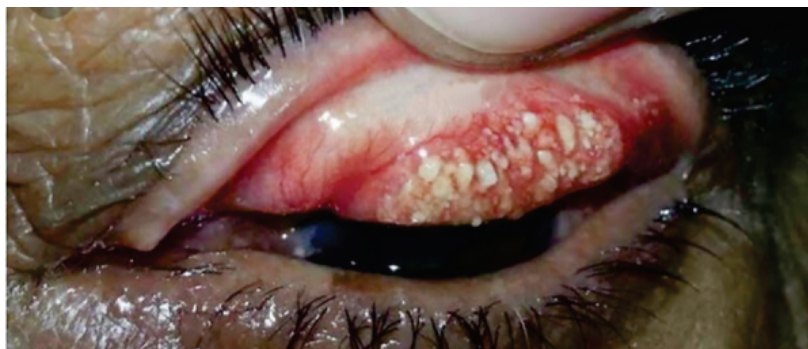Acute mucopurulent conjunctivitis

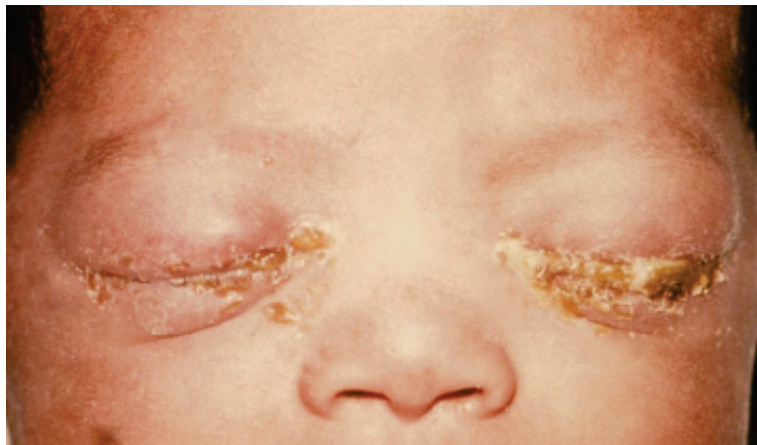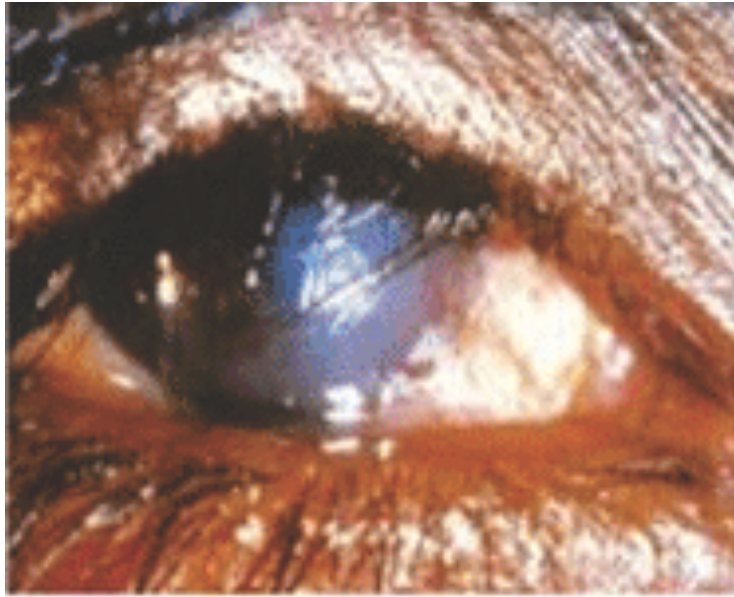


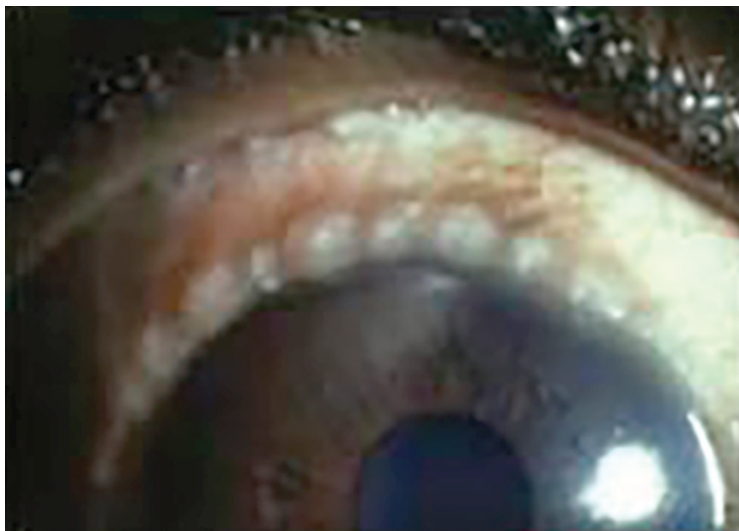
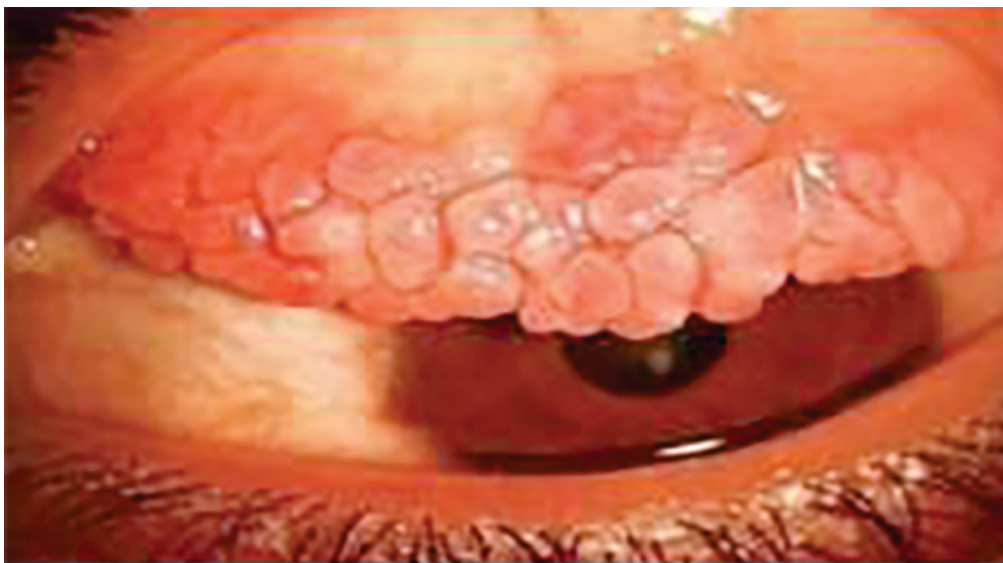


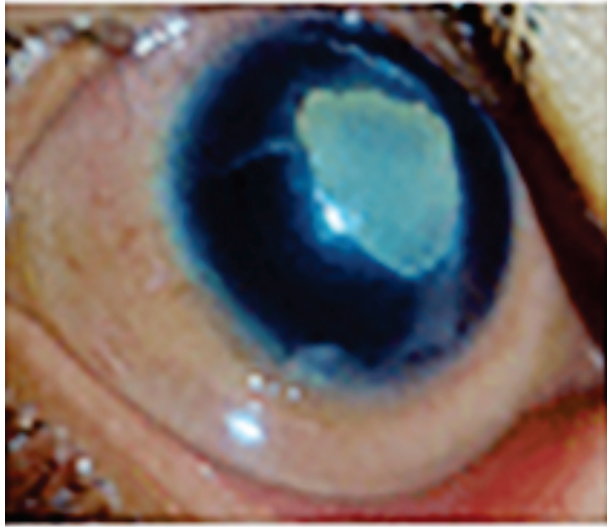
Sago grain follicles



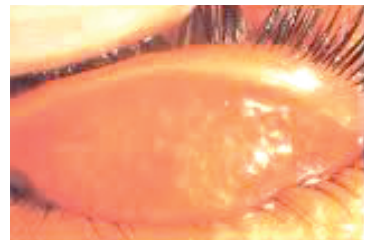









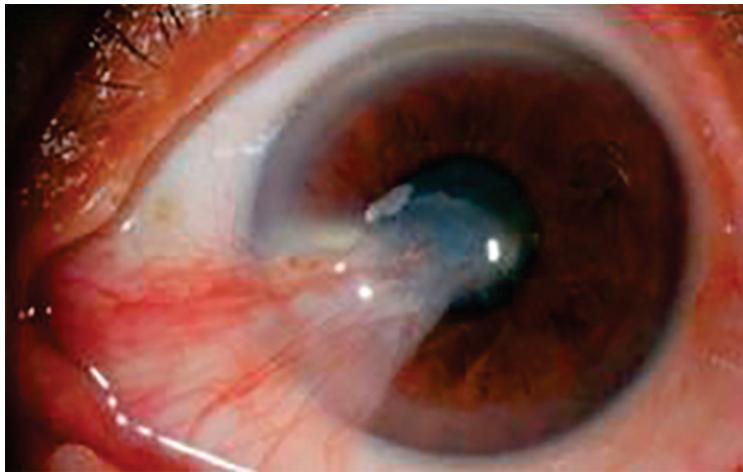


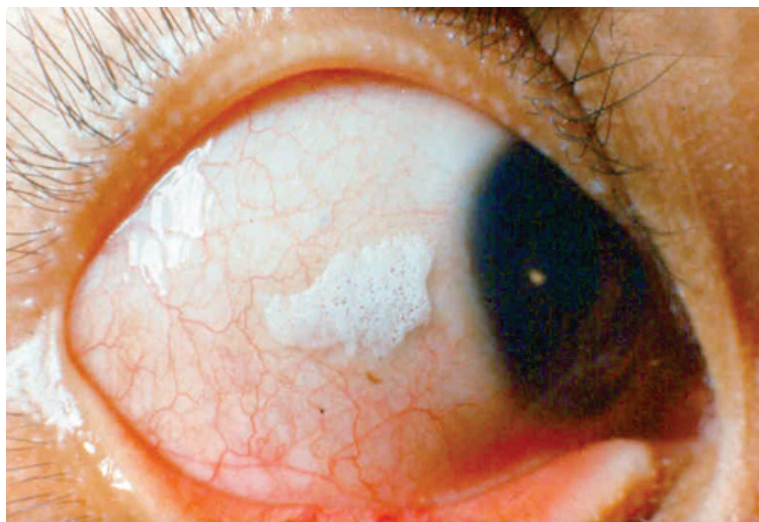
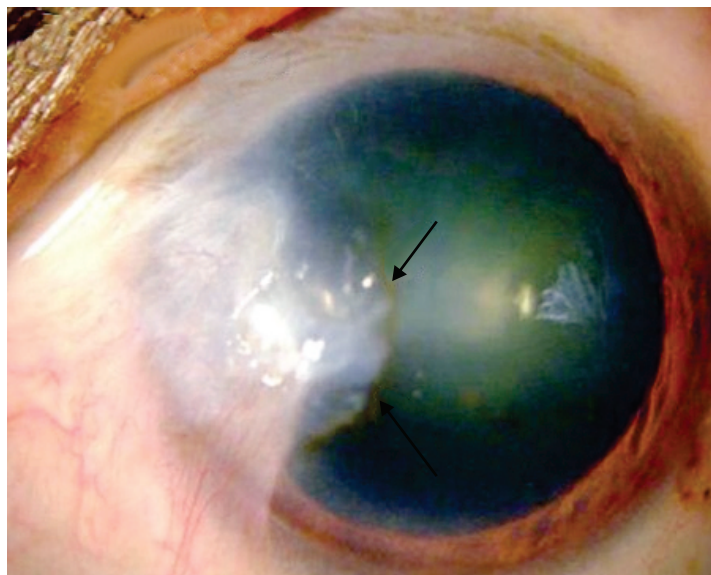


	Stage	Description
	N: Normal Tarsal Conjunctiva	For examination, the upper eyelid is turned over (everted). Notice the large deep-lying blood vessels that mainly run vertically.
	TF: Trachomatous inflammation-Follicular	Presence of 5 or more follicles in the upper tarsal conjunctiva, each at least 0.5 mm in size.
	TI: Trachomatous inflammation-Intense	Pronounced inflammatory thickening of the upper tarsal conjunctiva, which obscures more than one half of the normal tarsal vessels.
	TS: Trachomatous Scarring	The presence of easily visible white lines, bands, or sheets in the tarsal conjunctiva. Scarring may obscure the tarsal vessels.
	TT: Trachomatous Trichiasis	At least 1 eyelash that rubs the globe or evidence of recently removed in-turned lash (epilation).
	CO: Corneal Opacity	The presence of an easily visible corneal opacity that obscures at least part of the pupillary margin

Intervention: SAFE strategy

- *Surgery for trichiasis*
- *Antibiotics*
- *Facial cleanliness*
- *Environmental*
- *Hygiene*



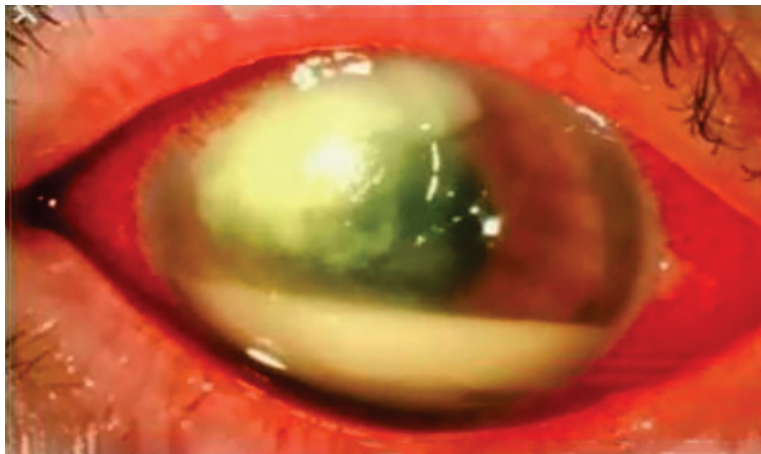


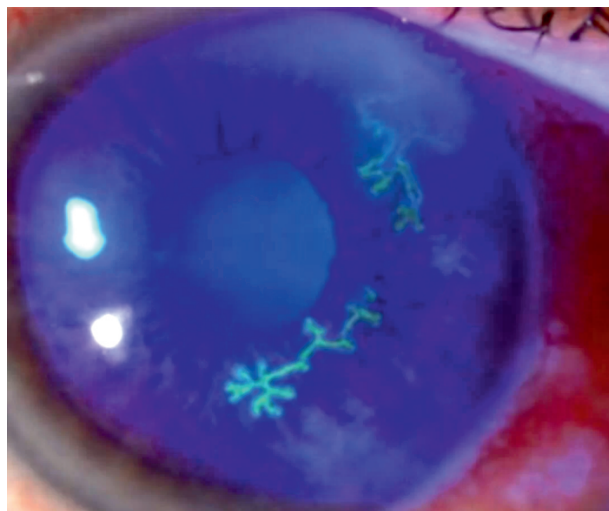
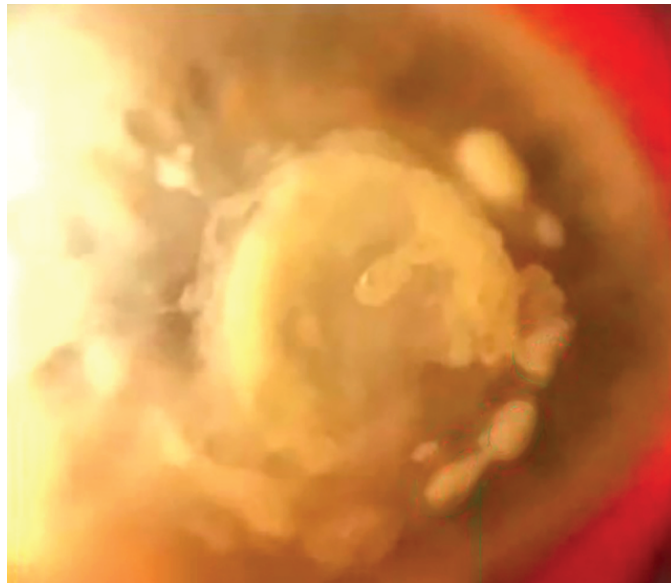


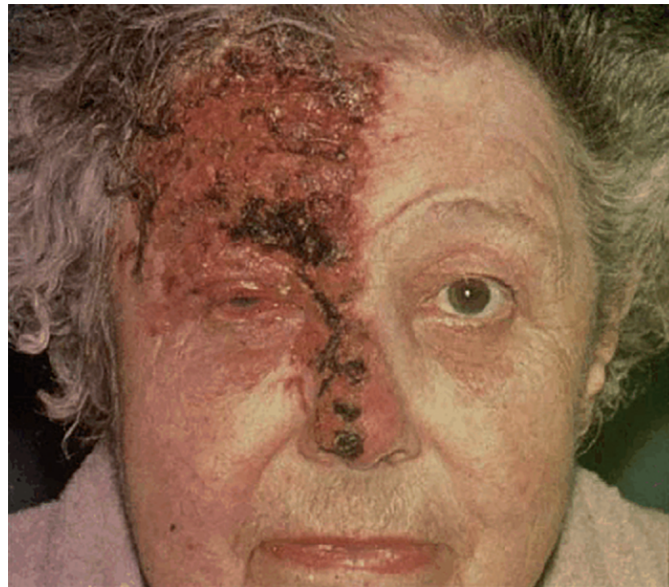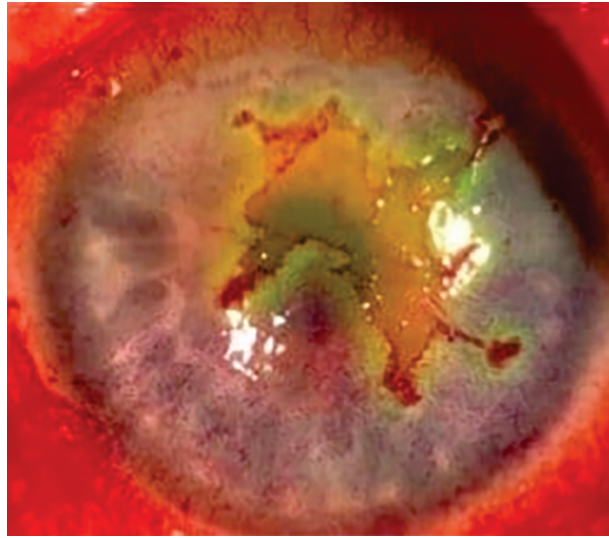
NOTES

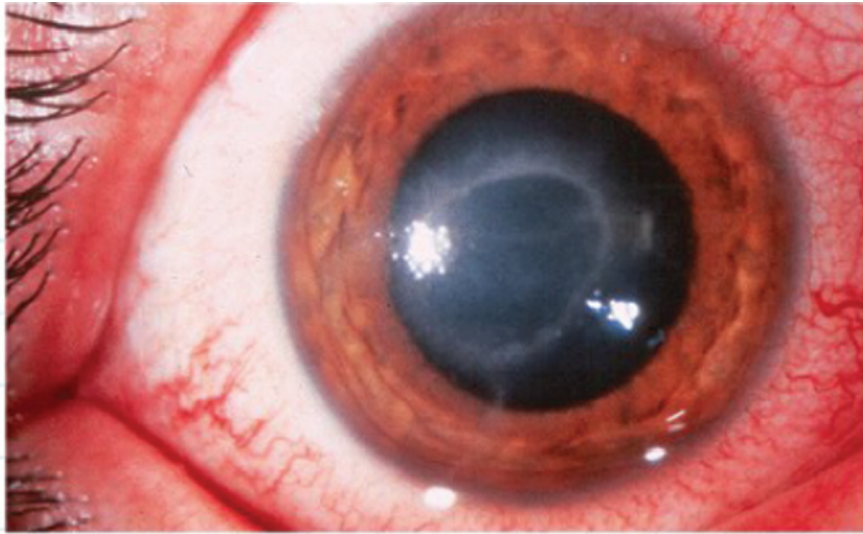
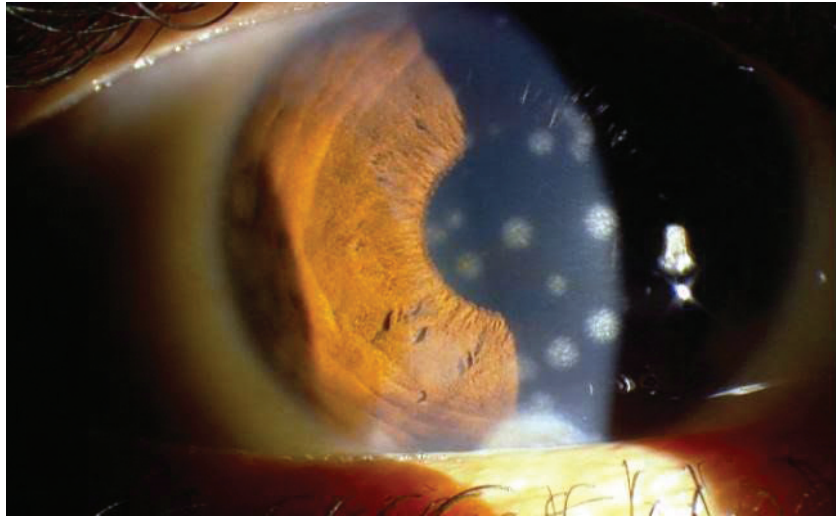


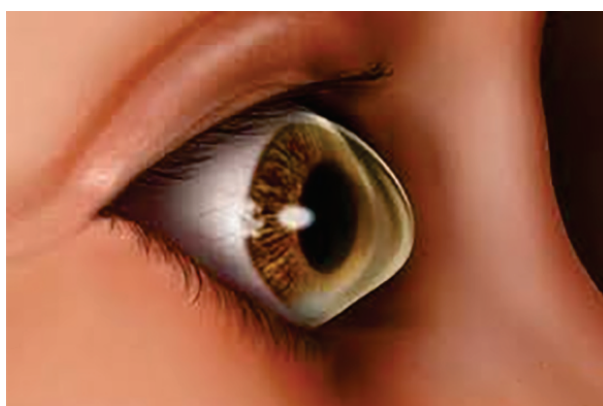
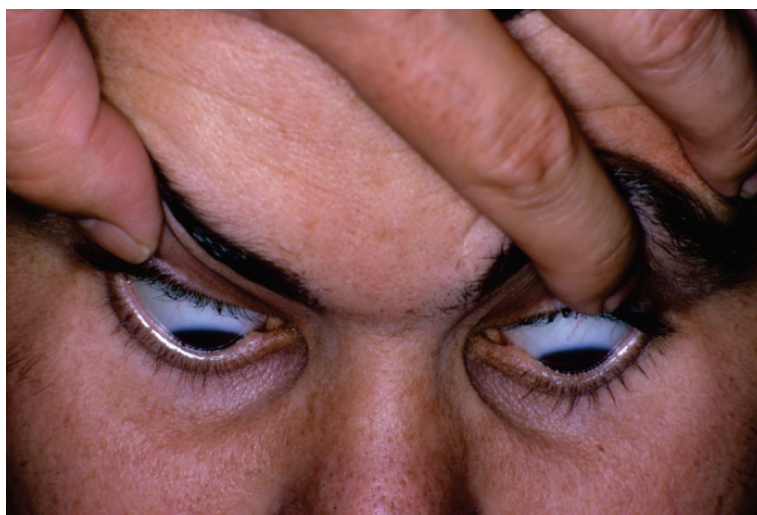CORNEA











SYSTEMIC ASSOCIATIONS OF KERATOCONUS

ABCDEF

Atopy

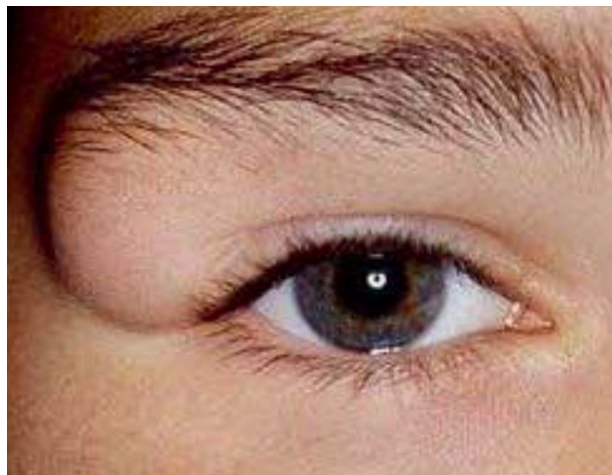
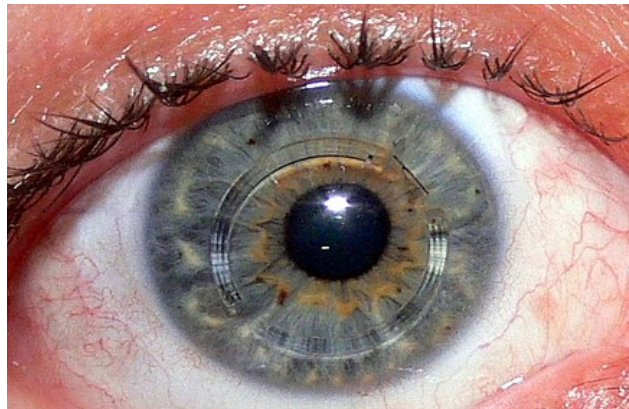
Bones (*osteogenesis imperfecta*)

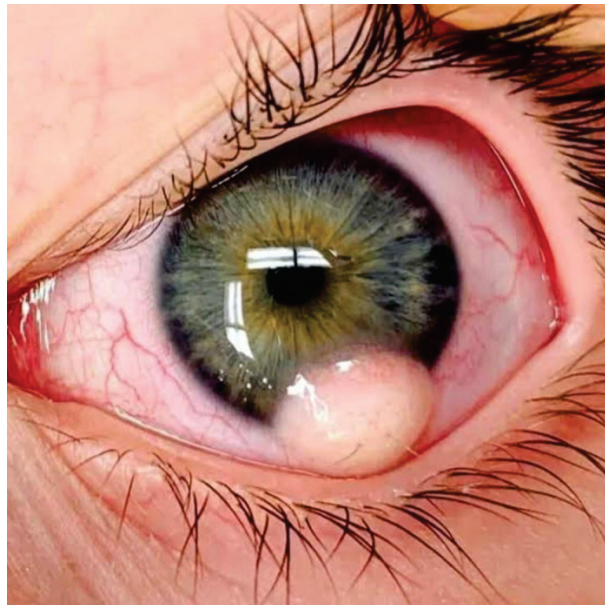
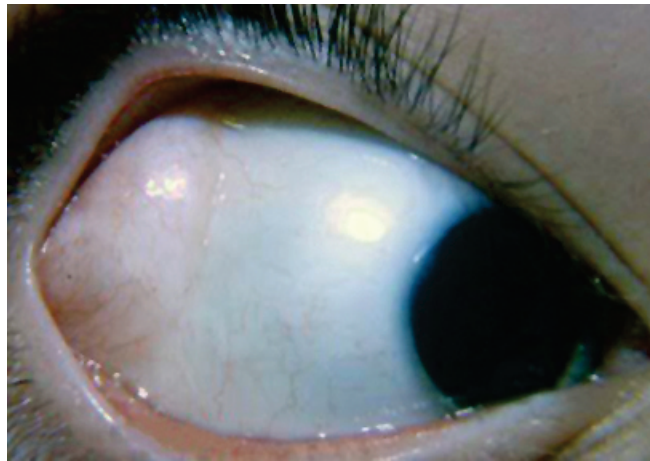
Crouzon's syndrome

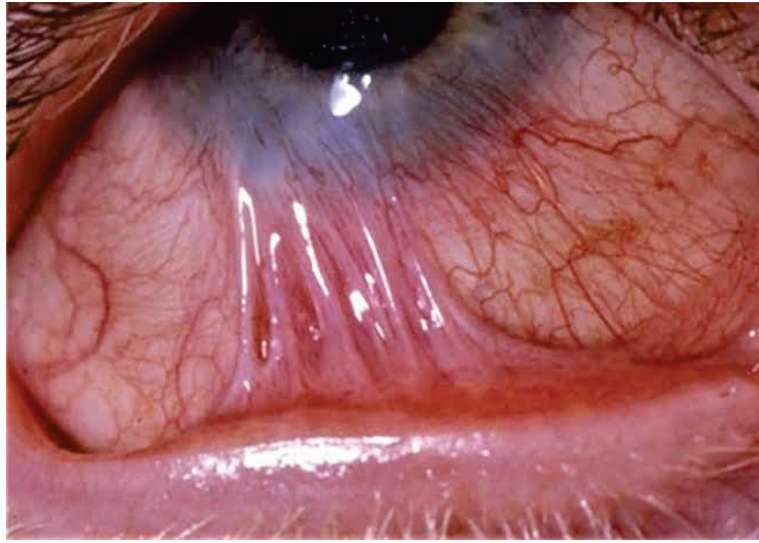
Down's syndrome

Ehler's Danlos syndrome

Fingers (*Marfan's*)











NOTES



NOTES



SCLERA

Episcleritis	Scleritis
	
<ul style="list-style-type: none"> • No pain comes to doctor due to red color 	<ul style="list-style-type: none"> • VERY Painful.. Deep Boring (drilling?) wakes up early due to pain.. Cant move eye DANGEROUS
<ul style="list-style-type: none"> • Affects episclera 	<ul style="list-style-type: none"> • Affects sclera
<ul style="list-style-type: none"> • Types-diffuse, nodular 	<ul style="list-style-type: none"> • Types-anterior, posterior
<ul style="list-style-type: none"> • Bright red in color 	<ul style="list-style-type: none"> • Anterior - diffuse, nodular, necrotizing (with inflammation Can burst, without inflammation - can perforate, scleromalacia, perforans)
<ul style="list-style-type: none"> • No scleral edema 	<ul style="list-style-type: none"> • Posterior-cant see the color, tenderness, proptosis, visual loss, Ultra sound B Scan -T sign. Treat with Systemic Steroids.
<ul style="list-style-type: none"> • No treatment needed, resolves spontaneously, Idiopathic, other causes could gout, hypersensitivity etc, topical NSAIDS 	<ul style="list-style-type: none"> • Violet blue in color
<ul style="list-style-type: none"> • By 10% phenylephrine drops vessels undergo blanching white 	<ul style="list-style-type: none"> • Scleral edema
	<ul style="list-style-type: none"> • Associated with AUTOIMMUNE disorders RA, SLE etc
	<ul style="list-style-type: none"> • Treatment Oral NSAIDS, 2 step- Systemic Steroids, 3 step-immunomodulators - cyclophosphomide
	<ul style="list-style-type: none"> • By 10% phenylephrine drops vessies do not blanch (deep blood vessels)

TYPES OF SCLERITIS



Blue Sclera

High myopia

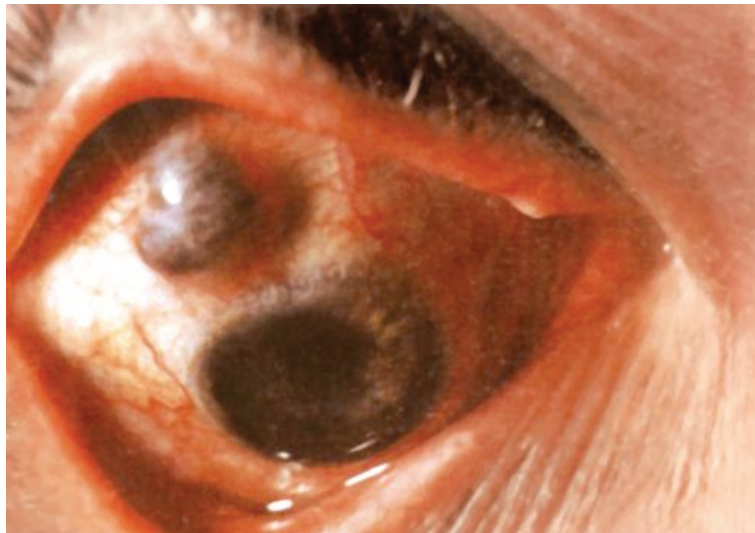
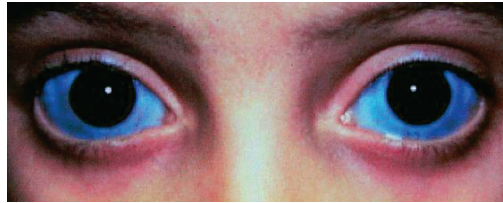Osteogenesis imperfecta

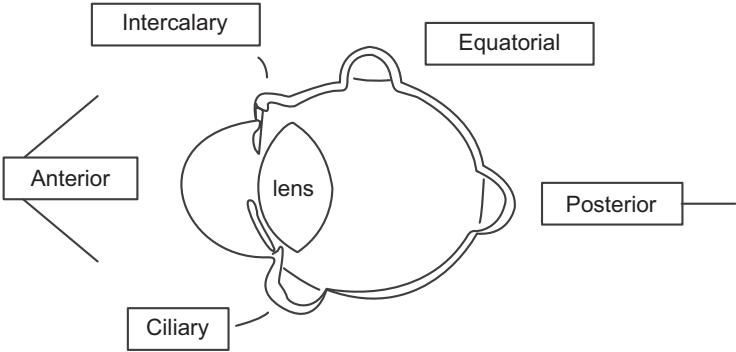
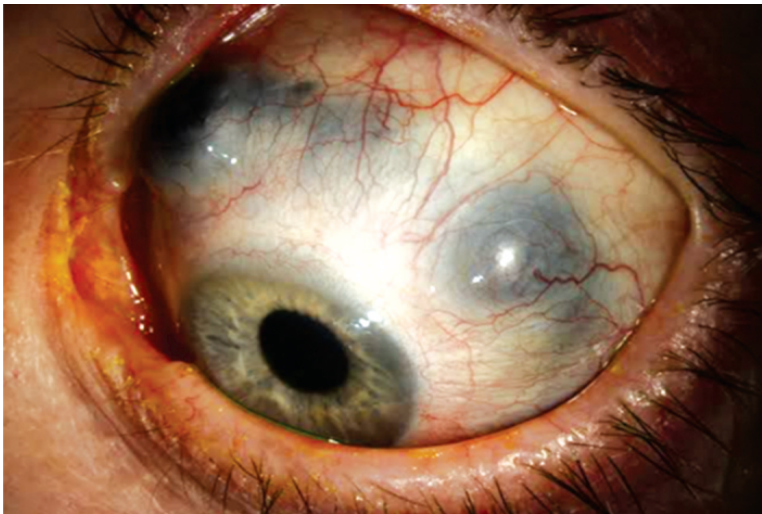
Pseudoxanthoma elasticum

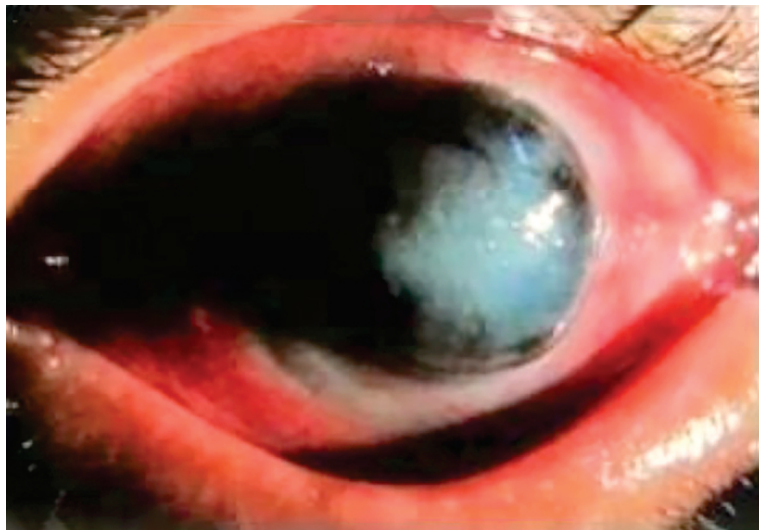
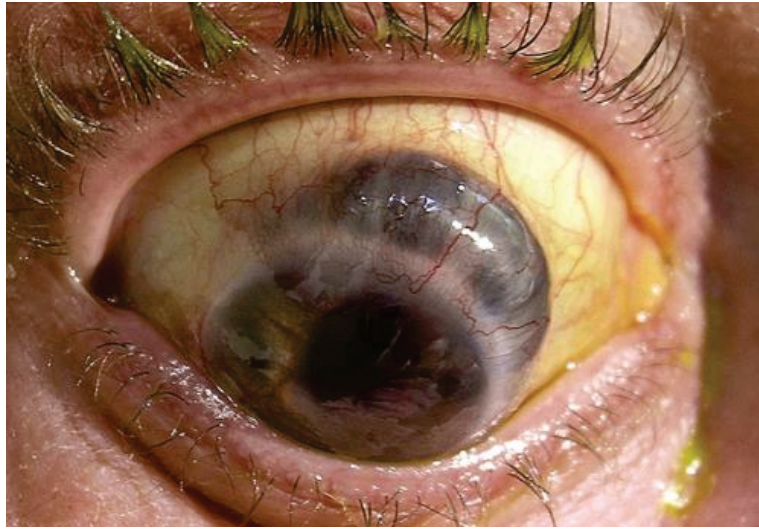Ehlers-danlos syndrome

Scleritis

Bupthalmos









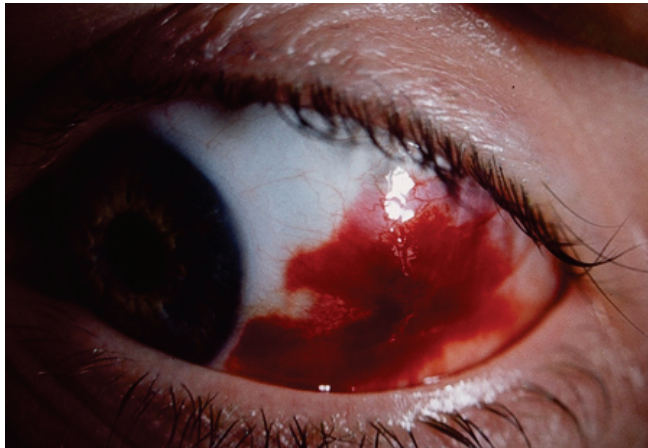NOTES

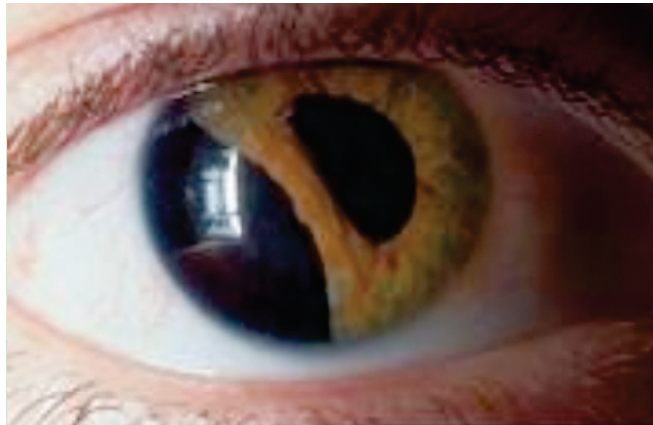
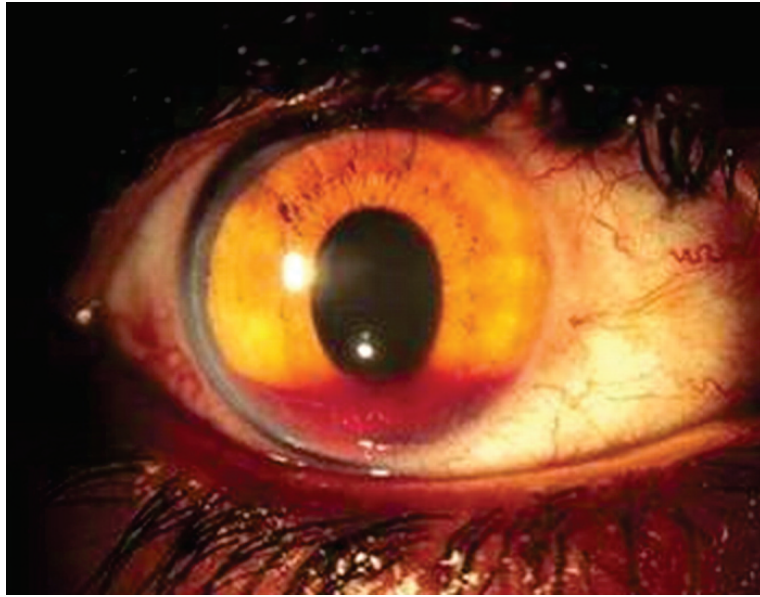


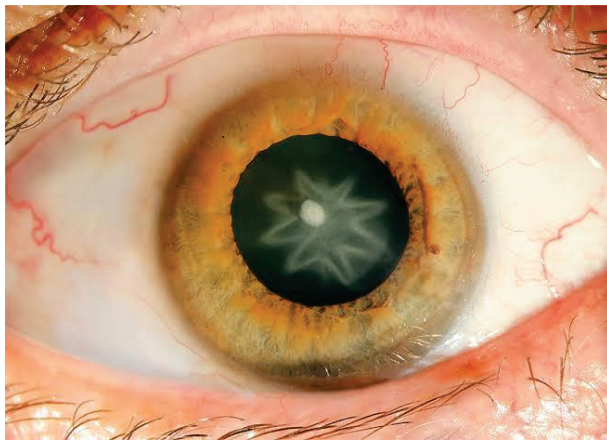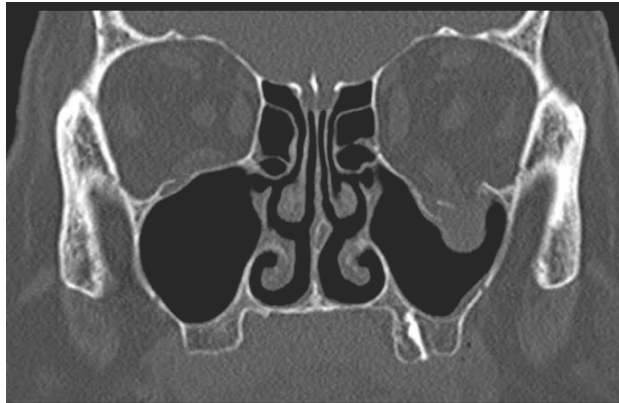NOTES

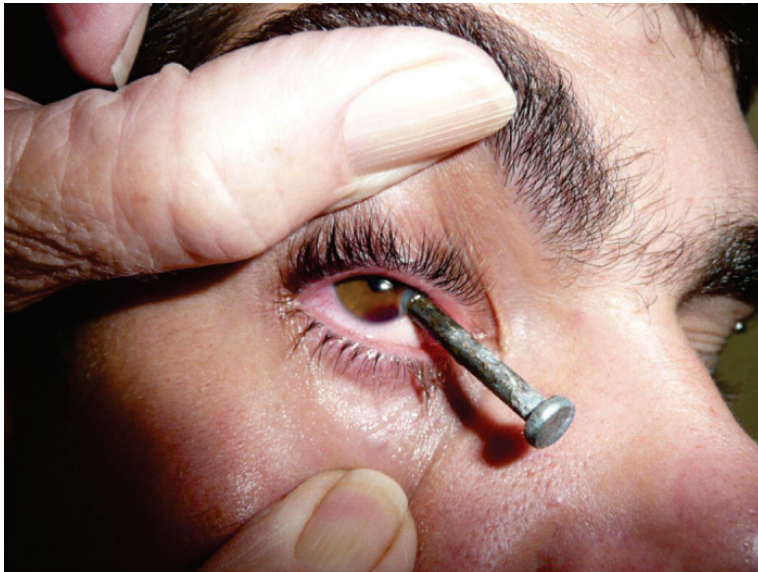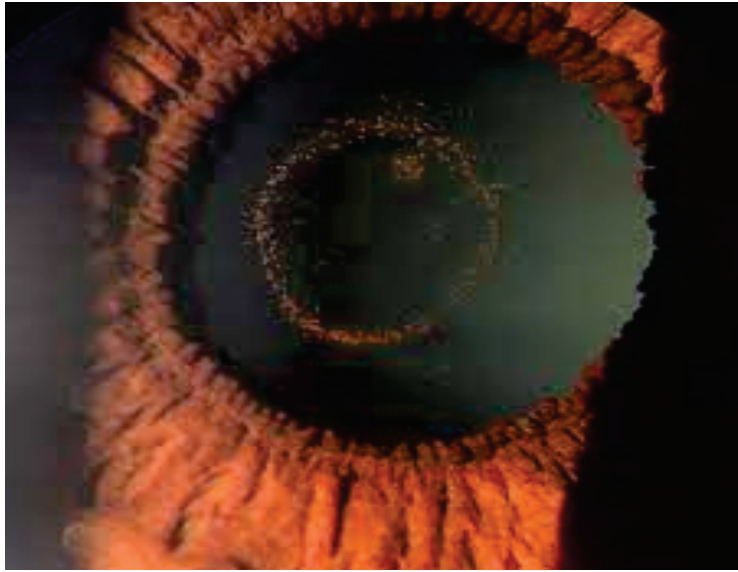


TRAUMA











Salient Features of Common Cycloplegic and Mydriatic Drugs

Sl. No	Name of the drug	Age of the patient when indicated	Dosage of Instillation	Peak effect	Time of Performing Retinoscopy	Duration of action	Period of Postcycloplegic test	Tonus Allowance
1.	Atropine sulphate (1% ointment)	< 5 years	TDS x 3 days	2-3 days	4th day	10-20 days	After 3 weeks of retinoscopy	1D
2.	Homatropie hydrobromied (2% drops)	5-8 years	One drop every 10 min for 6 times	60-90 min	After 90 min. of instillation of first drop	48-72 hours	After 3 days of retinoscopy	0.5D
3.	Cyclopentolate hydrochloride (1% drops)	8-20 years	One drop every 15 min. for 3 times	80-90 min	After 90 min. of instillation of first drop	6-18 hours	After 3 days of retinoscopy	0.75D
4.	Tropicamide (0.5%, 1% drops)	Not used as cycloplegic for retinoscopy; used only as mydriatic	One drop every 15 min. for 3 to 4 times	20-40 min.		4-6 hours		
5.	Phenylephrine (5%, 10% drops)	Used only as mydriatic alone or in combination with tropicamide	One drop every 15 min. for 3 to 4 times	30-40 min.		4-6 hours		

Ocular and Systemic Features of Immunological Disorders:

Systemic Diagnosis	Systemic Features	Extraocular Features	Intraocular Features
Rheumatoid arthritis	Arthritis: hand, wrist and foot, skin nodules, Felty syndrome	'Dry eye', episcleritis, scleritis	Iridocyclitis, corneal melting, cataract
Systemic lupus erythematosus	Butterfly rash, pleuritis, pericarditis Raynaud phenomenon	Episcleritis	Iritis, retionopathy
Giant cell arteritis	Temporal arteritis, cephalgia, jaw claudication	Extraocular muscle palsies	Anterior ischaemic optic neuropathy
Sarcoidosis	Granuloma of the lymph nodes, lungs, CNS, erythema nodosum	Enlargement of the lacrimal glands	Iridocyclitis, retinal periphlebitis or sarcoid nodule
Reiter syndrome	Arthritis, urethritis, planter rash	Conjunctivitis	Uveitis, retinal vasculitis
Periarteritis nodosa	Pyrexia of unknown origin, myalgia, arthralgia, skin nodules, renal and cardiac failure	Episcleritis, extraocular muscle palsy	Uveitis, retinal haemorrhage, papilloedema
Vogt-Koyanagi-Harada syndrome	Meningitis, encephalopathy, dysacusis, vitiligo, alopecia	Poliosis	Uveitis, choroiditis, exudative retinal detachment
Multiple endocrine neoplasia (MEN IIb)	Medullary carcinoma of thyroid, phaeochromocytoma	Mucosal neuromas of the lid and conjunctiva	Medullated nerve fibres in the cornea

Ocular and Systemic Features of Haematological Diseases

Systemic Diagnosis	Systemic Features	Extraocular Features	Intraocular Features
Lymphocytic leukaemia	Lymphadenopathy, hepatosplenomegaly, anaemia, leucopenia	Proptosis	Iris nodules, retinal oedema, haemorrhages, leukaemic infiltrates, Roth spots
Myeloid leukaemia	Hepatosplenomegaly, bleeding, thrombosis	Orbital chloroma	Retinal oedema, haemorrhages, peripheral retinal neovascularization
Lymphomas	Fever, lymphadenopathy	Lid/orbital deposits	Uveitis
Sickle cell anaemia	Transient aplastic crisis, stroke, leg ulcers, jaundice, anaemia	Dilated conjunctival vessels	Retinal capillary occlusion, neovascularization, chorioretinal scars



Ocular and Systemic Features of Infectious Diseases

Systemic Diagnosis	Systemic Features	Extraocular Features	Intraocular Features
Viral			
<i>Herpes simplex</i>	<i>Blisters and sores around the mouth and genital area</i>	<i>Vesicles on the lids</i>	<i>Dendritic keratitis, uveitis, acute retinal necrosis</i>
<i>Congenital rubella</i>	<i>Congenital heart disease, sensorineural deafness, mental retardation</i>		<i>Microphthalmos, cataract, glaucoma, chorioretinitis</i>
<i>Measels</i>	<i>Rash, diarrhoea, middle ear infection, encephalitis, precipitates malnutrition</i>	<i>Keratoconjunctivitis, precipitates xerophthalmia</i>	<i>Optic neuritis</i>
<i>Infectious mononucleosis</i>	<i>Fever, malaise, rash, lymphadenopathy, splenomegaly</i>	<i>Conjunctivitis</i>	<i>Uveitis, retinal phlebitis, papillitis</i>
<i>Cytomegalovirus</i>	<i>Immunocompromised adults and newborns-fever, hepatitis, pneumonitis, encephalitis</i>	<i>Microphthalmos</i>	<i>Necrotizing chorioretinitis, optic atrophy</i>
<i>Acquired immune deficiency syndrome</i>	<i>Immunocompromised individuals, Kaposi sarcoma</i>	<i>Kaposi sarcoma (Fig)</i>	<i>Cotton-wool spots on retina, cytomegalovirus retinitis</i>
Fungal			
<i>Candida</i>	<i>Oral and genital 'thrush'</i>	<i>Conjunctivitis</i>	<i>Keratitis, retinitis, endophthalmitis</i>
<i>Cryptococcus</i>	<i>Immunocompromised adults, pneumonia, meningitis</i>		<i>Papilloedema, optic atrophy</i>
Bacterial			
<i>Tuberculosis</i>	<i>Fever, malaise, granulomas (lung, lymph node)</i>	<i>Phlyctenular conjunctivitis</i>	<i>Granulomatous uveitis, juxtapapillary choroiditis</i>
<i>Leprosy</i>	<i>Thickened peripheral nerves, hypaesthetic skin lesions, weakness of peripheral muscles</i>	<i>Facial palsy, madarosis</i>	<i>Iritis, secondary glaucoma, cataract</i>

Ocular and Systemic Features of Muscular Disorders

<i>Systemic Diagnosis</i>	<i>Systemic Features</i>	<i>Extraocular Features</i>	<i>Intraocular Features</i>
<i>Myasthenia gravis</i>	<i>Fluctuating voluntary muscle weakness affecting speech, swallowing breathing</i>	<i>Ptosis, diplopia</i>	
<i>Muscular dystrophy</i>	<i>Progressive muscle weakness of</i>	<i>Ptosis, exophthalmoplegia dry eye</i>	<i>Cataract, pigmentary retinopathy</i>

Ocular and Systemic Features of Inherited Disorders

<i>Systemic Diagnosis</i>	<i>Systemic Features</i>	<i>Extraocular Features</i>	<i>Intraocular Features</i>
<i>Down syndrome</i>	<i>Mental retardation, muscle hypotonia, congenital heart disease</i>	<i>Mongoloid slant of eyes, epicanthic folds, keratoconus</i>	<i>Cataract, iris spots</i>
<i>Sturge-Weber syndrome</i>	<i>Facial port-wine stain, angiomas</i>	<i>Arteriovenous malformations of episclera</i>	<i>Choroidal haemangioma, glaucoma</i>
<i>Neurofibromatosis</i>	<i>Café au lait spots, subcutaneous neurofibromas</i>	<i>Prosis, pulsating exophthalmos</i>	<i>Optic nerve gloma, neurofibromas of the iris, retina and choroid</i>
<i>Albinism</i>	<i>Hypopigmented skin and hair</i>	<i>Nystagmus</i>	<i>Translucent iris, albinotic fundus, foveal hypoplasia</i>
<i>Marfan syndrome</i>	<i>Tall, arachnodactyly, aortic aneurysm, cardiac valvular anomalies</i>		<i>Subluxation of the lens, myopia, retinal detachment</i>
<i>von Hippel-Lindau disease</i>	<i>Angiomas of the central nervous system and kidneys</i>		<i>Retinal angiomas</i>



Ocular and Systemic Features of Parasitic Diseases

Systemic Diagnosis	Systemic Features	Extraocular Features	Intraocular Features
<i>Toxoplasmosis</i>	<i>Congenital mental retardation, deafness, Immune deficient patient, encephalitis</i>		<i>Macular scarring, retino-choroiditis, vitritis</i>
<i>Toxocariasis</i>	<i>Congenital mental retardation, deafness, Immune deficient patient, encephalitis</i>		<i>Vitritis, choroiditis, vitreoretinal granuloma</i>
<i>Cysticercosis</i>	<i>Cysticerci-subcutaneous, brain, spine, heart</i>	<i>Subconjunctival cysticerci</i>	<i>Subretinal or vitreous cysticerci</i>
<i>Onchocerciasis</i>	<i>Subcutaneous onchoceromas</i>		<i>Sclerosing keratitis, uveitis, cataract</i>

Ocular and Systemic Features of Endocrine Disorders and Disorders of Metabolism

Systemic Diagnosis	Systemic Features	Extraocular Features	Intraocular Features
<i>Homocystinuria</i>	<i>Mental retardation, tall, arachnodactyly, thromboembolic episodes</i>		<i>Subluxation of the lens</i>
<i>Mucopolysaccharidoses</i>	<i>Dysmorphia, behavioural disorders, cardiac anomalies</i>	<i>Corneal opacification</i>	<i>Pigmentary retinopathy, glaucoma, optic atrophy</i>
<i>Wilson disease</i>	<i>Extrapyramidal signs, cirrhosis</i>	<i>Kayser-Fleischer ring</i>	<i>Sunflower cataract</i>
<i>Diabetes mellitus</i>	<i>Peripheral neuropathy, glomerulosclerosis</i>	<i>Xanthelasma, extraocular muscle palsies, infections</i>	<i>Cataract, iris neovascularization, retinopathy, vitreous haemorrhage, tractional retinal detachment, optic neuropathy</i>
<i>Hyperthyroidism</i>	<i>Tachycardia, tremors of the hand</i>	<i>Exophthalmos, lid retraction, lid lag</i>	<i>Superior limbic keratitis disc oedema</i>
<i>Hypoparathyroidism</i>	<i>Tetany, seizures</i>	<i>Fasciculation</i>	<i>Cataract, disc oedema</i>

Classification of Visual Impairment and Blindness

Category of Visual Impairment*	Best Corrected Visual Acuity (BCVA) in The Better Eye
0 'Normal'	6/6 to 6/18, i.e. can see 6/18 or better
1 'Visual impairment'	<6/18 to 6/18, i.e. cannot see 6/18 or better
2 'Severe visual impairment' (Economic)	<6/60 to 3/60, i.e. cannot see 6/60, can see 3/60
3 'Blind (Social)'	<3/60 to 1/60, i.e. cannot see 3/60, can see 1/60
4 'Blind (Legal)'	<1/60 to only light perception, i.e. cannot see 3/60, can see light
5 'Blind (Total)'	No light perception, i.e. cannot see light
9 'Undetermined or unspecified'	

*Adapted from International Statistical Classification of Diseases and Related Health Problems, tenth revision, Geneva, World Health Organization, 1992.



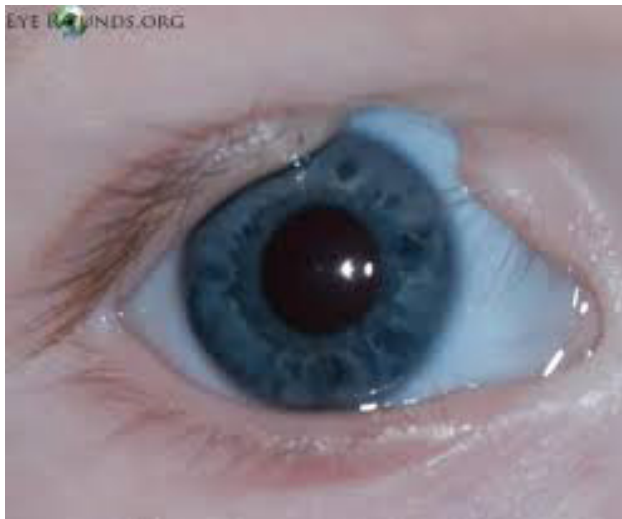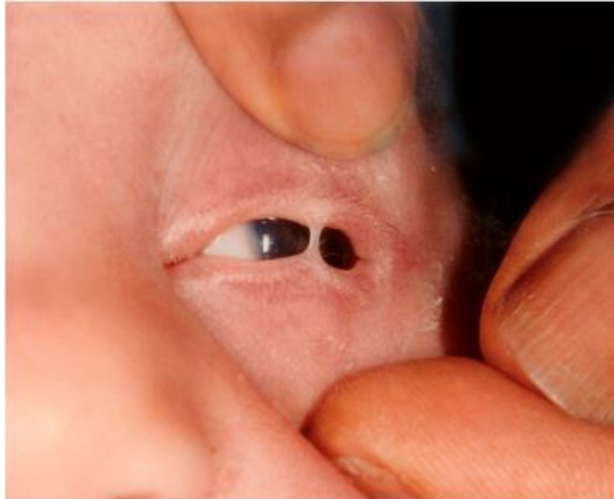
NOTES

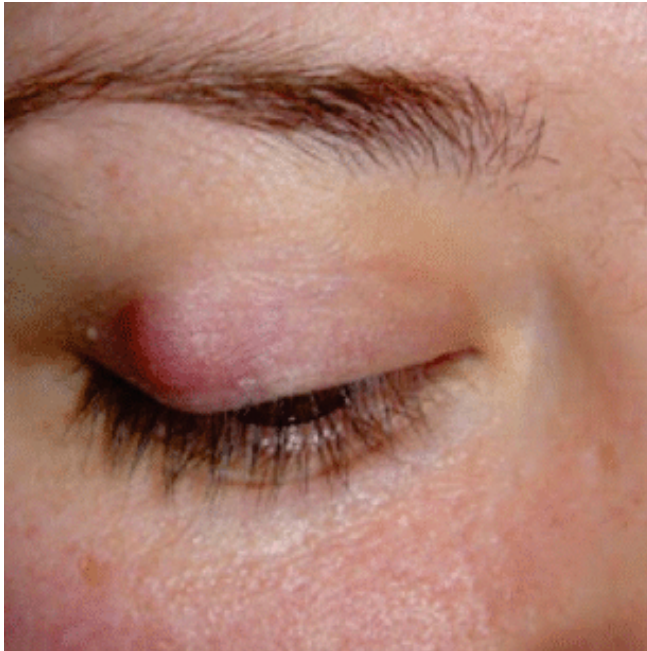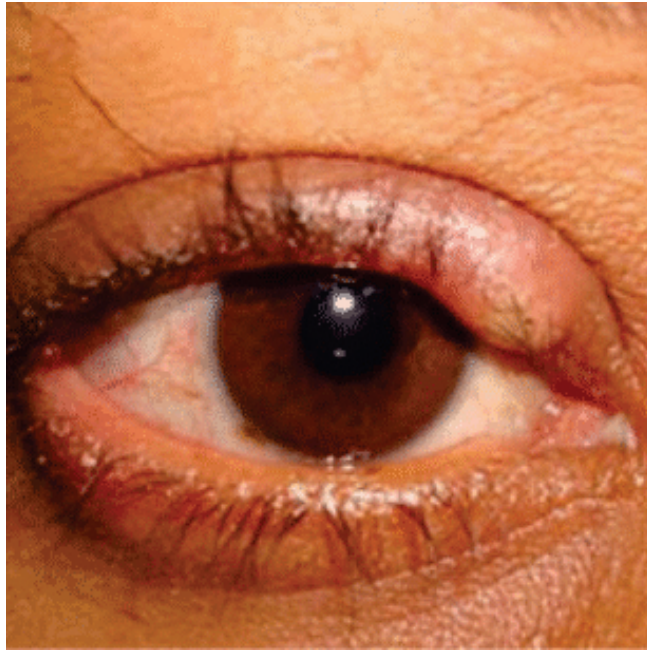


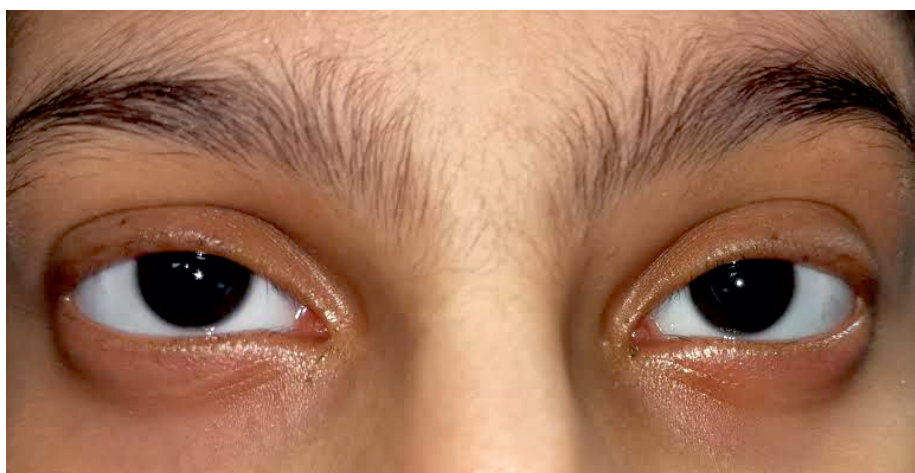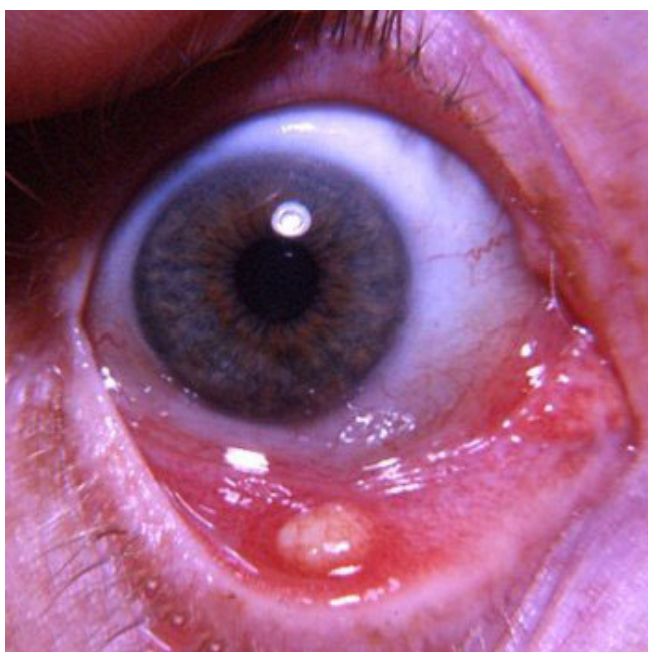NOTES

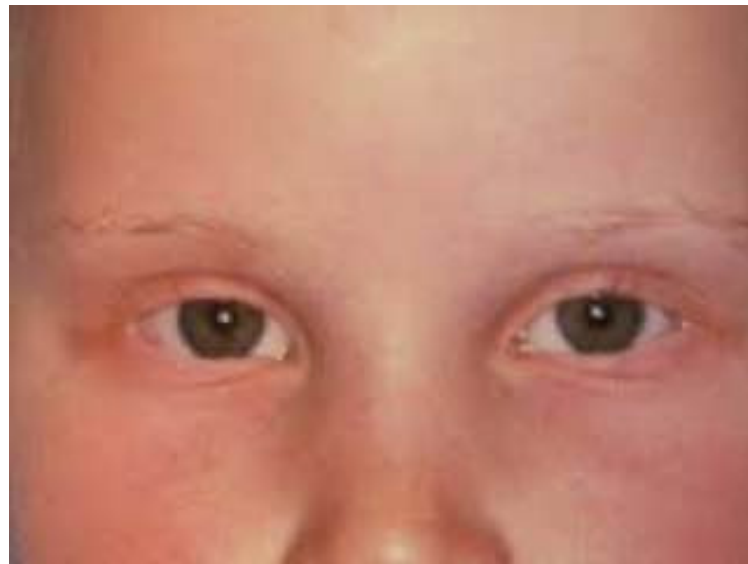
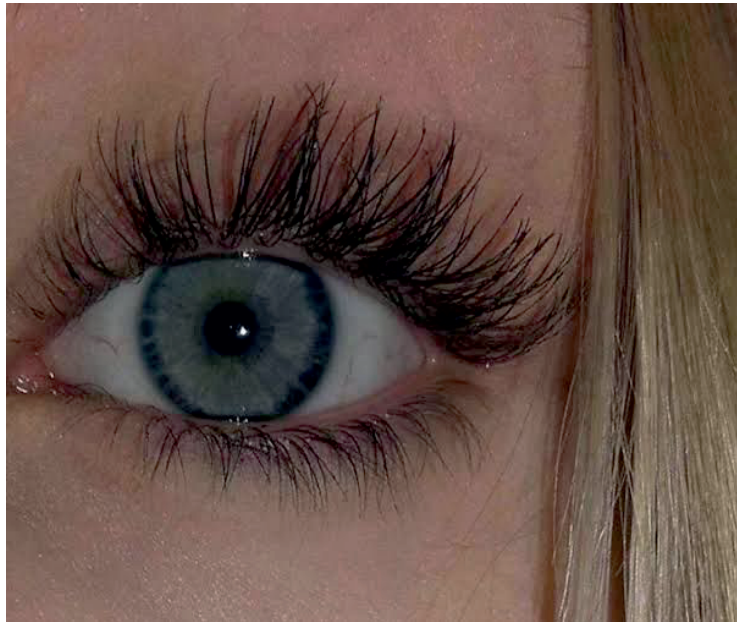
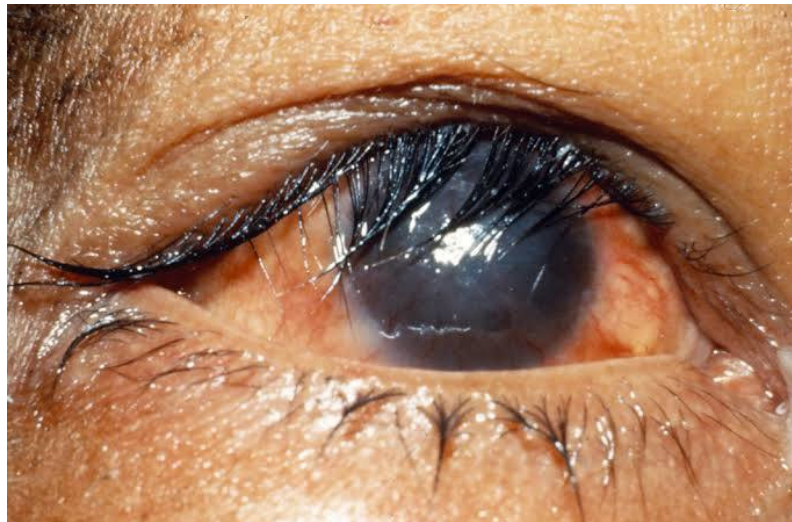
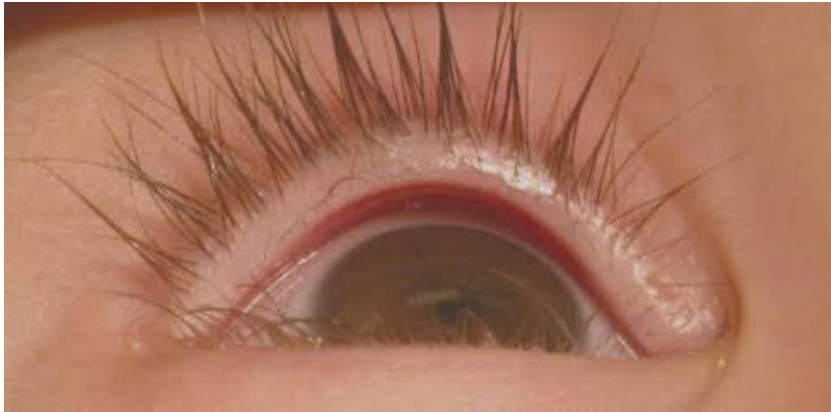EYELIDS





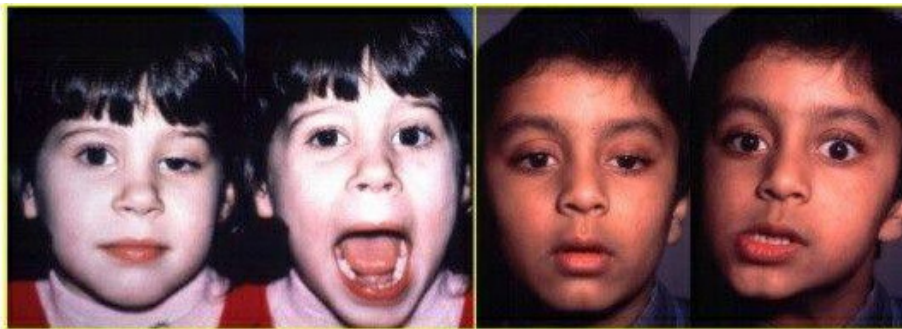





MARCUS GUNN JAW WINKING SYNDROME

- *Seen in 5% of congenital ptosis.*
- *Retraction or 'wink' of ptotic lid in conjunction with stimulation of ipsilateral pterygoid muscles in conjunction with stimulation of ipsilateral pterygoid muscles.*



Opening of mouth

Contralateral movement of jaw



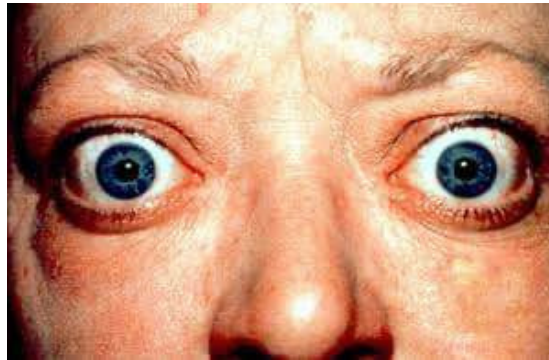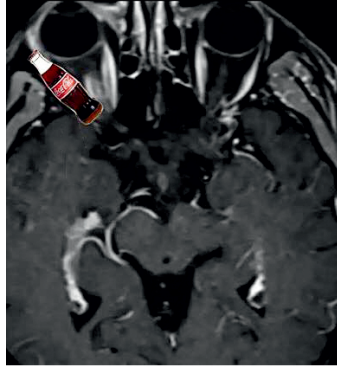
NOTES

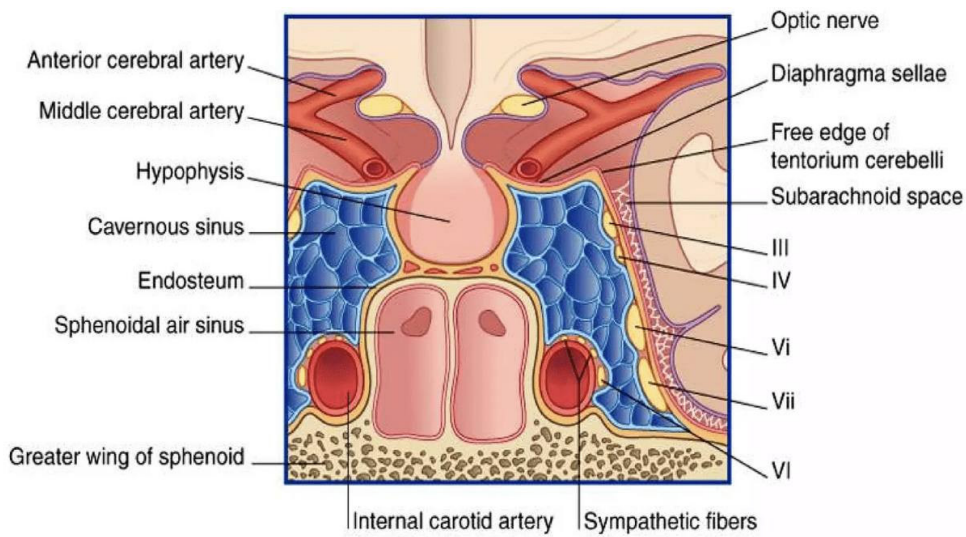


NOTES



ORBIT





Feature	Preseptal cellulitis	Orbital cellulitis
History	Insect bite or trauma around the eye	Upper respiratory tract infection toothache earache headache
Protruding eye (Proptosis)	Absent	Present
Eye movement	Normal	Painful, restricted
Visual acuity	Normal	Reduced in severe cases
Color vision	Normal	Reduced in severe cases
Pupil abnormality (relative afferent pupil defect, RAPD)	Normal	Present in severe cases

Clinical feature	Preseptal cellulitis	Orbital cellulitis
Eyelid swelling (w/w/o erythema)	Yes	Yes
Eye pain / tenderness	May be present	Yes, deep eye pain
Pain with eye movements	No	Yes
Proptosis	No	Usually may be subtle
Ophthalmoplegia (+/- diplopia)	No	Yes
Vision impairment	No	May be present (Afferent pupillary defect)
Chemosis	Rarely present	May be present
Leucocytosis	May be present	May be present



NOTES



NOTES



NOTES



NOTES



NOTES



NOTES