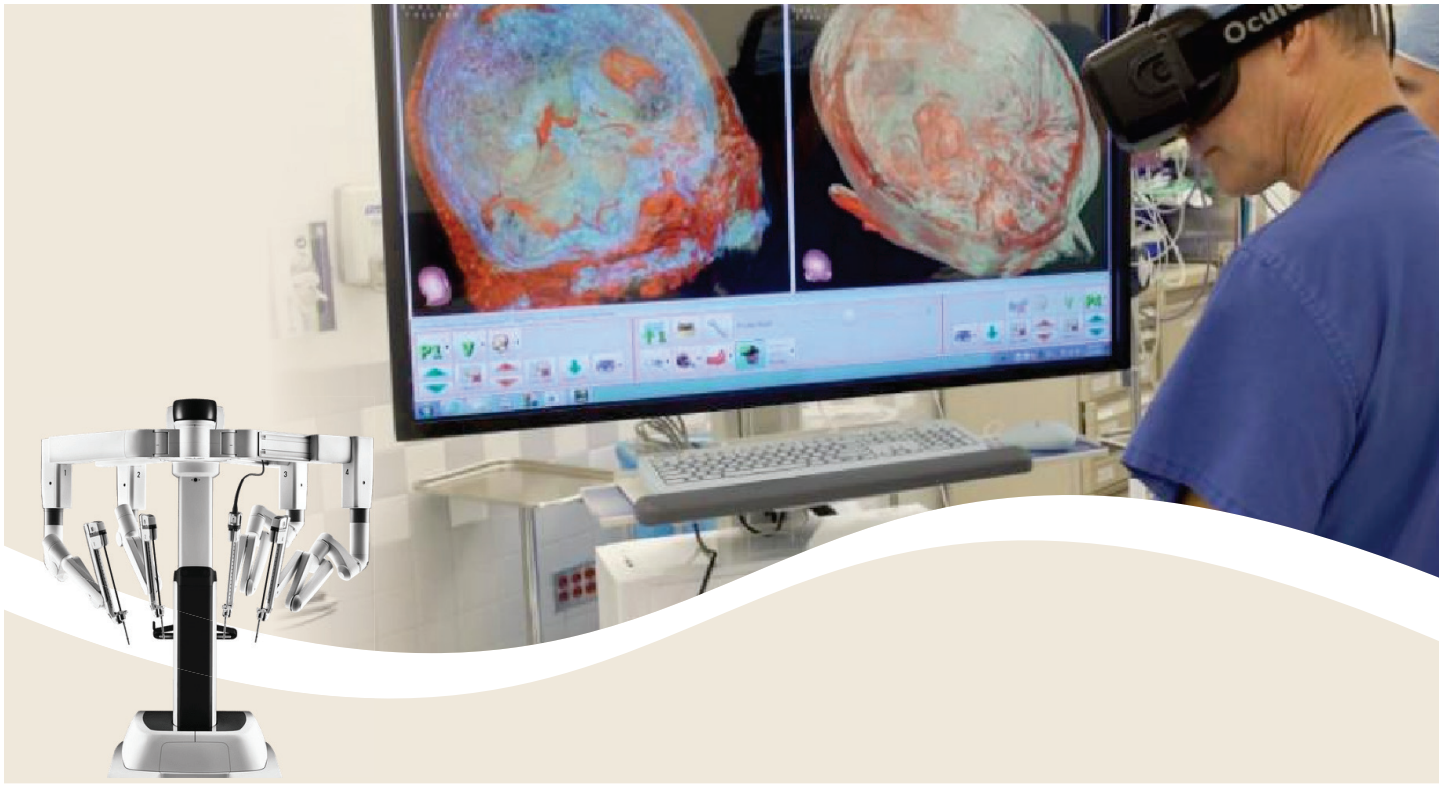




OneShot 4.0 **Surgery**



SURGERY

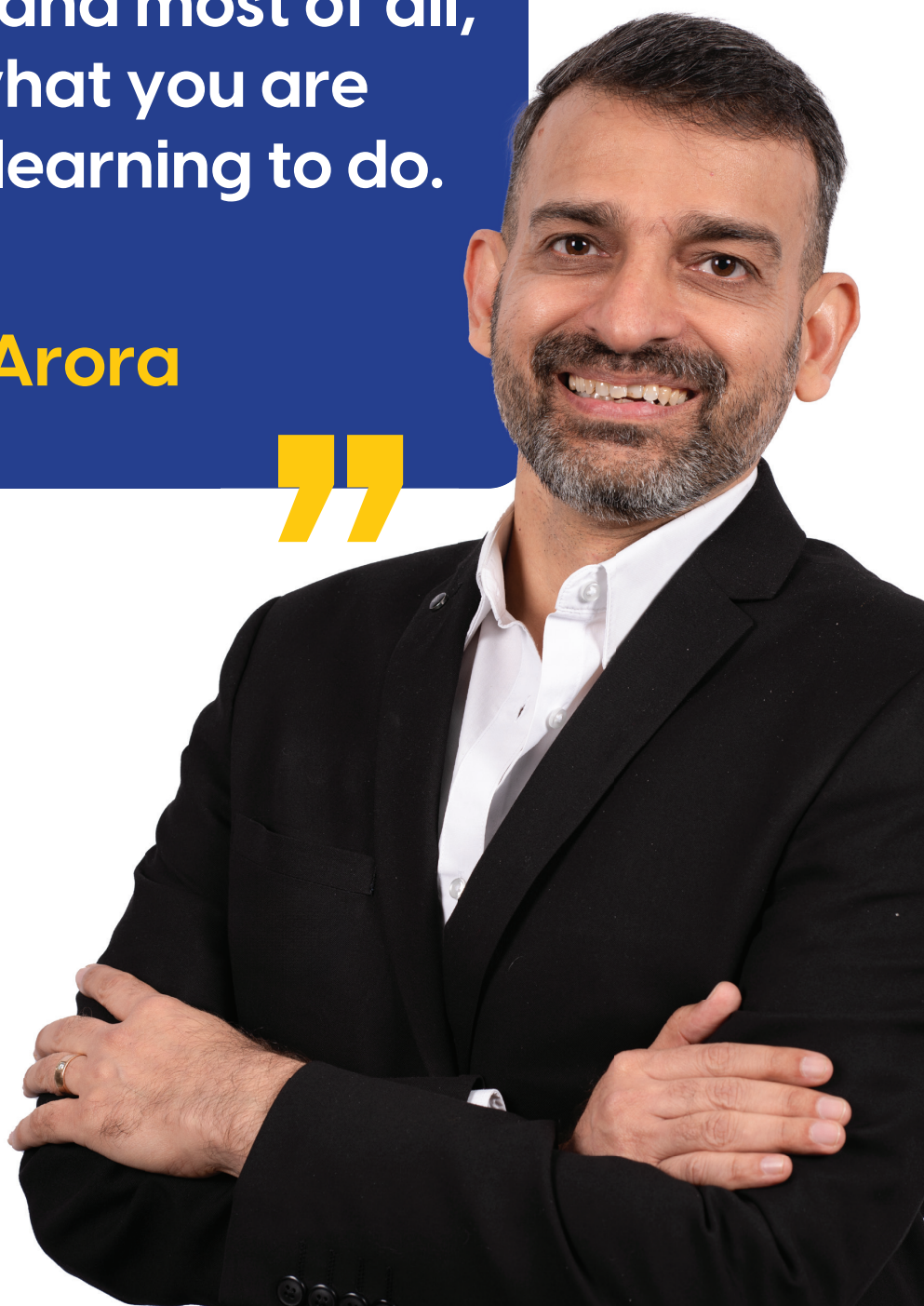<i>Sl. No.</i>	<i>CHAPTER</i>	<i>Page No.</i>
1.	<i>Surgery</i>	179

“

Success is no accident.
It is hard work, learning,
perseverance, studying,
sacrifice and most of all,
love of what you are
doing or learning to do.

- Dr. Jai Arora

”





SURGERY

Score	Result
0	<i>Inconclusive</i>
1	<i>Normal</i>
2	<i>Benign lump</i>
3	<i>Probably benign</i>
4	<i>Suspicious for malignancy</i>
4a	<i>Low suspicion - Risk of malignancy 2-10%</i>
4b	<i>Intermediate suspicion - Risk of malignancy 10-50%</i>
4c	<i>High suspicion - Risk of malignancy 50-95%</i>
5	<i>Highly suspicious - >95%</i>
6	<i>Already proven malignancy</i>

Staging of CA Breast

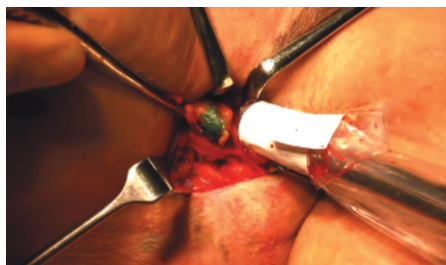- T_{is} → insitu → includes
 - ↳ Ductal carcinoma in-situ
 - ↳ Paget's disease without invasive CA and/or in-situ CA in parenchyma.
- $T_1 < 2\text{ cm}$
 - T_{1mic} → $< 0.1\text{ cm}$
 - T_{1a} → $0.1 - 0.5\text{ cm}$
 - T_{1b} → $0.5 - 1\text{ cm}$
 - T_{1c} → $1-2\text{ cm}$
- T_2 → $2-5\text{ cm}$
- T_3 → $>5\text{ cm}$
- T_4 →
 - T_{4a} — any size with chest wall involvement (DOES NOT include P. major)
 - T_{4b} — any size with skin involvement (includes Peau'd orange, Satellite nodule, ulceration)
 - T_{4c} — $T_{4a} + T_{4b}$
 - T_{4d} — Inflammatory Carcinoma
- N_0 — No node
- N_1 — I/L mobile axillary LN (Level I/ II)
- N_2 — N_{2a} → I/L fixed or matted axillary LN (Level I/II)
- N_{2b} → I/L Internal mammary LN in absence of axillary LN
- N_3 — N_{3a} → I/L Infraclavicular LN (Level III)
- N_{3b} → I/L IMLN with axillary LN
- N_{3c} → I/L Supraclavicular LN
- M_0 — No distant metastasis
- M_1 — Distant metastasis (B/L Supraclavicular LN)



- *Stage I and II Early Breast cancer*
- *Stage IIIa, IIIb, IIIc Locally Advanced Breast cancer*
- *Stage IV Advanced Breast cancer*



Surgery



Absolute C/I for SLNB

1. LABC/Inflammatory CA Breast

Relative C/I

1. Palpable LN → DO FNA or Trucut Bx

2. Previous Axillary surgery } Pre Op/Pre-SLN

3. Radiotherapy in past } ↓
Lymphoscintigraphy can be done

4. Multicentric disease → Not a C/I for SLNB



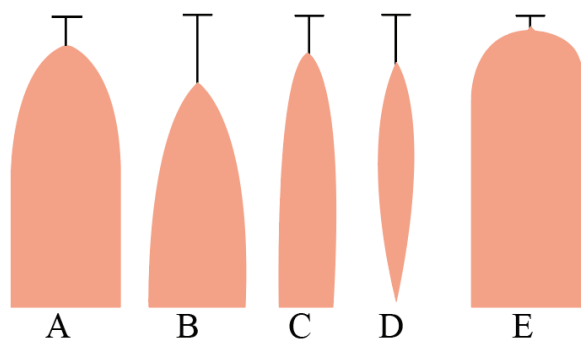
Surgery



Circulation

MC course of shock :- Hemorrhagic

	I	II	III	IV
	Minimal	Mild	Moderate	Severe
Blood Volume lost %	<15%	15-30%	30-40%	>40%
Blood Volume	<750ml	750-1500ml	1500-2l	>2l
HR	<100	100-120	120-140	>140
RR	<20	20-30	30-40%	>40
PP	Normal/↑	↓	↓	↓↓
Hypotension	x	x	✓	✓
Base deficit	0 to -2	-2 to -6	-6 to -10	<10 mEq/L
Blood products	Monitor	Possible	Yes	Massive

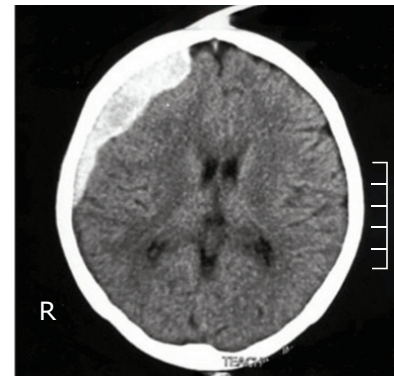
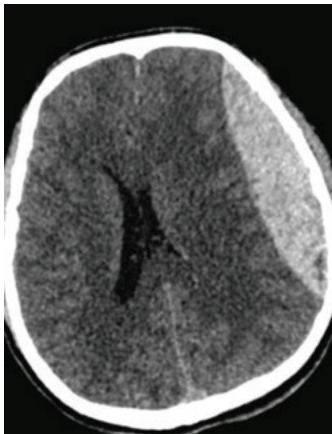



Surgery



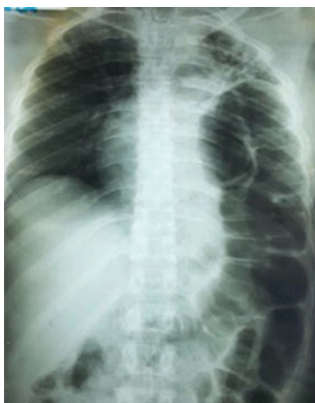Original Scale	Revised Scale	Score
Eye Opening (E) Spontaneous To speech To pain None	Eye Opening (E) Spontaneous To sound To pressure None None-testable	4 3 2 1 NT
Verbal Response (V) Oriented Confused conversation Inappropriate words Incomprehensible sounds None	Verbal Response (V) Oriented Confused conversation Inappropriate words Incomprehensible sounds None None-testable	5 4 3 2 1 NT
Best Motor Response (M) Obey commands Localizes pain Flexion withdrawal to pain Abnormal flexion (decorticate) Extension (decerebrate) None (flaccid)	Best Motor Response (M) Obey commands Localizing Normal flexion Abnormal flexion Extension None None-testable	6 5 4 3 2 1 NT



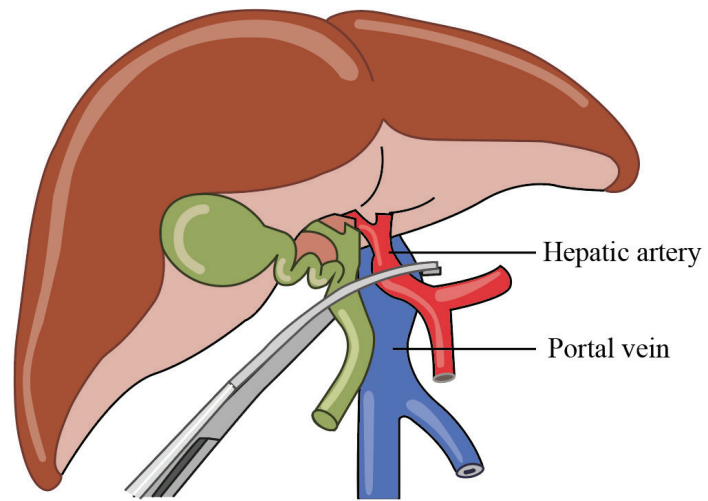
Subdural hematoma (SDH)



Surgery



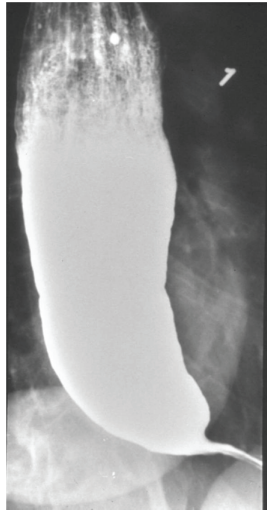
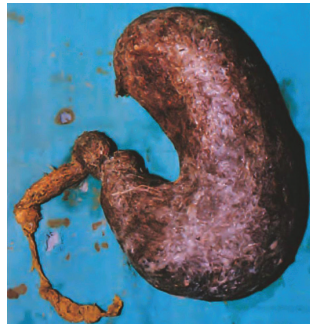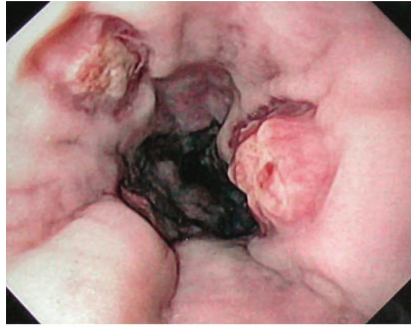
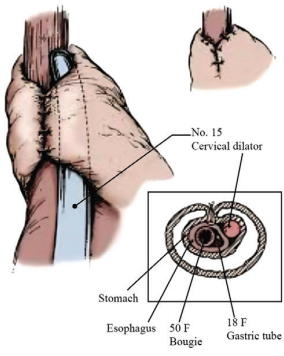
*Chest X-ray Showing
Bowel Loops in Thorax*







Surgery

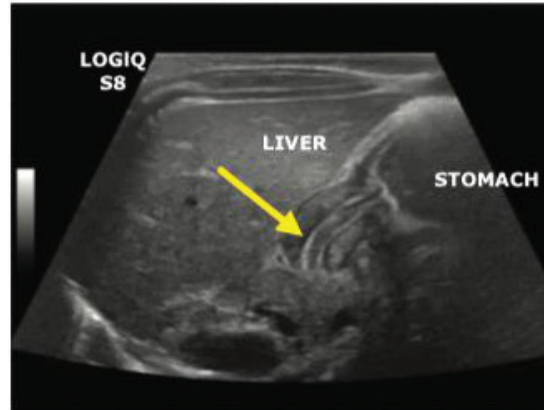
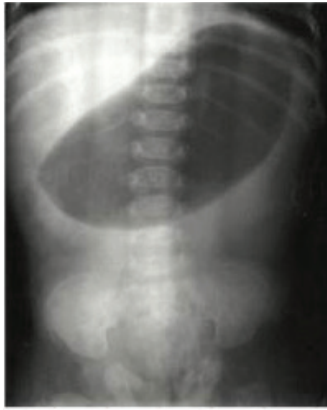
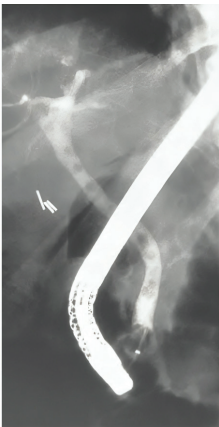
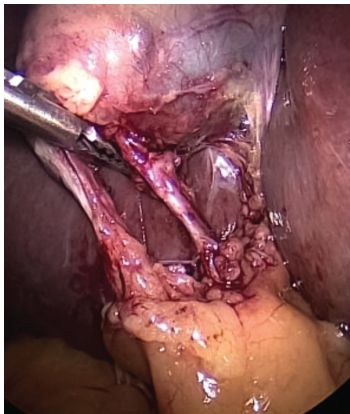
Bird Beak Defect





Surgery





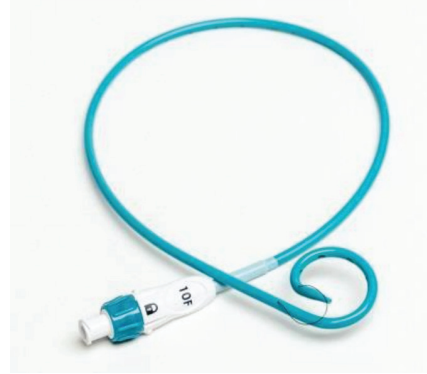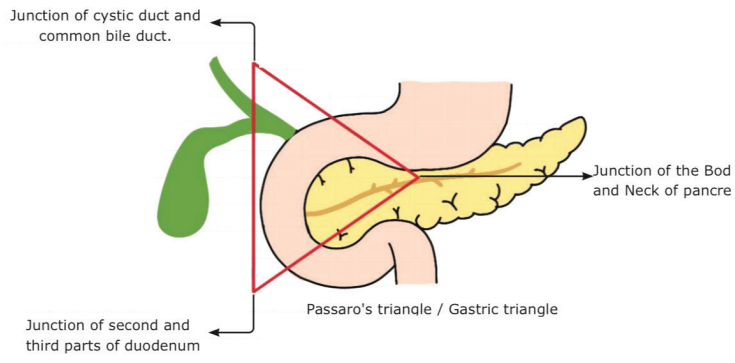


Surgery





Surgery

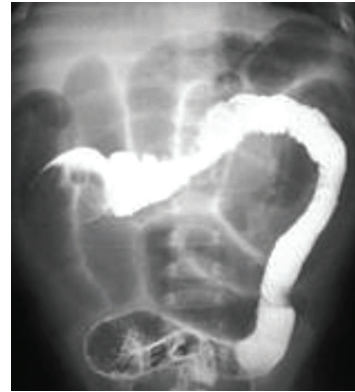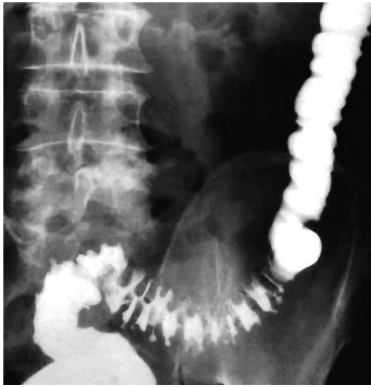


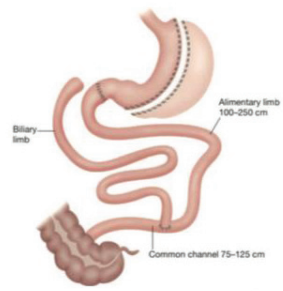


The Alvarado (MANTRELS) Score	
	Score
Symptoms	
<i>Migratory RIF pain</i>	<i>1</i>
<i>Anorexia</i>	<i>1</i>
<i>Nausea and vomiting</i>	<i>1</i>
Signs	
<i>Tenderness (RIF)</i>	<i>2</i>
<i>Rebound tenderness</i>	<i>1</i>
<i>Elevated temperature</i>	<i>1</i>
Laboratory	
<i>Leucocytosis</i>	<i>2</i>
<i>Shift to left</i>	<i>1</i>
<i>Total</i>	<i>10</i>

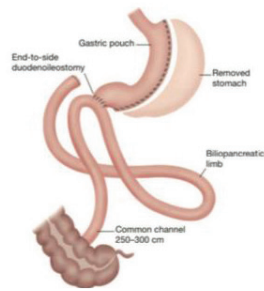


Surgery

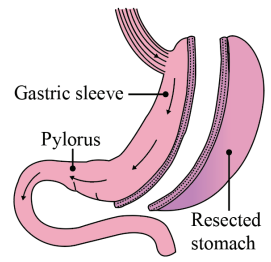
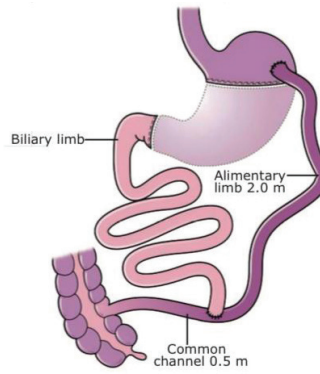




Duodenal Switch Variant

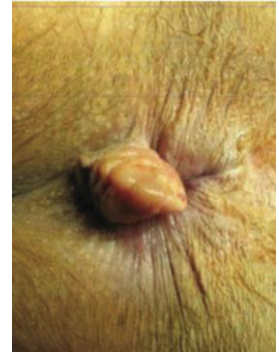
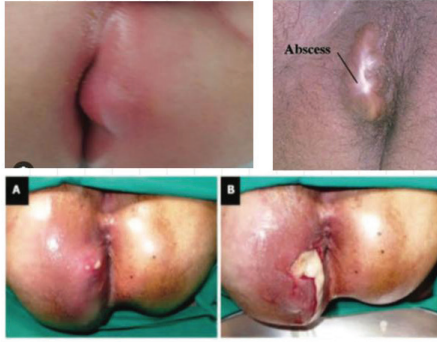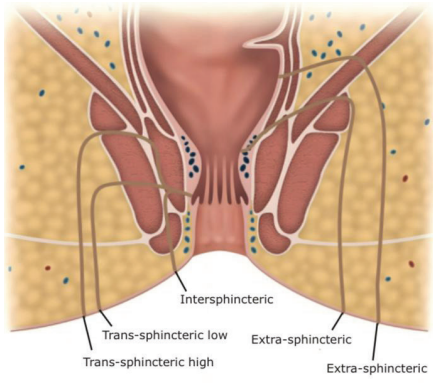


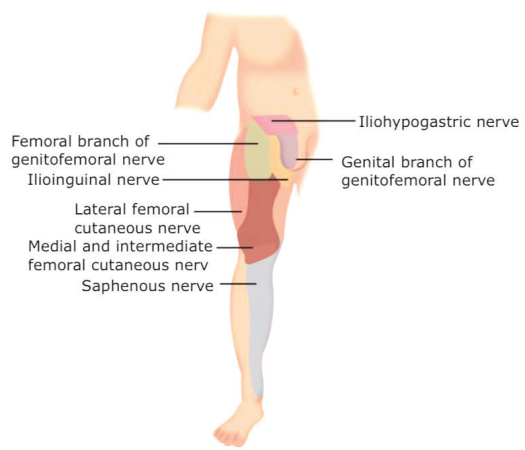
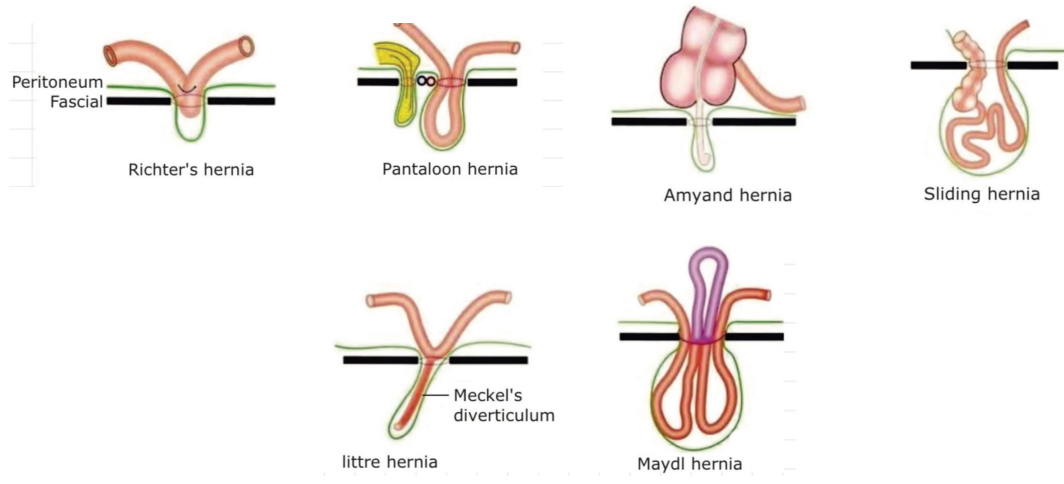
Single-anastomosis duodenoileal bypass with sleeve gastrectomy (SADI-S).





Surgery

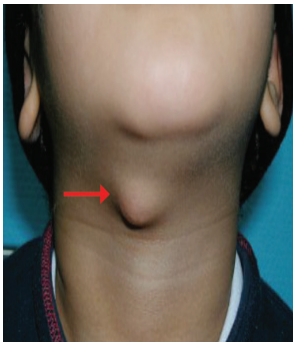
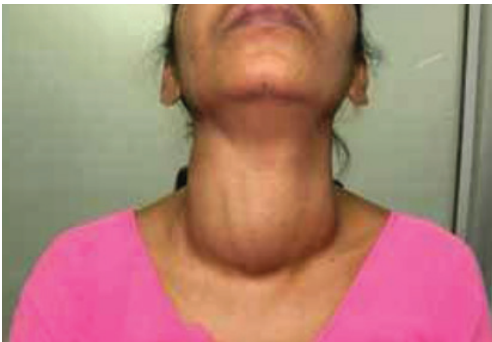
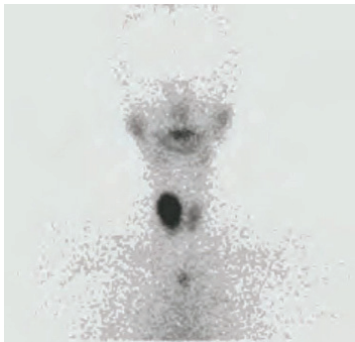




Sensory Dermatomes of the Major Nerves in the Groin Area

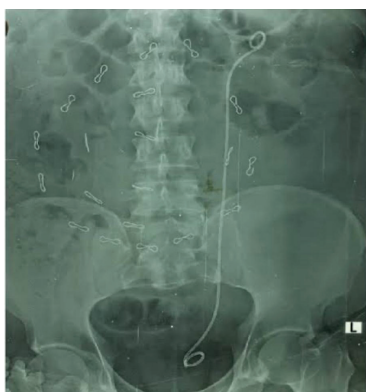

Surgery





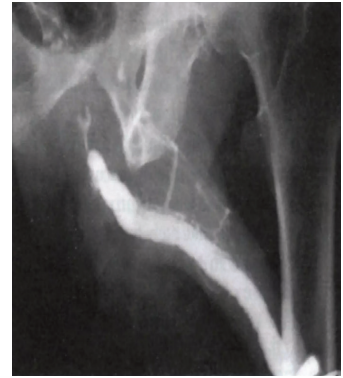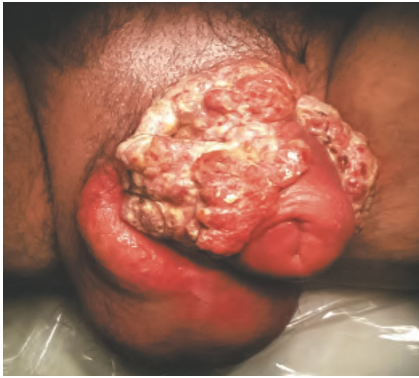Surgery

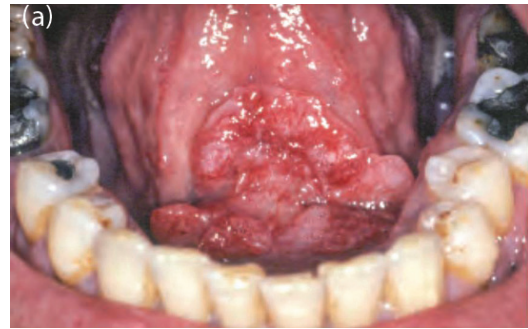
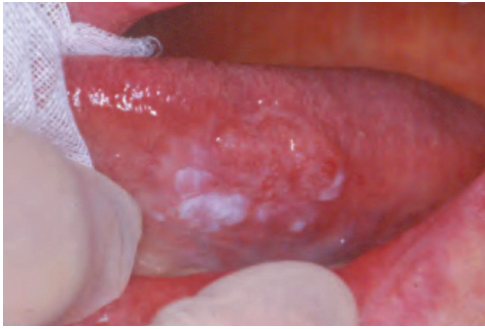
<i>Shape</i>	<i>Type of Stone</i>
<i>Envelope</i>	<i>Ca oxalate</i>
<i>Hourglass</i>	<i>Ca oxalate monohydrate</i>
<i>Hexagonal</i>	<i>Cysteine</i>
<i>Needle</i>	<i>Ca Hydrogen phosphate (Brushite)</i>
<i>Coffinated</i>	<i>Struvite (Ammonium-Magnesium stone)</i>
<i>Amorphous shards/plate</i>	<i>Uric acid</i>



Surgery



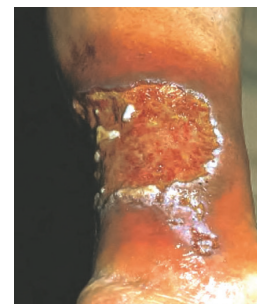
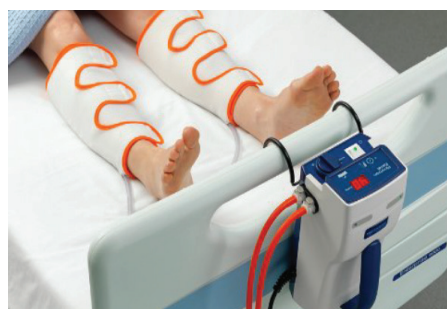
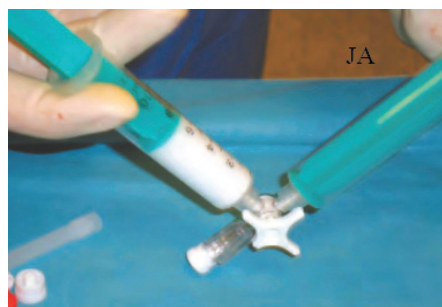Nick Dissection	Structures removed
1. Radial neck dissection	<ul style="list-style-type: none"> • Level I-V LN • Internal Jugular Vein (IJV) • Spinal accessory nerve (SAN) • Sternocleidomastoid muscle (SCM) • Submandibular gland • Tail of parotid gland
2. Modified radical neck dissection	All as in radical neck dissection except:
a. Type I	• Spinal accessory nerve (SAN) preserved
b. Type II	<ul style="list-style-type: none"> • Internal Jugular Vein (IJV) • Spinal accessory nerve (SAN) } Preserved
c. Type III	<ul style="list-style-type: none"> • Internal Jugular Vein (IJV) • Spinal accessory nerve (SAN) • Sternocleidomastoid muscle (SCM) } Preserved
3. Selective node dissection	Level I-III LN removed Level II-IV LN removed Level II-V LN removed Level VI LN removed

T category	T criteria
TX	Primary tumour cannot be assessed
Tis	Carcinoma in situ
T1	Tumour ≤ 2 cm, ≤ 5 mm DOI
T2	Tumour ≤ 2 cm, DOI > 5 mm and ≤ 10 mm or tumour > 2 cm but ≤ 4 cm, and ≤ 10 mm DOI
T3	Tumour > 4 cm or any tumour > 10 mm DOI
T4	Moderately advanced or very advanced local disease
T4a	Moderately advanced local disease: (lip) tumour invades through cortical bone or involves the inferior alveolar nerve, floor of mouth or skin of face (ie. chin or nose); (oral cavity) tumour invades adjacent structures only (e.g. through cortical bone of the mandible or maxilla, or involves the maxillary sinus or skin of the face); note that superficial erosion of bone/tooth socket (alone) by a gingival primary is not sufficient to classify a tumour as T4
T4b	Very advanced local disease; tumour invades masticator space, pterygoid plates or skull base and/or encases the internal carotid artery

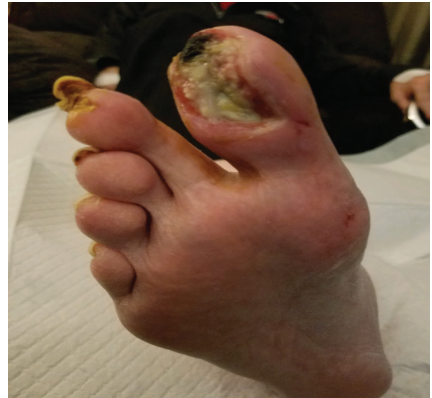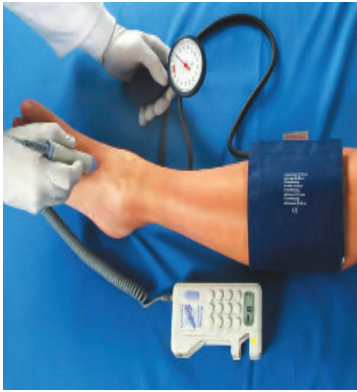Nx	Regional lymph nodes cannot be assessed.
N0	No regional lymph node metastasis
N1	Metastasis in a single ipsilateral lymph node, 3 cm or less in greatest dimension and ENE- negative
N2	Metastasis in a single ipsilateral lymph node, 3 cm or less in greatest dimension and ENE-positive, or more than 3 cm but not more than 6 cm in greatest dimension and ENE- negative, or metastases in multiple ipsilateral lymph nodes, none more than 6 cm in greatest dimension and ENE- negative, or metastases in bilateral or contralateral lymph nodes, none more than 6 cm in greatest dimension and ENE-negative
N2a	Metastasis in a single ipsilateral or contralateral lymph node 3 cm or less in greatest dimension and ENE-positive; or metastasis in a single ipsilateral lymph node more than 3 cm but not more than 6 cm in greatest dimension and ENE-negative / node
N2b	Metastasis in multiple ipsilateral lymph nodes, none more than 6 cm in greatest dimension and ENE-negative
N2c	Metastasis in bilateral or contralateral lymph nodes, none more than 6 cm in greatest dimension and ENE-negative
N3	Metastasis in a lymph node more than 6 cm in greatest dimension and ENE-negative, or metastasis in a single ipsilateral lymph node more than 3 cm in greatest dimension and ENE-positive, or metastasis in multiple ipsilateral, contralateral or bilateral lymph nodes, with any ENE-positive
N3a	Metastasis in a lymph node more than 6 cm in greatest dimension and ENE-negative
N3b	Metastasis in a single ipsilateral lymph node more than 3cm in greatest dimension and ENE-positive, or metastasis in multiple ipsilateral, contralateral or bilateral lymph nodes, with any ENE-positive
ENE, extranodal extension	
Note that a designation of 'U' or 'L' may be used for any N stage to indicate metastasis above the lower border of cricoid (U) or below the lower border of the cricoid (L). Similarly, clinical and pathological ENE should be recorded as ENE - negative or ENE - positive.	

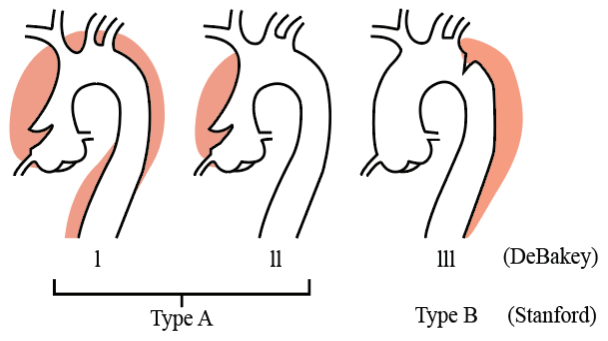
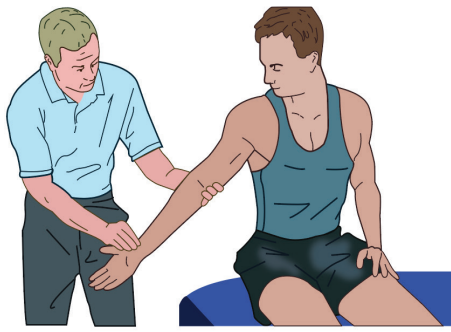
C	Clinical	
	C_0	No visible or palpable sign
	C_1	Telangiectasia (Size < 1mm) (or) Reticular veins (Size 1 - 2.9mm)
	C_2	Varicose veins (Size > 3mm)
	C_3	Edema
	C_{4a}	Pigmentation / Eczema
	C_{4b}	Lipodermatosclerosis / Atrophia blanche
	C_{4c}	Corona phlebectatica
	C_5	Healed venous ulcer
	C_6	Active venous ulcer
	C_{6r}	Recurrent venous ulcer





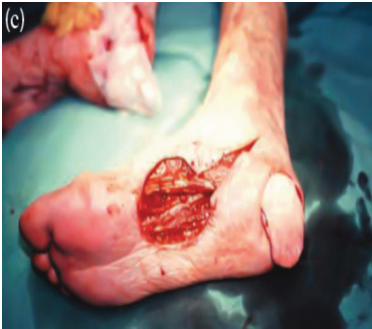
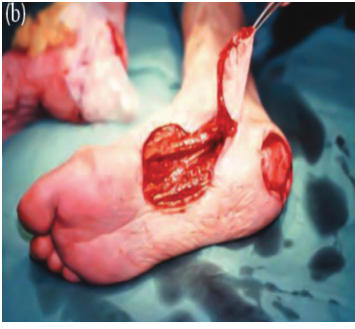
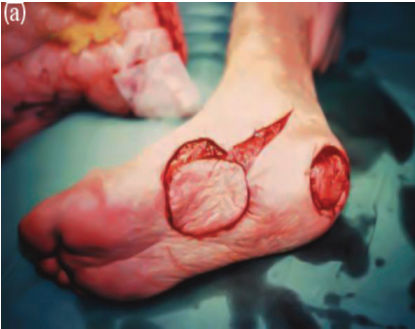Surgery





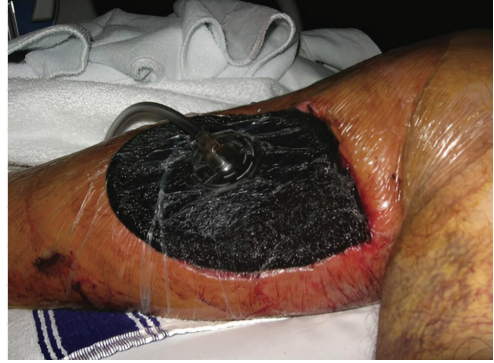
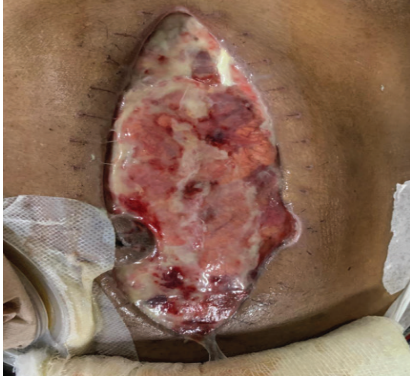
	<i>Split Thickness Skin Graft</i>	<i>Full Thickness Skin Graft</i>
<i>Dermal content</i>	+	+++
<i>Primary contraction</i>	+	+++
<i>Secondary contraction</i>	+++	+
<i>Engraftment</i>	+++	+
<i>Durability</i>	+	+++
<i>Pigmentation</i>	+++	+
<i>Resist desiccation</i>	+	+++
<i>Recipient bed</i>	+	+++
<i>Appearance</i>	+	+++



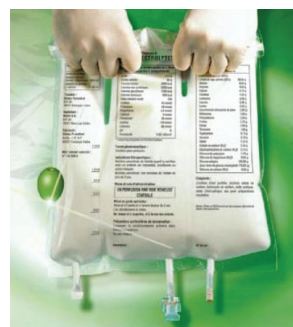

Surgery








	Hypovolaemia	Cardiogenic	Obstructive	Distributive
<i>Cardiac output</i>	<i>Low</i>	<i>Low</i>	<i>Low</i>	<i>High</i>
<i>Vascular resistance</i>	<i>High</i>	<i>High</i>	<i>High</i>	<i>Low</i>
<i>Venous pressure</i>	<i>Low</i>	<i>High</i>	<i>High</i>	<i>Low</i>
<i>Mixed venous saturation</i>	<i>Low</i>	<i>Low</i>	<i>Low</i>	<i>High</i>
<i>Base deficit</i>	<i>High</i>	<i>High</i>	<i>High</i>	<i>High</i>






Surgery

<p>1 (5 Metric) 1/2 Circle round bodied</p>  <p>30mm 45cm</p>	<p>2 (5 Metric) 1/2 C round bodied</p>  <p>35mm 45cm</p>	<p>1/0 (3.5 Metric)</p>  <p>45cm</p>
<p>NYLON MONOFILAMENT Non-Absorbable suture</p> <p>CE 0123</p> <p>STERILE[R] ⚠ Ⓢ</p>	<p>POLYESTER BRAIDED Non-Absorbable suture</p> <p>CE 0123</p> <p>STERILE[R] ⚠ Ⓢ</p>	<p>SILK BRAIDED Non-Absorbable suture</p> <p>CE 0123</p> <p>STERILE[R] ⚠ Ⓢ</p>

2/0
(3 Metric)
1/2 Circle
our vest cutting




26mm
45cm

POLYDIOXANONE
Absorbable suture

CE 1023

STERILE[EO] ⚠ Ⓢ

3/0
(2 Metric)
38 Circle
curved-cutting



25mm
70cm


POLYGLYCOLIC ACID
Absorbable suture

CE 1023

STERILE[EO] ⚠ Ⓢ

LOT 20100908
09.2010
09.2013

4/0
(2 Metric)
28 Circle
curved-cutting



20mm
45cm


PLAIN CATGUT
Absorbable suture

CE 1023

STERILE[R] ⚠ Ⓢ

LOT 20100908
09.2010
09.2013

5/0
(1.5 Metric)
34 Circle
curved-cutting



16mm
75cm


CHROMIC CATGUT
Absorbable suture

CE 1023

STERILE[R] ⚠ Ⓢ

LOT 20100908
09.2010
09.2013

6/0
(0.7 Metric)
30 Circle
curved-cutting



16mm
150cm

POLYPROPYLENE
Non-Absorbable suture

CE 1023

STERILE[R] ⚠ Ⓢ

LOT 20100908
09.2010
09.2013





Current role of drain placement in non-gastrointestinal surgery

Avoid routine drain placement

- *Thyroid surgery*
- *Breast lumpectomy*
- *Inguinal hernia repair*

Consider routine drain placement

- *Radical and modified radical neck dissection*
- *Parotid surgery*
- *Axillary dissection with or without mastectomy*
- *Inguinal lymphadenectomy*
- *Ventral hernia repair in obese patients*

Current role of drain placement in gastrointestinal surgery

Avoid routine drain placement following


- *Colonic surgery*
- *Small bowel resections*
- *Hepatic resections*
- *Cholecystectomy*

Consider routine drain placement following

- *Oesophageal surgery*
- *Major pancreatic resection*

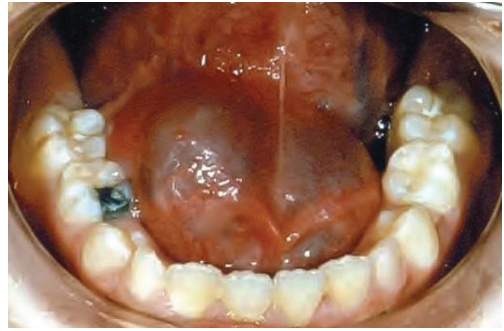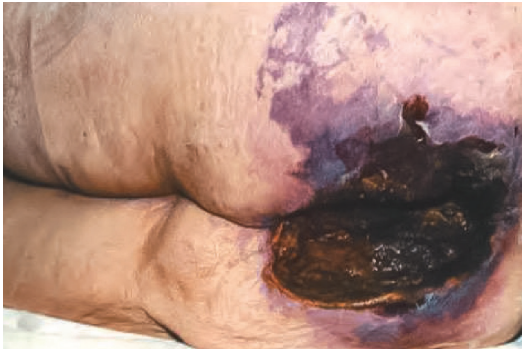Selective use of drains following

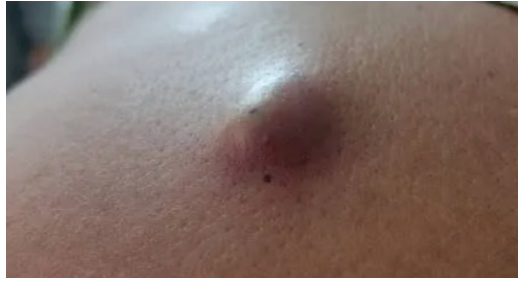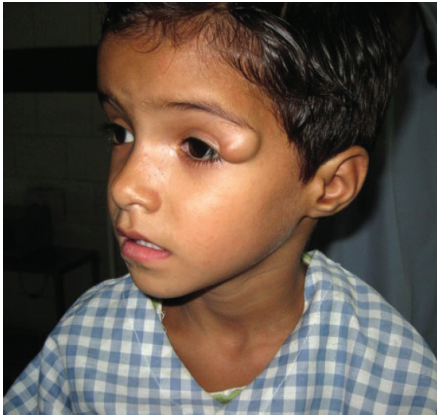- *Rectal surgery*
- *Gastric resections*





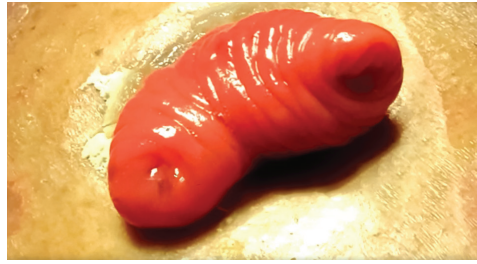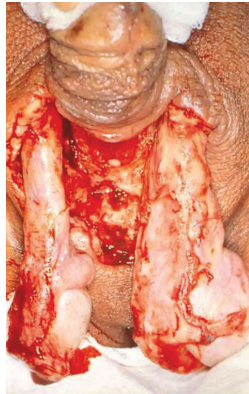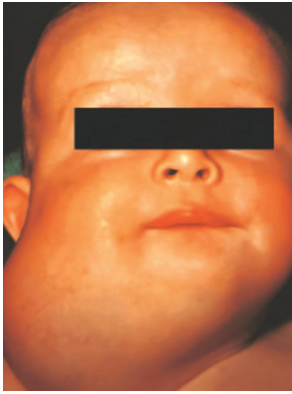Surgery







Surgery





NOTES



Surgery

NOTES